Mycoses

WILEY

mycoses Diagnosis, Therapy and Prophylaxis of Fungal Diseases

GUIDELINES OPEN ACCESS

Management of Invasive Pulmonary Aspergillosis in Intensive Care Units: Guidelines From the Fungal Infection Network of Switzerland (FUNGINOS)

F. Lamoth[1,2] | W. C. Albrich[3] | S. Ragozzino[4] | D. Bosetti[5] | J. Delaloye[6] | C. El Khoury[1] | A. Munting[1] | V. Portillo[6] | I. Reinhold[7,8] | J. Sumer[3] | A. Zbinden[9] | V. Bättig[4] | C. Beigelman-Aubry[10,11] | K. Boggian[3] | A. Conen[12] | T. S. Fischer[13] | C. Garzoni[14] | D. Goldenberger[15] | E. Hofmann[16] | P. Khafagy[17] | L. Kern[18] | G. R. Kleger[19] | C. Le Terrier[20,21,22,23] | O. Marchetti[1,6] | J. L. Pagani[24] | N. J. Rupp[25] | P. W. Schreiber[26] | M. Siegemund[27] | F. Kadgien[28] | D. Neofytos[29] | N. Khanna[4] | on behalf of the Fungal Infection Network of Switzerland (FUNGINOS)

[1]Department of Medicine, Infectious Diseases Service, Lausanne University Hospital and University of Lausanne, Lausanne, Switzerland | [2]Department of Pathology and Laboratory Medicine, Institute of Microbiology, Lausanne University Hospital and University of Lausanne, Lausanne, Switzerland | [3]Division of Infectious Diseases, Infection Prevention and Travel Medicine, HOCH Health Ostschweiz, St Gallen Cantonal Hospital, St Gallen, Switzerland | [4]Division of Infectious Diseases, University Hospital and University of Basel, Basel, Switzerland | [5]Infection Control Program and WHO Collaborating Center, Geneva University Hospitals and Faculty of Medicine, Geneva, Switzerland | [6]Department of Medicine, Ensemble Hospitalier de la Côte, Morges, Switzerland | [7]Institute of Translational Research, Cologne Excellence Cluster on Cellular Stress Responses in Aging-Associated Diseases (CECAD), Faculty of Medicine and University Hospital Cologne, University of Cologne, Cologne, Germany | [8]Department I of Internal Medicine, Excellence Center for Medical Mycology (ECMM), Faculty of Medicine, and University Hospital Cologne, University of Cologne, Cologne, Germany | [9]Unilabs Dübendorf, Dübendorf, Switzerland | [10]Department of Diagnostic and Interventional Radiology, Lausanne University Hospital and University of Lausanne, Lausanne, Switzerland | [11]Department of Radiology, Foch Hospital, Suresnes, France | [12]Clinic for Infectious Diseases and Infection Prevention, Aarau Cantonal Hospital, Aarau, Switzerland | [13]Department of Radiology and Nuclear Medicine, HOCH Health Ostschweiz, St Gallen Cantonal Hospital, St Gallen, Switzerland | [14]Clinica Moncucco, Gruppo Ospedaliero Moncucco, Lugano, Switzerland | [15]Department of Clinical Bacteriology/Mycology, University Hospital Basel and University of Basel, Basel, Switzerland | [16]Department of Infectious Diseases, Inselspital, Bern University Hospital, University of Bern, Bern, Switzerland | [17]Department of Radiology, Fribourg Cantonal Hospital, Fribourg, Switzerland | [18]Division of Pulmonology, Winterthur Cantonal Hospital, Winterthur, Switzerland | [19]Division of Intensive Care Medicine, HOCH Health Ostschweiz, St Gallen Cantonal Hospital, St Gallen, Switzerland | [20]Division of Intensive Care, Department of Acute Care Medicine, Geneva University Hospitals, Geneva, Switzerland | [21]Department of Anaesthesiology, Pharmacology, Intensive Care and Emergency Medicine, Faculty of Medicine, University of Geneva, Geneva, Switzerland | [22]Emerging Antibiotic Resistance Unit, Medical and Molecular Microbiology, Faculty of Science and Medicine, University of Fribourg, Fribourg, Switzerland | [23]Division of Emergency Medicine, Fribourg Cantonal Hospital, Fribourg, Switzerland | [24]Intensive Care Unit, Lausanne University Hospital and University of Lausanne, Lausanne, Switzerland | [25]Department of Pathology and Molecular Pathology, University Hospital Zurich and University of Zurich, Zurich, Switzerland | [26]Department of Infectious Diseases and Hospital Epidemiology, University Hospital Zurich and University of Zurich, Zurich, Switzerland | [27]Division of Intensive Care, University Hospital and University of Basel, Basel, Switzerland | [28]Infectious Diseases Clinic, University Hospital Schleswig-Holstein, Campus Luebeck, Luebeck, Germany | [29]Division of Infectious Diseases, Transplant Infectious Diseases Unit, University Hospitals of Geneva, Geneva, Switzerland

Correspondence: F. Lamoth (frederic.lamoth@chuv.ch) | N. Khanna (nina.khanna@usb.ch)

Received: 12 September 2025 | **Revised:** 27 October 2025 | **Accepted:** 1 November 2025

Funding: FUNGINOS has received financial support for the elaboration of these guidelines from Pfizer, Gilead and Mundipharma. Funding was used for logistical support, including the organisation of the plenary session where the recommendations were presented and voted. Representatives from these pharmaceutical companies did not attend the plenary session and had no role in the process of analyses and assessment of recommendations. They did not review the manuscript before submission and publication.

Keywords: antifungal therapy | aspergillus | cirrhosis | coronavirus | critical care | critically ill | flu | tracheobronchitis

Lamoth F, Albrich WC, Neofytos D, and Khanna N contributed equally to this work.

This is an open access article under the terms of the Creative Commons Attribution-NonCommercial License, which permits use, distribution and reproduction in any medium, provided the original work is properly cited and is not used for commercial purposes.

© 2025 The Author(s). *Mycoses* published by Wiley-VCH GmbH.

ABSTRACT

Invasive pulmonary aspergillosis (IPA) is increasingly recognised in intensive care units (ICU) affecting not only patients with classical immunosuppressive conditions but also other severely ill patients, including those with respiratory viral infections (influenza, COVID-19), advanced chronic obstructive pulmonary disease or acute and chronic liver diseases. Several expert panels have proposed definitions of IPA in different ICU settings. However, practical recommendations for its diagnostic and therapeutic approaches are scarce. Moreover, these approaches can be influenced by different parameters that may vary across countries including the case mix of ICU patients, the incidence of IPA, the prevalence of azole resistance and the availability of diagnostic tests and antifungal drugs. For these reasons, the Fungal Infection Network of Switzerland (FUNGINOS) has appointed a panel of different specialists to develop a practical guideline for the management of IPA in ICU. This article provides the executive summary of the panel conclusions and recommendations regarding the epidemiology, diagnosis, definitions and therapy of IPA in ICU.

1 | Introduction

Invasive pulmonary aspergillosis (IPA), mainly caused by *Aspergillus fumigatus*, has emerged as a serious threat in intensive care units (ICU), affecting not only immunocompromised patients but also patients with severe underlying conditions, such as influenza, coronavirus disease 2019 (COVID-19), chronic obstructive pulmonary disease (COPD) or liver cirrhosis [1, 2]. Some expert panels have proposed definitions for IPA in ICU in general, as well as for influenza-associated and COVID-19-associated pulmonary aspergillosis (IAPA and CAPA, respectively) [3–6]. However, guidelines addressing practical questions for the management of these patients are scarce. The guidelines of the Infectious Diseases Society of America (IDSA) and the joint guidelines of the European Society for Clinical Microbiology and Infectious Diseases (ESCMID), European Confederation of Medical Mycology (ECMM) and European Respiratory Society (ERS) have proposed recommendations for the diagnostic and therapeutic approaches of IPA in general [7, 8]. However, some characteristics that are specific to ICU patients need to be considered.

The Fungal Infection Network of Switzerland (FUNGINOS) is a consortium of physicians and mycologists from different university and university-affiliated hospitals in Switzerland with the objective of promoting medical research, education and collaborations in the field of medical mycology (www.funginos.ch). Considering the lack of consensus regarding the screening strategies and management of these infections, FUNGINOS has identified the need to create a multidisciplinary working group with the objective of assessing standardised diagnostic and therapeutic recommendations for the management of IPA in ICU. The recommendations in this guideline have been adapted to the epidemiological context and the healthcare system (e.g., available diagnostic tools and antifungal drugs) of Switzerland. However, unless otherwise specified, these recommendations may also be adapted for centers in other countries with comparable epidemiology and technical panel.

2 | Methods

A panel of physicians and mycologists from different medical specialties (infectious diseases, intensive care, pulmonology, microbiology, radiology, pathology) and different Swiss tertiary care hospitals was constituted. The members of this panel were selected by the FUNGINOS committee according to their expertise in the topic. The work was distributed in four working groups (WG): epidemiology (WG1), definitions (WG2), diagnosis (WG3), and therapy (WG4).

Practical questions to answer were defined for each WG. During a first step, each WG worked independently on literature review, data analyses and elaboration of proposed recommendations using the grading system from the ESCMID for strength of recommendation (SoR, from A to D) and level of quality of evidence (QoE, from I to III) (Table S1) [8]. Results of analyses and recommendations were presented as a slide set during a plenary session attended by most participants (24/31). These recommendations were discussed and voted on during the session. Contributors who were unable to attend had the opportunity to review the slides and express their opinions. In case of substantial disagreement, the issues were referred to each WG for reassessment and elaboration of a revised proposition, which was again submitted to the appreciation of the whole panel. The final recommendations were consensus-based and needed the approval of at least 75% of the panel. The detailed workflow of the guideline development and the listing of participants of the different WGs are provided in Tables S2 and S3, respectively.

3 | Epidemiology

3.1 | What Is the Incidence of IPA in ICU Patients?

Incidence of IPA in the general ICU population is overall low (< 1%) except in some subgroups of patients, which can be stratified as "low risk" (1%–5%), "intermediate risk" (5%–10%) and "high risk" (> 10%), as detailed in Table 1.

Discussion. Epidemiological data about IPA in ICU patients in general, IAPA and CAPA were reviewed. IPA incidence in critically ill patients without influenza or COVID-19 is generally below 1% (i.e., one per 1000 admissions) [9, 10], although some studies reported higher incidence [11]. Data for specific ICU subpopulations in this group are scarce. IPA rates were 6%–7% in ICU patients with hematologic cancer (all types) in one study [12], which is somewhat higher than that observed in non-ICU patients (4%–5%) [13]. Data specific for high-risk patients, such as those with acute leukaemia or allogeneic haematopoietic cell transplantation (HCT) are lacking but IPA incidence may be expected to be higher in this subgroup. However, the use of mould-active prophylaxis (e.g., posaconazole) was shown to reduce the incidence to about 1% in these

TABLE 1 | Risk stratification for invasive pulmonary aspergillosis in intensive care unit patients.

Low risk (1%–5%)
Solid-organ transplantation other than lung or heart
Hematologic cancer with no or short-duration (< 10 days) neutropenia (e.g., multiple myeloma, lymphoma) or with prolonged (≥ 10 days) neutropenia receiving mould-active prophylaxis
Autologous HCT
Allogeneic HCT without GvHD or receiving mould-active prophylaxis
Respiratory viral infections other than influenza or COVID-19
Extensive burns[a] and/or inhalation injury
Intermediate risk (5%–10%)
Lung or heart transplantation
Severe acute liver dysfunction or chronic end-stage liver disease[b]
Severe chronic obstructive pulmonary disease[c]
Chronic use of systemic corticosteroids or other immunosuppressive therapy
Severe COVID-19[d,e]
Cumulative baseline conditions of low-risk category OR one baseline condition of low-risk category and additional risk factors[f]
High risk (> 10%)
Hematologic cancer and prolonged (≥ 10 days) neutropenia (induction/consolidation for MDS/AL) not receiving mould-active prophylaxis or uncontrolled hematologic cancer
Allogeneic HCT (pre-engraftment phase or GvHD) not receiving mould-active prophylaxis
Severe influenza[d]
Cumulative baseline conditions of intermediate-risk category OR one baseline condition of intermediate-risk category and additional risk factors[f]

Abbreviations: AL, acute leukaemia; COVID-19, Coronavirus disease 2019; GvHD, graft versus host disease; HCT, haematopoietic cell transplantation; MDS: myelodysplastic syndrome.
[a]Burns with > 35% of total body surface area.
[b]Cirrhosis with Child-Pugh score C, acute liver failure, alcoholic hepatitis with Model for End-stage Liver Disease (MELD) score > 24.
[c]Grade 3 or 4 according to the Global Initiative for Chronic Obstructive Lung Disease (GOLD) classification.
[d]The term "severe" refers to patients requiring mechanical ventilation.
[e]The classification of COVID-19 in the intermediate category is based on the IPA incidence observed in Switzerland (5%–10%). It may differ for other countries. Of note, the presence of additional factors, such as short-term corticosteroid use and/or interleukin-6 inhibitor (which is frequent in severe COVID-19) would move these patients into the high-risk category.
[f]Additional risk factors include: high illness severity scores, intensive supportive care (prolonged mechanical ventilation, vasopressors, extracorporeal membrane oxygenation, renal replacement therapy), antibiotic use or immunomodulatory therapies during ICU stay (corticosteroids, interleukin-6 inhibitor).

patients [14, 15]. For solid-organ transplant (SOT) recipients, specific ICU data are lacking. Overall incidence is usually below 5% but may be higher in lung and heart transplant recipients (5%–10%) [16, 17]. For other ICU populations, reported rates of IPA were 1%–15% in patients with liver failure [18–22], 7%–8% in those with COPD [23], 5% in those with respiratory infections other than influenza or COVID-19 [24] and about 2% in those with extensive burns [25–27].

According to one meta-analysis, IAPA incidence in hospitalised patients ranged from 1% to 31%, with a pooled incidence of 11% (95% confidence interval 6%–18%) [28]. Two meta-analyses focusing on critically ill patients reported higher rates (20%–30%) [29, 30]. Variable incidence has been reported between centers and countries, but also from the same centers across seasons [31]. IAPA incidence among patients with immunosuppressive conditions was reported to be as high as 32%–62% [24, 32].

For CAPA, very variable incidences have been reported (from 0% to 47%) with a pooled incidence of 10% [33–35]. These variable rates may be influenced by different CAPA definitions [34, 36]. However, studies based on autopsy results also reported variable incidence (range 2%–26%) [37–39]. A multicenter European study found a lower rate of CAPA (2.5%) compared to IAPA (6%) [40]. Subgroup analyses suggest a particularly high CAPA rate among SOT recipients (21%–64%) [32, 41–43]. CAPA incidence may have increased after the introduction of the COVID-19 vaccine with a possible shift of the disease towards more immunocompromised patients not responding to the vaccination [32].

Overall, data about the incidence of IPA in Swiss ICUs is scarce. One study (two centers) showed an IAPA incidence of 11% [44, 45]. A single-center study conducted during the first COVID-19 wave showed a low CAPA incidence (4%) [46].

3.2 | Which Conditions Have Been Recognised as Risk Factors for IPA in ICU Patients?

In addition to the underlying conditions of the patients listed in Table 1, several factors may additionally increase the risk of IPA, such as a high illness severity score, the need for highly intensive supportive care, and the use of antibiotics or immunomodulatory therapies (corticosteroids or interleukin-6 [IL-6] inhibitors, in particular for COVID-19 patients). The accumulation of baseline underlying conditions and additional risk factors should be considered when assessing the IPA risk of the patient.

Discussion. Studies reporting characteristics of IPA patients were reviewed in the general ICU population, influenza and COVID-19 patients. Among general ICU patients, the most frequent underlying conditions were hematologic cancers [11, 47, 48], COPD [11, 23, 47, 49–52], liver cirrhosis or liver failure [18–22, 53], solid-organ transplantation [11, 47, 54] and extensive burns [25–27]. IPA has also been reported in patients with HIV infection and low CD4 cell count in the absence of classical host factors [55, 56]. However, HIV patients represented a small proportion of IPA in the ICU (0%–7%) [11, 47].

Overall, the requirement for ICU admission and indicators of illness severity, such as high Acute Physiologic Assessment and Chronic Health Evaluation scoring system II (APACHE II), mechanical ventilation, renal replacement therapy (RRT) or use of vasopressors have been associated with increased risk of IPA among diverse non-neutropenic populations (SOT recipients, patients with COPD or severe liver diseases) [18, 19, 50, 57]. Factors associated with *Aspergillus* colonisation and/or IPA in ICU were the use of steroids or other immunosuppressive conditions [23, 58–61], COPD [9, 59], antibiotic use [23, 50], diabetes mellitus [62], and cytomegalovirus (CMV) viremia [63]. Among COPD patients, advanced disease stage, ICU admission, use of steroids, previous antibiotic therapy and chronic heart failure have been associated with IPA [50, 64, 65]. Among patients with liver failure, age, male sex, high model for end-stage liver disease (MELD) score, COPD, encephalopathy, hepato-renal syndrome, antibiotic use and steroid use were identified as independent risk factors of IPA [18, 19, 21, 22, 53]. Among ICU patients colonised with *Aspergillus* spp., those with immunosuppressive conditions, metastatic cancer, steroid therapy during hospitalisation or broad-spectrum antibiotics were more prone to develop IPA [9, 47, 66].

Severe influenza was found to be an independent predictor of IPA in critically ill patients [24, 61, 63]. IAPA mainly occurs in patients on mechanical ventilation and early after ICU admission (within 2–3 days) [24, 29, 67, 68]. About 75% of patients developing IAPA have no immunosuppressive conditions [28, 68]. IAPA has been associated with influenza A H1N1 subtype, male sex, immunosuppressive conditions (hematologic cancer or solid-organ transplantation), liver cirrhosis, chronic lung disease (COPD, asthma, smoking history) and steroid use before or after ICU admission [24, 28–30, 45, 69–73].

IPA has been mainly reported in critically ill COVID-19 patients under mechanical ventilation occurring at variable times after ICU admission [33, 34, 43, 74]. Most CAPA patients were not immunocompromised (93%) but were treated with immunomodulatory therapies, such as steroids and/or IL-6 inhibitors (70%) [34]. Risk factors associated with CAPA were older age, chronic respiratory disease (mainly COPD), previous long-term corticosteroid use, immunosuppression (mainly hematologic cancer and solid-organ transplantation), chronic liver disease, diabetes and cerebrovascular disease [32, 33, 41–43, 62, 74–79]. Treatment of COVID-19 with steroids and IL-6 inhibitors significantly increased the risk of CAPA [33, 42, 43, 78–80].

3.3 | What Is the Impact of IPA on Morbidity and Mortality of ICU Patients?

IPA in ICU is associated with a significant impact on morbidity (need for advanced supportive care, prolonged mechanical ventilation and prolonged ICU stay) with overall high mortality rates.

Discussion. IPA is associated with high in-hospital mortality across all ICU subgroups, with most comparative studies showing significant differences in all categories of patients including general ICU [10, 19, 21, 23, 50, 59, 66], influenza [24, 28–30, 45, 69, 70] and COVID-19 patients [32, 33, 42, 43, 74, 76, 77, 79, 81, 82]. Indexes of critical illness, including high severity scores, RRT, vasopressors, extracorporeal membrane oxygenation (ECMO), duration of mechanical ventilation and duration of hospital or ICU stay were also significantly higher among IPA patients compared to the control groups in most studies [9, 10, 19, 24, 28, 29, 32, 33, 40, 42–45, 66, 69–71, 74, 76, 78, 82]. However, it is difficult to determine whether these severity indexes were the consequences of IPA or rather represented risk factors for its development. The impact of antifungal therapy (AFT) or the timing of its initiation on outcomes has not been clearly demonstrated [24, 74].

Overall mortality rates for IPA in general ICU patients ranged from about 55% to > 90% [9–11, 47, 59, 66]. Analyses for specific ICU subgroups suggest mortality rates of about 70% for SOT recipients [54], 60% for COPD patients [23] and 55%–100% for patients with severe liver diseases [18–22, 53]. In meta-analyses, mortality rates of IAPA and CAPA were 30%–50% and 40%–60%, respectively [28–30, 33, 34, 76].

4 | Diagnosis

4.1 | Which Tests Are Available to Diagnose IPA in the ICU?

Samples for IPA detection include serum (or plasma), non-bronchoscopic respiratory (NBR) samples (bronchial aspirates, non-bronchoscopic lavage) and bronchoalveolar lavage fluid (BALF) obtained by bronchoscopy. Diagnostic tools for IPA include direct microscopy, fungal culture, *Aspergillus*-specific PCR, galactomannan (GM) and 1,3-β-d-glucan (BDG) detection.

Discussion. More details about these tests (available kits, cut-off values) and their use in different clinical samples are provided in

Table S4. For GM testing, the panel supports the use of both the enzyme immunoassay (EIA, Platelia *Aspergillus*, Bio-Rad) and the lateral flow assay (Soña *Aspergillus* GM LFA, IMMY). Both tests have been compared in the ICU setting with acceptable agreement and similar performances in BALF [83–85]. Their performance in serum was similar in hematologic patients, but comparative data specific to the ICU setting are lacking [86]. The choice of the test may be influenced by the laboratory workflow and the turnaround time, which may be shorter with the LFA compared to the EIA. Detection of *Aspergillus* by PCR can be performed by in-house assays or commercial kits (listed in Table S4). Data are lacking to favor one approach over the other.

The following paragraphs address diagnostic approaches of IPA, which are summarised in the algorithm of Figure 1.

4.2 | Which ICU Patients Should Be Screened for IPA and Which Tests Should Be Used for Screening?

ICU patients with hematologic conditions classified within the high-risk category (Table 1) should undergo serial GM screening in serum (A I). For other high-risk categories, the panel proposes a marginal recommendation for the IPA screening strategy in ICU based on the absence of studies assessing the benefit of such a pre-emptive approach and the overall limited sensitivity and specificity of the tests (C II). If such a strategy is applied, GM in serum can be used in patients with severe influenza (but not COVID-19 due to low sensitivity). Screening can also be performed in NBR samples using (in order of preference and according to availability) GM, fungal culture or PCR. These recommendations are summarised in Table 2. A negative test does not rule out IPA and a positive test should always trigger further diagnostic work-up (i.e., bronchoscopy) for better diagnostic accuracy. There is no clear evidence regarding the frequency of screening, but the panel recommends testing every 3 to 4 days (e.g., twice weekly).

Discussion. Screening for IPA can be performed on serum samples with the GM test (*Aspergillus* specific), the BDG test (not specific) or PCR (*A. fumigatus* or *Aspergillus* spp. specific). Data about the performance of these tests in screening strategies are mostly derived from the onco-hematologic setting [87–89]. The sensitivity of serum GM for IAPA is about 50%–60% [24, 68] but does not exceed 10%–20% for CAPA [74, 77, 90, 91]. In one study using autopsy-proven IPA as the reference standard, the specificity of serum GM for IAPA and CAPA was 94%. The role of serial serum GM screening for IAPA has been investigated in few studies and raised some concerns about specificity [92, 93]. A variable sensitivity (30%–80%) and specificity (50%–85%) have been reported in other ICU patients with mixed risk factors of IPA [11, 21, 94–98]. Data about the use of PCR screening in serum for IPA in ICU are very scarce [99]. The BDG test has variable sensitivity (40%–90%) and overall poor specificity (40%–80%) for the diagnosis of IPA in ICU [77, 94, 98, 100, 101].

Screening can also be performed in NBR samples by GM, PCR or fungal cultures. Some studies have reported variable sensitivity (about 60%–85%) and specificity (80%–95%) using different cut-offs for GM detection in NBR samples (endotracheal aspirates, non-directed BALF) in CAPA patients [79, 102–105]. Fungal cultures from NBR samples have low sensitivity (30%–40%) [68, 79]. Data for PCR in these samples is limited [79].

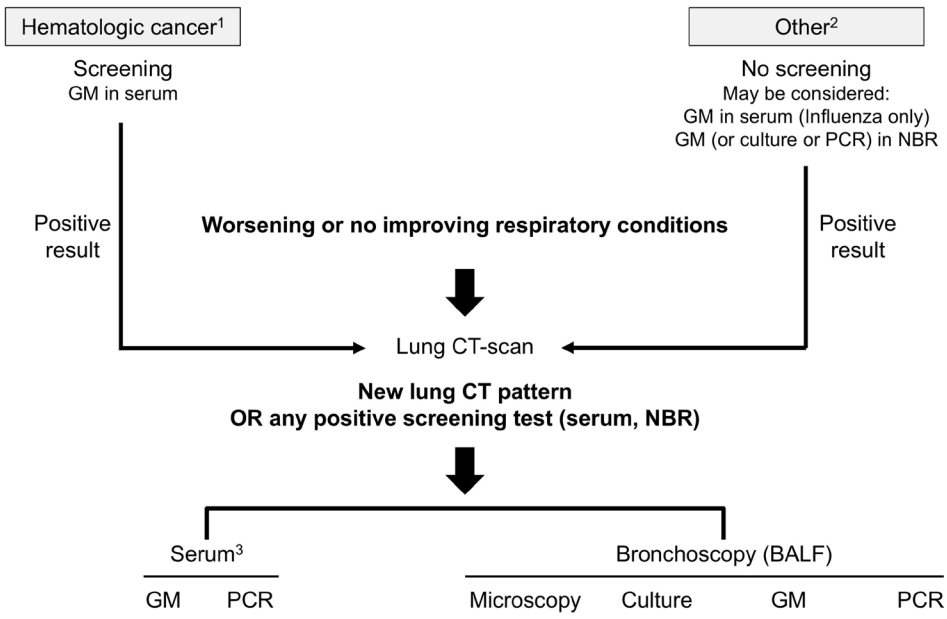

FIGURE 1 | Algorithm for diagnostic approach of invasive pulmonary aspergillosis in intensive care unit patients. BALF, bronchoalveolar lavage fluid; CT, computed tomography, GM, galactomannan; NBR, non-bronchoscopic respiratory samples; PCR, polymerase chain reaction. [1]Patients with hematologic cancer classified in the high risk category (see Table 1). [2]Other patients classified in the high, intermediate or low risk categories (see Table 1). [3]If not already tested positive in screening.

TABLE 2 | Role of diagnostic procedures for invasive pulmonary aspergillosis in intensive care unit patients.

Diagnostic procedure	Targeted population	SoR, QoE
GM[a] in serum (screening)	Hematologic cancer within high-risk category[b] Severe influenza	A, I C, II
GM[a] in NBR (screening)[c]	Conditions classified in high-risk category other than hematologic cancer[d]	C, II
Chest CT	Any baseline condition (low/intermediate/high risk)[d] AND Worsening respiratory conditions without clear explanation	A, III
Bronchoscopy with: direct microscopy, fungal culture, GM and PCR in BALF[e]	Any baseline condition (low/intermediate/high risk)[d] AND New radiological pulmonary infiltrate without alternative infectious or non-infectious diagnosis OR Any positive *Aspergillus* test (culture, GM, PCR) in a non-invasive sample (serum, NBR)	A, II

Abbreviations: BALF, bronchoalveolar lavage fluid.CT, computed tomography; GM, galactomannan; NBR, non-bronchoscopic respiratory sample (sputum, tracheal aspirate; non-bronchoscopic bronchoalveolar lavage); PCR, *Aspergillus*-specific polymerase chain reaction; QoE, quality of evidence; SoR, strength of recommendation.
[a]Both GM-enzyme immunoassay (EIA) and GM-lateral flow assay (LFA) can be used. See details and proposed cut-offs in Table S4.
[b]According to Table 1: hematologic cancer and prolonged (≥10 days) neutropenia (induction/consolidation for myelodysplastic syndrome/acute myeloid leukaemia, acute lymphocytic leukaemia) not receiving mould-active prophylaxis or uncontrolled hematologic cancer or allogeneic haematopoietic cell transplantation (pre-engraftment phase or graft versus host disease) not receiving mould-active prophylaxis.
[c]Alternatively, fungal culture or *Aspergillus* PCR can be performed.
[d]According to Table 1.
[e]If not yet documented, the diagnostic work-up should be completed by GM and/or PCR in serum or plasma (see Figure 1).

4.3 | What Is the Utility of CT-Scan for the Diagnosis of IPA?

Lung CT-scan should be performed in any patient with worsening respiratory conditions (A III, Table 2). Although there are no specific imaging patterns of IPA in ICU patients, CT may detect some suggestive patterns like cavitary lesions and is useful for baseline assessment and follow-up.

Discussion. Chest CT-scan is the most useful imaging procedure, which can usually be obtained in a reasonable time frame (within 24 h) and can detect IPA lesions that are often missed by standard chest radiograph [106]. Radiological patterns of IPA in ICU have been mainly described in CAPA [4, 11, 97, 107–111]. Classical findings of IPA, such as the nodules and halo sign, were present in ≤25% and ≤12% of cases, respectively [4, 11, 97, 108–111]. Cavitary lesions were observed in about 10%–30% in most studies and up to 73% in one study [4, 11, 108–111]. Signs suggestive of IPA, such as nodules and cavitary lesions, were more frequently observed in IAPA than in CAPA, which may reflect the higher level of baseline immunosuppression and higher risk of angio-invasive in IAPA [111]. Overall, the most frequent pattern (present in > 70% of cases) was non-specific consolidation or ground-glass opacities [4, 108–111]. Bronchiectasis (de novo or increased) has been reported in about 40%–80% of CAPA [107–109]. This pattern should be distinguished from common reversible dilated airways of COVID-19 organising pneumonia or traction bronchiectasis of COVID-19 associated fibrosis. Bronchial wall thickening, albeit not specific, has been reported in up to 60% of CAPA in one study [109]. In two studies comparing radiological patterns between CAPA and non-CAPA COVID-19 patients, cavitary lesions, bronchiectasis and bronchial wall thickening have been significantly associated with CAPA [108, 109].

4.4 | Which Patients Should Undergo Bronchoscopy for IPA Diagnostic Work-Up?

All ICU patients (at low, intermediate or high risk for IPA) with a new radiological abnormality in the absence of alternative explanation should undergo bronchoscopy (A II). Bronchoscopy is also indicated in case of a positive test for *Aspergillus* detection in serum (GM) or NBR samples (culture, GM, PCR) (A II). These recommendations are summarized in Table 2.

Discussion. Clinical signs of IPA are insidious and non-specific. Worsening respiratory conditions despite ongoing antibiotic therapy should raise the suspicion of IPA in patients at risk [3–6]. As discussed above, IPA, may be associated with multiple non-specific radiological patterns [109–111]. Any positive microbiological test for *Aspergillus* in a screening sample (e.g., serum or NBR) is suggestive of IPA. Because of the lack of specificity of serum GM (with possible false positive results) [92–95], and GM, PCR and cultures in NBR samples (poor ability to distinguish IPA from colonisation) [79, 102–105], a bronchoscopy is indicated whenever possible for more accurate diagnosis and guiding therapeutic decisions [112].

4.5 | Which Tests Should Be Performed in BALF?

BALF samples should be tested using direct microscopy (A II), fungal culture (A II), GM testing (A II) and *Aspergillus* PCR (A II). While these tests exhibit variable sensitivity and specificity, their conjunction may improve diagnostic accuracy. These recommendations are summarized in Table 2.

Discussion. BALF samples can be tested for *Aspergillus* detection by direct microscopy, fungal culture, PCR or GM. Direct microscopy is associated with low sensitivity in CAPA [90, 113].

For IAPA, sensitivity is much higher in patients with *Aspergillus* tracheobronchitis compared to those with IPA (75% vs. 20%) [114]. The actual sensitivity of culture and GM in BALF is difficult to assess as most studies used these tests' results for IPA definitions [5, 6]. However, a study confronting ante-mortem diagnosis of probable IAPA or CAPA to autopsy results showed sensitivity/specificity of 92%/64% and 58%/93% for GM and culture in BALF, respectively [39]. It is important to note that the actual positive and negative predictive values of these tests depend on the IAPA/CAPA prevalence, which may vary between centers and across seasons [28, 31, 36]. Regarding PCR in BALF, data using the reference standard of autopsy-proven IPA are lacking. The few studies assessing its performance for IPA diagnosis according to consensual definitions suggest variable sensitivity according to the underlying condition (40%–50% in CAPA, 60%–70% in other ICU IPA) and good specificity (> 95%) [77, 115, 116].

5 | Definitions

5.1 | How Should Possible, Probable and Proven IPA in ICU Be Defined?

For immunocompromised hosts, we recommend using EORTC-MSGERC criteria, similarly to non-ICU populations. For patients who do not fulfill EORTC-MSGERC host criteria, adapted definitions of IPA in ICU are proposed in Table 3.

Discussion. IPA definitions have been established by the European Organisation for Research and Treatment of Cancer (EORTC) and Mycoses Study Group Education and Research Consortium (MSGERC) and rely on the presence of host factors of immunosuppression [117]. These definitions are not generally applicable in ICU where patients without these host criteria may also be at risk of IPA. Several definitions adapted to the ICU setting have been proposed [3–6, 24]. Because of the lack of specificity of clinical and radiological signs of IPA, these definitions rely essentially on the documentation of a positive microbiological test for *Aspergillus*. However, the distinction between *Aspergillus* airway colonisation and IPA remains challenging. Considering that the physiopathology of IPA may differ between ICU patients with EORTC-MSGERC host criteria and those exhibiting other risk factors (as mentioned in Table 1), we propose to treat these categories separately. We considered that ICU patients fulfilling EORTC-MSGERC host criteria enter into the EORTC-MSGERC classification of IPA [117]. We established a distinct classification for ICU patients with conditions at low, intermediate or high risk of IPA (other than EORTC-MSGERC host factors, Table 1). Among these patients (host criteria), IPA should be suspected in those presenting deteriorating respiratory conditions and any new or progressive pulmonary infiltrate without alternative explanation or direct observation of signs suggestive of *Aspergillus* tracheobronchitis (tracheobronchial ulcerations, pseudomembranes, nodules, plaques, eschars) at bronchoscopy (i.e., clinical/radiological criteria). Documentation of

TABLE 3 | Definitions of invasive pulmonary aspergillosis in non-immunocompromised intensive care unit patients (i.e., not fulfilling EORTC-MSGERC host criteria)[a].

IPA classification	Host criteria	Clinical/radiological criteria	Histopathological/microbiological criteria
Proven			Direct observation of hyphae consistent with *Aspergillus* spp. and signs of tissue invasion Positive culture or *Aspergillus* PCR from normally sterile tissue
Probable	Severe influenza[b] Severe COVID-19[b] Exacerbated severe COPD (GOLD grade 3 or 4) Severe acute liver dysfunction or chronic end-stage liver disease Respiratory viral infection other than influenza or COVID-19 Burns with TBSA > 35% and/or inhalation injury	Deterioration of respiratory conditions AND New radiological pulmonary infiltrate without alternative infectious or non-infectious diagnosis Tracheobronchial ulcerations, pseudomembranes, nodules, plaques or eschars at bronchoscopic examination	GM[c] ≥ 0.5 in serum OR GM[c] ≥ 1 in BALF OR *Aspergillus* spp. recovered by culture in BALF OR Positive *Aspergillus* PCR in serum (twice) OR Positive *Aspergillus* PCR in serum and BALF
Possible			*Aspergillus* spp. recovered by culture in NBR OR GM[c] ≥ 4.5 in NBR OR GM[c] ≥ 1.2 in NBR (twice) OR GM[c] ≥ 1.2 and positive *Aspergillus* PCR in NBR

Abbreviations: BALF, bronchoalveolar lavage fluid; COPD, chronic obstructive pulmonary disease; COVID-19, coronavirus 2019; EORTC-MSGERC, European Organisation for Research and Treatment of Cancer—Mycoses Study Group Education and Research Consortium; GM, galactomannan; GOLD, Global Initiative for Chronic Obstructive Lung Disease; IPA, invasive pulmonary aspergillosis; NBR, non-bronchoscopic respiratory samples; PCR, polymerase chain reaction; TBSA, total body surface area.

[a]For immunocompromised patients according to EORTC-MSGERC host criteria, definitions of the EORTC-MSGERC apply [117].

[b]The term "severe" refers to patients requiring mechanical ventilation.

[c]Both GM-enzyme immunoassay (EIA) and GM-lateral flow assay (LFA) can be used. See details in Table S4.

a positive test for *Aspergillus* (i.e., histopathological/microbiological criteria) is then required for classification in the proven, probable and possible IPA categories. We considered sample origin to make this distinction. Samples from normally sterile sites (i.e., lung biopsy) with recovery of *Aspergillus* spp. (direct microscopy, culture or PCR) are required for proven IPA. Positive results from serum or plasma (GM, PCR) and BALF (culture, GM, PCR) were considered as indicative of probable IPA. Indeed, based on one study assessing the performance of these tests/samples according to autopsy results for CAPA and IAPA, serum GM, BALF GM and BALF culture had a specificity of 94% (cut-off ≥ 0.5 ODI), 64% (cut-off ≥ 1 ODI) and 93%, respectively [39]. Moreover, GM in BALF exhibited the highest sensitivity (92%). For PCR, because of the lack of reliable specificity data, we propose that two positive tests (twice in serum or one in serum and one in BALF) are required for a diagnosis of probable IPA, which is in line with previous guidelines [5, 117]. Finally, positive results from NBR samples (culture, GM, PCR) were classified in the category of possible IPA. Indeed, the specificity of these samples to distinguish IPA from colonisation is uncertain. Cut-offs have been proposed for GM interpretation in NBR samples in CAPA [5], but their actual performance to predict IPA is unclear with limited experience [79, 102–105].

We have provided a schematic representation comparing the rationale and approach for definitions of IPA in ICU for patients with EORTC-MSGERC criteria and other patients at risk in Figure S1.

6 | Treatment

6.1 | Which ICU Patients Should Be Treated for IPA?

Patients fulfilling the criteria of probable or proven IPA or *Aspergillus* tracheobronchitis (according to Table 3) should be treated with AFT as soon as possible (A II). Patients with criteria of possible IPA or clinical suspicion of IPA should undergo further diagnostic work-up (e.g., bronchoscopy) as soon as possible, as recommended above. AFT should be considered in these patients according to clinical conditions if bronchoscopy is not feasible or delayed or in case of persisting (i.e., ≥ 2 consecutive) positive results in NBR samples. In these latter scenarios, AFT should be reassessed later according to the results of microbiological tests in BALF when bronchoscopy has been performed (A III).

Discussion. There was no study demonstrating the association between AFT and improved outcomes [24, 28, 29, 33, 74, 76, 78]. Indeed, the benefit of AFT is difficult to demonstrate as most patients with putative IPA receive AFT. Considering the high mortality rates of IPA in ICU (see above), we strongly recommend promptly starting AFT in patients with proven or probable IPA according to the definitions in Table 3. In case of positive GM or PCR in serum, we recommend obtaining a second positive test on a consecutive sample. Pending this result, AFT can be started or refrained according to the clinical situations (risk level, clinical illness severity). For patients fulfilling the criteria of possible IPA according to the definitions in Table 3, diagnostic work-up should be completed by bronchoscopy with BALF. If bronchoscopy cannot be performed within a reasonable time frame (< 24 h) or in case of clinical deterioration or high-risk condition, AFT can be started and reassessed later. If bronchoscopy is not feasible, we recommend repeating *Aspergillus* testing (culture, GM or PCR) in NBR samples and to consider AFT in case of persistent positive results and clinical deterioration. If bronchoscopy is obtained and BALF results do not allow an upgrade from possible to probable IPA in a patient with stable or improving clinical conditions, AFT can be refrained. A screening in serum or NBR samples can be performed in this scenario (see recommendations above for screening strategy) and AFT should be considered in case of lack of improvement and repeated positive *Aspergillus* testing in NBR samples or in case of clinical deterioration without alternative explanation. These recommendations are summarised in the algorithm presented in Figure 2.

6.2 | Which Antifungal Drug Is Recommended as First-Line Therapy of IPA?

We recommend isavuconazole or voriconazole as first-line therapy for IPA in ICU patients (A I and A II for patients with and without immunocompromised conditions, respectively). Isavuconazole might be preferred in selected critically ill patients because of its better pharmacokinetic and safety profiles. Liposomal amphotericin B (L-amphotericin B) and posaconazole are acceptable alternatives (B II, B I/II, respectively). Echinocandins can be considered in combination therapy for selected cases (C I/III) but should be avoided as monotherapy unless there is no alternative option. These recommendations are summarised in Table 4.

Discussion. Few studies have compared the mortality rates between different antifungals for the treatment of IPA in ICU and their results (based on small datasets) could not demonstrate any significant differences [118, 119, 166, 167]. Voriconazole and isavuconazole have been approved as first-line AFT for IPA based on randomized trials in hematologic cancer populations [7, 8, 120, 122, 168]. Such studies are lacking for ICU patients. In observational cohort studies of IPA in ICU, voriconazole was the most frequent AFT [24, 35, 50, 74, 91, 118, 119, 121]. The use of isavuconazole was mainly reported for the treatment of CAPA, representing about 15%–40% of AFTs in published literature [35, 91, 123]. Compared to voriconazole, isavuconazole displays several advantages in terms of pharmacokinetic and safety profiles, such as less variable interindividual drug exposure, fewer drug–drug interactions (DDI), the lack of the cyclodextrin adjuvant component in the intravenous formulation (that may accumulate in cases of renal failure), less neurological and hepatic toxicity and less concern about the risk of cardiac arrhythmia (no prolongation of QT interval) [122, 123]. Because these conditions are frequent in critically ill patients, the panel suggested a strong recommendation (A, similar to voriconazole) for the use of isavuconazole, suggesting that it could be favored for patients with liver dysfunction, severe renal insufficiency or potential DDI. Posaconazole has demonstrated that it is non-inferior to voriconazole for the treatment of IPA in immunocompromised patients in a randomized controlled trial [125]. However, experience with posaconazole for IPA treatment in ICU is limited [35, 91], and this drug does not offer real

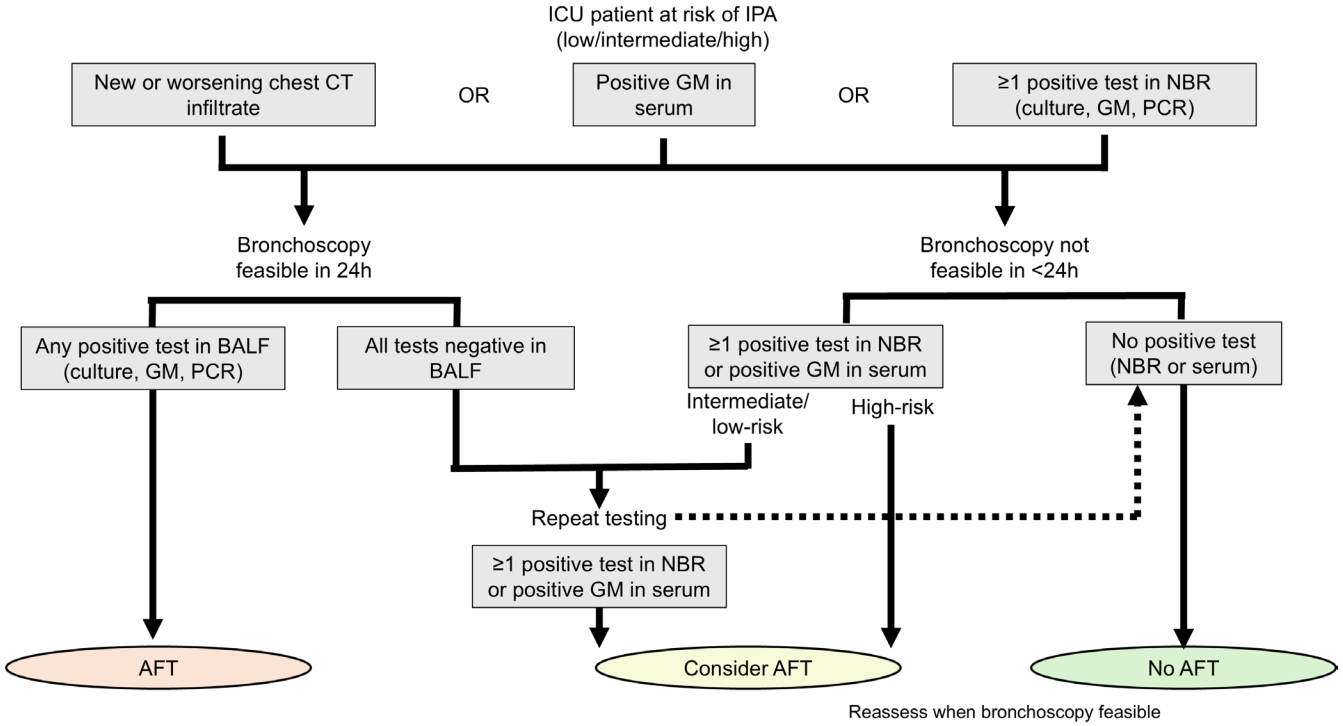

FIGURE 2 | Algorithm for the management of intensive care unit patients at risk of invasive pulmonary aspergillosis. AFT, antifungal therapy; BALF, bronchoalveolar lavage fluid; CT, computed tomography; GM, galactomannan; HC, patients with hematologic cancer; ICU, intensive care unit; IPA, invasive pulmonary aspergillosis; NBR, non-bronchoscopic respiratory samples; PCR, polymerase chain reaction.

advantages over voriconazole in terms of pharmacokinetic or safety profiles.

Lipid formulations of amphotericin B have also been used for the treatment of IPA in ICU [35, 91, 118]. They represent the best alternative option in patients with end-stage chronic or severe acute liver disease [19, 20]. Their use is limited in patients with renal failure because of nephrotoxicity with a global incidence of about 10%–15% [169–171]. Mainly L-amphotericin B is available in Switzerland and it has been associated with a lower risk of nephrotoxicity compared to other amphotericin B lipid formulations [171–173]. However, studies suggested a relatively high incidence of worsening renal function (about 25%) in ICU patients who are at high risk of acute renal injury due to critical illness severity and co-medications (diuretics, vasopressors) [174, 175]. Echinocandins (mainly caspofungin) have been used with variable success rates (30%–50%) for the treatment of IPA but comparative trials, as well as specific ICU data, are lacking [126, 127, 154, 176]. A randomised trial showed a trend (but not significant) towards improved outcomes with a combination of anidulafungin and voriconazole compared to voriconazole alone for the treatment of IPA in patients with hematologic cancer [128]. A significant benefit was observed in the subgroup of patients with GM-positive IPA. While these results cannot be extrapolated to ICU, the panel suggests that this combination may be considered for severe IPA (see details in the footnote of Table 4).

While the rate of azole resistance among *A. fumigatus* is currently low in Switzerland (about 1% among clinical isolates), environmental studies suggest that it is emerging [177, 178]. Therefore, we recommend performing antifungal susceptibility testing for every *Aspergillus* spp. isolated from ICU respiratory samples. If azole resistance is confirmed or suspected (i.e., transfer from an ICU unit located in an endemic area or mould-active azole breakthrough infection), we favor treatment with L-amphotericin B [129, 179]. In case of toxicity concern (i.e., kidney dysfunction), novel antifungal agents, such as fosmanogepix or olorofim, can be considered if available [130, 131]. Other options include a combination of a triazole with an echinocandin or high-dose posaconazole (for targeted plasma trough concentrations of 3–6 mg/L with strict monitoring of adverse events), although evidence supporting the clinical efficacy of these regimens is scarce [132, 133, 179].

An algorithm for guidance of therapeutic choice is provided in Figure 3.

6.3 | How Should Refractory IPA Be Treated?

The different options to consider in case of failure of initial AFT are presented in Table 4. Switch of antifungal drug classes (from triazoles to L-amphotericin B, or inversely) or combination therapies including an echinocandin represents the preferred options. Novel antifungal drugs (e.g., fosmanogepix, olorofim) may also be considered if available.

Discussion. There is no clear consensual definition for refractory IPA in ICU. In case of worsening clinical or radiological signs despite AFT for > 7 days, physicians should first consider repeating bronchoscopy and searching for an alternative explanation (e.g., insufficient drug exposure, alternative diagnosis). Several options are available for IPA not responding to

TABLE 4 | Recommendations for antifungal therapy of invasive pulmonary aspergillosis in intensive care unit patients.

Therapeutic interventions	SoR	QoE[a]	QoE[b]	Comments	References
First-line AFT					
Voriconazole (VOR)	A	I	II	First-line agent for patients with low risk of liver or neurological toxicity, absence of QTc prolongation or important DDI	[24, 35, 50, 74, 91, 118–121]
Isavuconazole (ISA)	A	I	II	First-line agent, to be preferred in case of liver injury or neurological toxicity, risk of QTc prolongation, renal failure (if IV formulation is warranted)	[35, 91, 122, 123]
Liposomal amphotericin B (L-AMB)[c]	B	II	II	May be preferred over triazoles in case of severe acute or chronic liver dysfunction	[20, 35, 91, 118, 124]
Posaconazole (POS)	B	I	II	Limited experience in ICU	[35, 91, 125]
Echinocandin[d]	C	II	III	To be restricted to situations where none of the above options is acceptable (due to toxicity issues)	[35, 91, 118, 126, 127]
Combined triazole[e] and echinocandin[d]	C	I	III	May be considered for severe cases[f]	[91, 128]
AFT for suspected or documented azole resistance					
Liposomal amphotericin B (L-AMB)[c]	A	II	III	First-line agent whenever possible	[129]
Novel antifungal drugs (fosmanogepix, olorofim)	B	III	III	According to availability. Note: experience is currently limited with these drugs	[130, 131]
Combined triazole[e] and echinocandin[d]	C	III	III	In vitro synergism, lack of clinical data. Should be limited to scenarios where other options are not possible[g]	[132]
High-dose posaconazole (POS)	C	III	III	Strict TDM for targeted plasma trough concentrations 3–6 mg/L and close clinical monitoring of adverse events (risk of toxicity) Should be limited to scenarios where other options are not possible[g]	[133]
AFT for refractory IPA					
Change of antifungal class	A	II	III	L-AMB if failure of initial triazole therapy. Triazole[e] if failure of initial L-AMB therapy	[134–136] [134, 137–143]
Combination AFT[h]	B	II	III	Triazole[e] and echinocandin	[144–148]
				L-AMB and echinocandin	[146, 147, 149–152]
				L-AMB and triazole[e]	[147]
Novel antifungal drugs (fosmanogepix, olorofim)	B	III	III	According to availability. Note: experience is currently limited with these drugs	[130, 131]

(Continues)

TABLE 4 | (Continued)

Therapeutic interventions	SoR	QoE[a]	QoE[b]	Comments	References
Change of antifungal drug within same class	C	III	III	Change of triazole[e] To consider mainly when failure is attributed to insufficient drug exposure	[133, 137, 141, 153]
Echinocandin[d] monotherapy	C	II	III	To be restricted to situations where none of the above options is acceptable (due to toxicity issues)	[151, 154–157]
Adjunctive interventions					
Nebulized L-AMB	B	III	III	As adjunctive therapy mainly in *Aspergillus* tracheobronchitis	[158, 159]
Bronchoscopic debridement	C	III	III	For selected cases of severe *Aspergillus* tracheobronchitis	[160, 161]
Surgery	C	III	III	For selected cases (large lung lesions or extra-pulmonary lesions)	[162]
Arterial embolization	C	III	III	For selected cases (pseudoaneurysms, major hemoptysis)	[163]
Immunomodulatory drugs (Interferon gamma, G-CSF)	C	III	III	For selected cases (refractory IPA)	[164, 165]

Abbreviations: AFT, antifungal therapy; DDI, drug–drug interactions; G-CSF, granulocyte-colony stimulating factor; ICU, intensive care unit; IPA, invasive pulmonary aspergillosis; IV, intravenous; QoE, quality of evidence; QTc, corrected QT interval of electrocardiogram; SoR, strength of recommendation; TDM, therapeutic drug monitoring.
[a]Patients with hematologic cancer.
[b]All ICU patients other than those with hematologic cancer.
[c]Other lipid amphotericin B formulations (e.g., lipid complex, colloidal dispersion) have limited availability in Switzerland. Amphotericin B deoxycholate is not recommended due to toxicity.
[d]Caspofungin or anidulafungin (micafungin has limited availability in Switzerland).
[e]Voriconazole, isavuconazole or posaconazole.
[f]Examples where combined triazole and echinocandin therapy may be considered: patients with hematologic cancer classified in the high-risk category (see Table 1) and/or factors of bad prognosis, such as positive galactomannan in serum or no expected recovery of immunosuppression (or other underlying condition at risk). In these scenarios, combination therapy may be administered for one or two weeks until favourable response to therapy and/or documentation of appropriate plasma trough concentration of the triazole.
[g]For instance, severe kidney dysfunction precluding use of L-amphotericin B.
[h]Combination AFT may be considered for refractory IPA for instance when a toxicity issue precludes a switch of antifungal drug classes (e.g., L-amphotericin B and an echinocandin in case of severe liver dysfunction or a triazole and an echinocandin in case of severe kidney dysfunction).

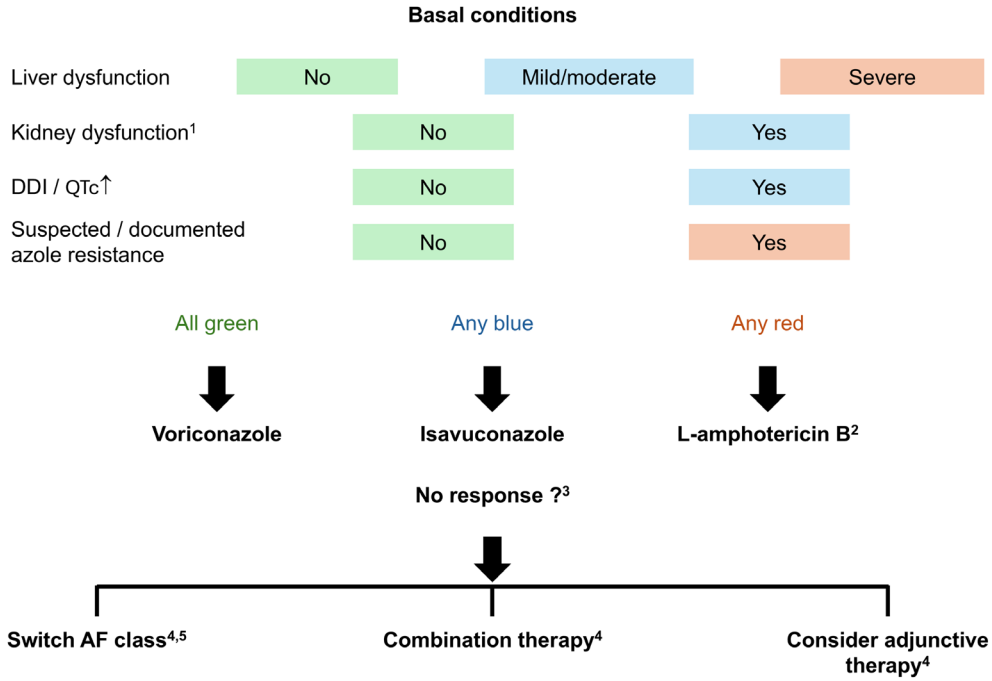

FIGURE 3 | Algorithm for guidance of therapeutic choices for invasive pulmonary aspergillosis in intensive care unit patients. DDI, drug-drug interactions; QTc, corrected QT interval at electrocardiogram. [1]Refers to moderate or severe kidney dysfunction (e.g., estimated glomerular filtration rate [GFR] < 30 mL/min or increase of serum creatinine ≥ 50% from baseline). [2]Alternatively, novel antifungal agents, such as fosmanogepix or olorofim, can be used if available (for instance: In case of severe renal dysfunction precluding use of L-amphotericin B). Of note, experience is currently limited with these new drugs. [3]Assess cause of lack of response, which may guide therapeutic decisions (see Table 4). [4]See details and recommendations for different options in Table 4. [5]Novel antifungal agents, such as fosmanogepix or olorofim, can also be considered if available and in case of limited alternative options. Of note, experience is currently limited with these new drugs.

first-line AFT, of which none has demonstrated to be superior to the other. Most clinical trials or cohort studies addressing the efficacy of salvage therapies have been performed in patients with hematologic cancer or other immunosuppressive conditions [137, 144–146, 155]. Data specific to ICU are lacking. The switch of antifungal drug classes between triazoles and L-amphotericin B seems the most appropriate option because of the good efficacy of these drug classes as first-line AFT [120, 180]. Combination AFTs with the addition of an echinocandin to a triazole or L-amphotericin B are common practice, although their superiority to monotherapies remains controversial [134, 145, 146, 149]. If available, novel antifungal drugs (e.g., fosmanogepix, olorofim) can be considered in selected cases [130, 131]. The switch of drug within the same class (mainly triazoles) should be restricted to situations where failure is attributed to insufficient drug exposure or toxicity [137, 138]. Echinocandin monotherapy should be avoided unless there is no other option, because of concern about efficacy and lack of appropriate exposure in ICU patients [127, 176, 181]. Finally, adjunctive therapeutic interventions (e.g., inhaled AFT, surgery, immunomodulation) can be considered.

6.4 | Which Adjunctive Therapeutic Interventions Can Be Considered for IPA Treatment?

Little evidence supports the use of adjunctive therapeutic interventions, which may be considered in selected cases of severe or refractory IPA. These interventions are summarised in Table 4.

Discussion. Use of nebulized L-amphotericin B has been mentioned in some case reports of CAPA or IAPA (mainly *Aspergillus* tracheobronchitis) with good tolerance [158, 159, 182]. Therefore, the panel suggests that it might be considered as adjunctive therapy in severe *Aspergillus* tracheobronchitis, which is associated with high mortality rates [114, 183, 184]. Opelconazole is a novel triazole designed for inhalation use, which is currently being tested as adjunctive therapy for refractory IPA in a randomised placebo-controlled trial (OPERA-T study, NCT05238116).

Surgery may be considered in rare situations, such as pulmonary lesions at risk of bleeding or large cavitary lesions [162]. Embolization of affected vessels has also been reported for pseudoaneurysms and severe hemoptysis [163]. The use of immunomodulatory drugs (e.g., interferon gamma) or granulocyte colony-stimulating factors (G-CSF) has been marginally reported [164, 165]. Short use of steroids during ICU stay has been associated with increased risk of IAPA and CAPA [24, 78]. The continuation of such short-term corticosteroid therapy should be reassessed in patients with IPA on an individual basis. While the benefit of steroids has been demonstrated for CAPA [185], it is not recommended in IAPA [186].

6.5 | How Should AFT Be Adapted in the ICU Setting?

Recommendations for TDM and dosing adjustment of antifungal drugs according to specific ICU situations are provided in Table 5.

TABLE 5 | Recommendations for dosing adjustment and therapeutic drug monitoring of antifungal drugs in intensive care unit patients.

Antifungal drug	Dosing	Renal dysfunction	Liver dysfunction	ECMO	Weight	Nasogastric tube	TDM recommendation, SoR, QoE; target; timing interval
Voriconazole (VOR)	6 mg/kg q12h (day 1) 4 mg/kg q12h (from day 2)	AD+TDM[a] Favour oral VOR or alternative (e.g., ISA) if severe renal dysfunction[b]	Mild/ moderate: AD+TDM[a] Severe: favour alternative (ISA or L-AMB)	AD+TDM[a]	AD (until max. 100 kg)+TDM[a]	Tablets can be crushed or suspended in water	A, II For all patients (1.5–5 mg/L) 5 days[c]
Isavuconazole (ISA)	200 mg q8h (day 1 and 2) 200 mg q24h (from day 3)	SD	Mild/ moderate: SD Severe: SD+TDM[d]	SD+TDM[d]	SD+TDM[d]	Opened capsules or intravenous formulation	C, II For selected situations (e.g., ECMO, obesity severe liver dysfunction) (> 2 mg/L)[e] 5 days
Posaconazole (POS)	300 mg q12h (day 1) 300 mg q24h (from day 2)	SD+TDM[d] Favour oral POS or alternative (e.g., ISA) if severe renal dysfunction[b]	Mild/ moderate: SD+TDM[d] Severe: favour alternative (ISA or L-AMB)	SD+TDM[d]	SD+TDM[d] (increase to 400 mg q24h if weight > 140 kg)	Favour alternative (VOR or ISA) Tablets can be crushed if no alternative	A, II For all patients (prophylaxis: > 0.7 mg/L; therapy: > 1 mg/L) 5 days[c]
L-amphotericin B (L-AMB)	3–5 mg/kg q24h	AD Favour alternative if severe renal dysfunction, RRT or concomitant nephrotoxic drugs	AD	AD Caution: lack of data. Favour alternative if possible	AD (until max. 100 kg)	Not applicable	D, III Not recommended
Caspofungin (CAS)	70 mg q24h (day 1) 50 mg q24h (from day 2)	SD	Mild: SD Moderate/ severe: favour alternative (e.g., ANI)	SD	Increased dose may be considered in patients > 80 kg (e.g., 70 mg q24h)	Not applicable	C, III For selected situations (e.g., obese patients)

(Continues)

TABLE 5 | (Continued)

Antifungal drug	Dosing	Renal dysfunction	Liver dysfunction	ECMO	Weight	Nasogastric tube	TDM recommendation, SoR, QoE; target; timing interval
Anidulafungin (ANI)	200 mg q24h (day 1) 100 mg q24h (from day 2)	SD	SD	SD	SD (increased dose may be considered in patients > 140 kg)	Not applicable	C, III For selected situations (e.g., obese patients)

Abbreviations: AD, adjusted dosing according to weight; ECMO, extracorporeal membrane oxygenation; QoE, quality of evidence; RRT, renal replacement therapy; SD, standard dosing; SoR, strength of recommendation; TDM, therapeutic drug monitoring.
[a]AD+TDM: initial dosing adjusted to weight, then adjusted according to TDM. Note: adjusted body weight should be used (instead of actual weight).
[b]Accumulation of the sulfobutylether-beta-cyclodextrin (SBECD) component present in the intravenous formulation.
[c]An additional earlier measurement (day 2 or 3) can be considered if toxicity is suspected.
[d]SD + TDM: initial standard dosing, then adjust according to TDM.
[e]Based on population pharmacokinetic data (no established correlation with outcomes or toxicity).

Discussion. Administering effective AFT and achieving therapeutic drug levels is challenging in critically ill patients, who often have renal or liver impairment, hypoalbuminemia, and capillary leakage syndrome [187]. These conditions, combined with polypharmacy and procedures like RRT or ECMO, can significantly alter drug levels. Overall, antifungal agents achieve low rates of exposure and target attainment in ICU patients [188]. Therefore, dose adaptations are essential for therapeutic success.

Antifungal drugs used for IPA treatment usually do not require dosing adaptation in case of renal dysfunction or RRT considering their hepatobiliary clearance. The cyclodextrin component associated with voriconazole and posaconazole in the intravenous formulation may accumulate in case of renal insufficiency [189]. However, several studies have assessed the safety of these intravenous formulations in patients with renal dysfunction or RRT without the need for dosing adjustment [190–194].

In patients with severe liver impairment, voriconazole clearance is affected, which may result in increased exposure and toxicity [195]. Alternative AFT should be considered in this setting. Use of isavuconazole in patients with mild or moderate liver impairment was shown to be safe [196–198]. Although some increase in isavuconazole exposure can be expected, no dosing adjustment is required [199, 200]. Isavuconazole should be used cautiously in patients with severe liver impairment for whom data are lacking. Among echinocandins, some decrease in caspofungin clearance has been observed in patients with moderate/severe liver impairment, but the need for dosing adjustment is debated [201, 202]. An alternative echinocandin (e.g., anidulafungin) should be considered in this setting.

For patients under ECMO, some circuit loss can be expected for the triazoles (voriconazole, posaconazole and isavuconazole), although exposure is usually not significantly affected and initial dosing adjustment is not warranted [203–207]. Similar observations have been reported for echinocandins [203, 205, 208, 209]. For L-amphotericin B, data are scarce but suggest significant circuit loss [203, 205]. For patients with a nasogastric tube, oral administration of triazoles is possible using crushed tablets (voriconazole, posaconazole), opened capsules (isavuconazole) or intravenous solution (isavuconazole) [210–215].

For overweight patients, dosing of L-amphotericin B and voriconazole in dose/kg should be based on the adjusted body weight (rather than the actual body weight) until a maximum of 100 kg [216, 217]. For posaconazole, the results of one study support an increased initial dosing in patients weighing > 140 kg [218]. Dose increases can also be considered for the use of echinocandins in patients weighing > 80 kg [216, 219–221].

TDM (i.e., measurement of plasma trough concentrations) is recommended for all patients receiving voriconazole and posaconazole considering important interindividual variability and should be performed once steady state is reached (i.e., from day 5) [7, 8]. For voriconazole, trough concentrations have been correlated with therapeutic success and neurotoxicity for cut-offs of ≥ 1–2 mg/L and 5–5.5 mg/L, respectively [222–225]. For posaconazole, trough concentration cut-offs of 0.7 mg/L and 1 mg/L have been proposed for prophylaxis and therapy,

respectively [8]. However, these cut-offs are based on pharmacokinetic models and there is little evidence of correlation with outcomes [137, 226–228]. The upper cut-off has been set at 3.75 mg/L, although there is no clear correlation between high posaconazole concentrations and toxicity [8, 133, 229]. Pharmacokinetic profiles of patients receiving isavuconazole were more stable showing no correlation with outcomes or toxicity [230–232]. A pharmacokinetic study in critically ill patients did not find any significant impact of various parameters on isavuconazole concentrations [233]. Therefore, isavuconazole TDM is not routinely recommended but may be considered in selected cases (e.g., failure of therapy, suspicion of toxicity, DDI, ECMO, severe liver dysfunction or obesity). TDM for echinocandins is not routinely recommended and is not available in most centers [234]. Echinocandin plasma concentrations were found to be highly variable and unpredictable with overall lower concentrations in ICU patients compared to others [181, 235, 236]. Although no cut-off has been associated with outcomes, TDM for echinocandins (if available) could be considered in selected critically ill patients to ensure adequate exposure [237]. TDM for amphotericin B is complex because of the different lipid formulations and is not routinely recommended [237].

6.6 | What Is the Optimal Follow-Up and Treatment Duration for IPA in ICU?

Follow-up chest CT is recommended at 4–6 weeks from the start of AFT or earlier in case of lack of clinical improvement (A III). Monitoring of serum GM is recommended once weekly if the initial value was positive (i.e., ≥ 0.5 ODI) until it turns negative (A II). Duration of AFT should be assessed on an individual basis considering the presence/absence of underlying immunosuppressive conditions, the recovery of immune status and the response to therapy. In patients with proven or probable IPA, we recommend a minimum of 4–6 weeks and 6–12 weeks in patients without and with host factors of immunosuppression, respectively (B III). In patients with possible IPA, earlier discontinuation of AFT (i.e., < 4 weeks) can be considered in selected situations. These recommendations, as well as those for safety monitoring during AFT, are shown in Table 6.

Discussion. Assessing clinical response is complex due to the lack of reliable markers. Consensus criteria for response to AFT, based on clinical, radiological, and mycological factors, have been mainly defined for hematologic patients [8, 238]. Radiological response in ICU patients with IPA is difficult to assess because of the lack of specificity of lung CT lesions, which frequently overlap with patterns of viral infection (influenza, COVID-19) and secondary bacterial infections. We recommend performing follow-up chest CT at 4–6 weeks from the start of AFT to look for complications (e.g., cavity formation), which may impact the duration of therapy, or earlier in case of lack of clinical improvement. Monitoring of serum GM (in case of positive initial value) was shown to have a good prognostic value in IPA follow-up of immunocompromised patients [239, 240]. However, this marker is rarely positive in ICU patients with IPA except in IAPA.

Regarding safety monitoring, the frequency of TDM (when indicated) should be determined according to the timing of the steady state of the AF drug and the intra-individual variability of plasma drug levels. Overall, we recommend performing TDM once weekly during the ICU stay and then according to the clinical situation and the intra-individual variability of previous measurements.

Other safety monitoring interventions should include hepatic tests and electrocardiogram (measurement of QT interval) for triazoles, and serum creatinine and potassium (with magnesium in case of hypokalemia) for L-amphotericin B.

Recommendations for the duration of AFT in IPA are based on very little evidence and are highly dependent on the individual response to therapy and recovery of immunity [241]. Guidelines recommend a minimum duration of 6–12 weeks in immunocompromised patients (i.e., patients with EORTC-MSGERC host criteria) [7]. The context is quite different in ICU where most patients developing IPA have no EORTC-MSGERC host criteria and are exposed to a relatively short vulnerability period (i.e., duration of ICU stay, mechanical ventilation). We consider that, for proven/probable IPA in the absence of EORTC-MSGERC host criteria, AFT can be discontinued after a minimum of 4–6 weeks provided that clinical/radiological/microbiological response to therapy is favourable (complete or near complete response), mechanical ventilation has been discontinued, and the patient has been discharged from ICU. Among patients classified as possible IPA, earlier discontinuation of AFT (i.e., < 4 weeks) can be considered if the patients fulfill these criteria.

6.7 | Which Are the Recommendations for Antifungal Prophylaxis and Other Preventive Measures for IPA in ICU?

Antifungal prophylaxis with posaconazole is recommended in high-risk hematologic cancer patients (i.e., prolonged neutropenia or allogeneic HCT with severe graft versus host disease) (A I). It is generally not recommended in other ICU patients. Prophylaxis with posaconazole or nebulized L-amphotericin B may be considered in severe COVID-19 patients in a setting of high CAPA incidence (i.e., ≥ 10%, C II). We do not recommend prophylaxis in severe influenza because of the early onset of IAPA in these patients (D, I). Nebulized L-amphotericin B can be administered for the prevention of IPA in lung transplant recipients during the immediate post-transplantation period (B II). Close adherence to local infection prevention and control protocols should be followed in ICU to avoid spore contamination (A III).

Discussion. Posaconazole prophylaxis was shown to significantly reduce the incidence of IPA in patients with hematologic cancer and prolonged neutropenia or allogeneic HCT and severe graft-versus-host disease [14, 15]. Its benefit in other subgroups of patients has not been clearly demonstrated. Despite some favourable trends, a randomised trial failed to demonstrate the benefit of posaconazole prophylaxis in severe influenza because of the high incidence of early IAPA [67]. In two observational studies, CAPA incidence was lower among patients who received posaconazole prophylaxis compared to those who did not [242, 243]. Similarly, observational studies suggest that nebulized amphotericin B may lower CAPA

TABLE 6 | Follow-up and duration of antifungal therapy for invasive pulmonary aspergillosis in intensive care unit patients.

Intervention	Frequency	Recommendation SoR, QoE
TDM (when indicated)[a]	After 5 days from start of AFT, then every 5–7 days until ICU discharge, then on an individual basis (at least once every 2 weeks)	A, III
Safety monitoring		
Hepatic tests[b] (VOR, POS, ISA)	At initiation of AFT, then twice during the first week, then once weekly if within normal range of values	A, III
Serum creatinine (L-AMB)	At initiation of AFT, then 3 times weekly	A, III
Serum potassium (L-AMB)	At initiation of AFT, then 3 times weekly	A, III
ECG QT interval (VOR, POS)[c]	At initiation of AFT, then after 2-3 days, then at every change of medications with potential effect on QT interval[d]	A, IIII
Assessment of therapeutic response		
Serum GM	If initial testing positive (ODI ≥ 0.5): once weekly until negative	A, II
Chest CT	At 4–6 weeks from start of AFT if favourable clinical course[e]	A, III
Bronchoscopy with BALF	In case of clinical deterioration	B, III
Duration of therapy		
Presence of EORTC-MSGERC criteria	Minimum 6–12 weeks[f]	B, III
Absence of EORTC-MSGERC criteria	Minimum 4–6 weeks[g]	B, III

Abbreviations: AFT, antifungal therapy; BALF, bronchoalveolar lavage fluid; CT, computed tomography; EORTC-MSGERC, European Organisation for Research and Treatment of Cancer—Mycoses Study Group Education and Research Consortium; GM, galactomannan; ICU, intensive care units; ISA, isavuconazole; L-AMB, liposomal amphotericin B; ODI, optical density index; POS, posaconazole; QoE, quality of evidence; SoR, strength of recommendation; TDM, therapeutic drug monitoring; VOR, voriconazole.
[a]For TDM indications, see Table 5.
[b]Alanine aminotransferase, aspartate aminotransferase, alkaline phosphatase, gamma-glutamyl transferase, total bilirubin.
[c]Isavuconazole has been associated with a shortened (instead of prolonged) QT interval. For isavuconazole, congenital short QT interval should be excluded by ECG before starting therapy. We do not recommend further monitoring during the course of therapy unless otherwise indicated.
[d]Closer monitoring may be required for patients with corrected QT interval at the upper limit (> 440 ms). Change of therapy (e.g., isavuconazole) should be considered if corrected QT > 480 ms in females or > 470 ms in males.
[e]Earlier chest CT (i.e., at 2 weeks from start of AFT) should be considered in patients with immunosuppressive conditions (EORTC-MSGERC criteria) or in case of a lack of clinical improvement.
[f]Depending on clinical/radiological/microbiological response to therapy and recovery of immunity.
[g]Depending on clinical/radiological/microbiological response and recovery of critically ill conditions (i.e., interruption of mechanical ventilation and ICU discharge).

incidence [242, 243]. Nebulized L-amphotericin B was shown to be safe and is widely prescribed for the prevention of IPA in lung transplant recipients [244–247]. However, randomised controlled studies are lacking and the duration of prophylaxis is debated.

Since the incidence of IPA in ICU, in particular IAPA and CAPA, displays very important variations between centers, the role of environmental factors (e.g., contamination of rooms or ventilation systems) has been suspected. Genotype studies of *Aspergillus* clinical isolates and environmental samples to assess the source of acquisition (i.e., nosocomial or community-acquired) provided controversial results [248–250]. Nonetheless, hospital control measures to lower the risk of spore airborne contamination should be implemented.

Author Contributions

F. Lamoth: conceptualization, investigation, funding acquisition, writing – original draft, methodology, validation, supervision. **W. C. Albrich:** conceptualization, investigation, funding acquisition, writing – original draft, methodology, validation, supervision. **S. Ragozzino:** investigation, writing – review and editing. **D. Bosetti:** investigation, writing – review and editing. **J. Delaloye:** investigation, writing – review and editing. **C. El Khoury:** investigation, writing – review and editing. **A. Munting:** investigation, writing – review and editing, investigation. **V. Portillo:** investigation, writing – review and editing. **I. Reinhold:** investigation, writing – review and editing. **J. Sumer:** investigation, writing – review and editing. **A. Zbinden:** investigation, writing – review and editing. **V. Bättig:** investigation, writing – review and editing. **C. Beigelman-Aubry:** investigation, writing – review and editing. **K. Boggian:** investigation,

writing – review and editing. **A. Conen:** investigation, writing – review and editing. **T. S. Fischer:** investigation, writing – review and editing. **C. Garzoni:** investigation, writing – review and editing. **D. Goldenberger:** investigation, writing – review and editing. **E. Hofmann:** investigation, writing – review and editing. **P. Khafagy:** investigation, writing – review and editing. **L. Kern:** investigation, writing – review and editing. **G. R. Kleger:** investigation, writing – review and editing. **C. Le Terrier:** investigation, writing – review and editing. **O. Marchetti:** investigation, writing – review and editing. **J. L. Pagani:** investigation, writing – review and editing. **N. J. Rupp:** investigation, writing – review and editing. **P. W. Schreiber:** investigation, writing – review and editing. **M. Siegemund:** investigation, writing – review and editing. **F. Kadgien:** investigation, writing – review and editing. **D. Neofytos:** conceptualization, investigation, funding acquisition, writing – original draft, methodology, validation, supervision. **N. Khanna:** conceptualization, investigation, funding acquisition, writing – original draft, methodology, validation, supervision.

Acknowledgements

Open access publishing facilitated by Universite de Lausanne, as part of the Wiley - Universite de Lausanne agreement via the Consortium Of Swiss Academic Libraries. Werner Albrich, Christoph Berger, Anne Bergeron, Sabina Berezowska, Pierre-Yves Bochud, Katia Boggian, Anna Conen, Julie Delaloye, Stéphane Emonet, Véronique Erard, Christian Garzoni, Daniel Goldenberger, Vladimira Hinic, Cedric Hirzel, Eleftheria Evdokia Kampouri, Nina Khanna, Malte Kohns, Andreas Kronenberg, Frederic Lamoth, Basile Landis, Oscar Marchetti, Konrad Mühlethaler, Linda Müller, Dionysios Neofytos, Michael Osthoff, Jean-Luc Pagani, Chantal Quiblier, Arnaud Riat, Niels Rupp, Bettina Schulthess, Peter Werner Schreiber, Martin Siegemund, Laura Walti.

Conflicts of Interest

Outside of the present work: F. Lamoth: research funding from MSD, Pfizer and Novartis, speaker honoraria from Gilead, MSD, Pfizer, Mundipharma and Becton-Dickinson. W. Albrich: speaker honoraria from Pfizer, GSK, MSD and A. Vogel; travel support from Pfizer, Gilead and GSK; participation in advisory boards for Pfizer, MSD, GSK, Sanofi, Moderna, Janssen and Aurovir. I. Reinhold: speaker honoraria from Menarini Group. J. Sumer: travel support from Gilead. V. Bättig: travel support from Gilead. A. Conen: travel support from Gilead. E. Hofmann: travel support from Gilead and Astra Zeneca. C. Le Terrier: speaker and advisory boards honoraria from Advanz Pharma. N.J. Rupp: travel support from Roche Diagnostics AG, honoraria for advisory board from AbbVie AG. P.W. Schreiber: travel supports from Pfizer and Gilead. F. Kadgien: travel supports from Tillots and Gilead. D. Neofytos: research grants from MSD, Pfizer and Takeda, speaker honoraria from Pfizer, Gilead, MSD and Takeda, participation on advisory board for Novo Nordisk and travel support from Gilead. N. Khanna: honoraria for conferences, data safety monitoring boards or advisory boards from Gilead, MSD, Pfizer, Idorsia, Takeda and Pulmicide.

Data Availability Statement

Data sharing not applicable to this article as no datasets were generated or analysed during the current study.

References

1. D. Koulenti, G. Papathanakos, and S. Blot, "Invasive Pulmonary Aspergillosis in the ICU: Tale of a Broadening Risk Profile," *Current Opinion in Critical Care* 29 (2023): 463–469.

2. L. Townsend and I. Martin-Loeches, "Invasive Aspergillosis in the Intensive Care Unit," *Diagnostics (Basel, Switzerland)* 12 (2022): 2712.

3. M. Bassetti, D. R. Giacobbe, C. Agvald-Ohman, et al., "Invasive Fungal Diseases in Adult Patients in Intensive Care Unit (FUNDICU): 2024 Consensus Definitions From ESGCIP, EFISG, ESICM, ECMM, MSGERC, ISAC, and ISHAM," *Intensive Care Medicine* 50 (2024): 502–515.

4. S. I. Blot, F. S. Taccone, A. M. van den Abeele, et al., "A Clinical Algorithm to Diagnose Invasive Pulmonary Aspergillosis in Critically Ill Patients," *American Journal of Respiratory and Critical Care Medicine* 186 (2012): 56–64.

5. P. Koehler, M. Bassetti, A. Chakrabarti, et al., "Defining and Managing COVID-19-Associated Pulmonary Aspergillosis: The 2020 ECMM/ISHAM Consensus Criteria for Research and Clinical Guidance," *Lancet Infectious Diseases* 21 (2020): e149-e62.

6. P. E. Verweij, B. J. A. Rijnders, R. J. M. Bruggemann, et al., "Review of Influenza-Associated Pulmonary Aspergillosis in ICU Patients and Proposal for a Case Definition: An Expert Opinion," *Intensive Care Medicine* 46 (2020): 1524–1535.

7. T. F. Patterson, G. R. Thompson, 3rd, D. W. Denning, et al., "Practice Guidelines for the Diagnosis and Management of Aspergillosis: 2016 Update by the Infectious Diseases Society of America," *Clinical Infectious Diseases* 63 (2016): e1–e60.

8. A. J. Ullmann, J. M. Aguado, S. Arikan-Akdagli, et al., "Diagnosis and Management of Aspergillus Diseases: Executive Summary of the 2017 ESCMID-ECMM-ERS Guideline," *Clinical Microbiology and Infection* 24, no. Suppl 1 (2018): e1–e38.

9. S. Corcione, T. Lupia, S. Raviolo, et al., "Putative Invasive Pulmonary Aspergillosis Within Medical Wards and Intensive Care Units: A 4-Year Retrospective, Observational, Single-Centre Study," *Internal and Emergency Medicine* 16 (2021): 1619–1627.

10. K. H. Vandewoude, S. I. Blot, D. Benoit, F. Colardyn, and D. Vogelaers, "Invasive Aspergillosis in Critically Ill Patients: Attributable Mortality and Excesses in Length of ICU Stay and Ventilator Dependence," *Journal of Hospital Infection* 56 (2004): 269–276.

11. W. Meersseman, S. J. Vandecasteele, A. Wilmer, E. Verbeken, W. E. Peetermans, and E. Van Wijngaerden, "Invasive Aspergillosis in Critically Ill Patients Without Malignancy," *American Journal of Respiratory and Critical Care Medicine* 170 (2004): 621–625.

12. E. Azoulay, D. Mokart, F. Pene, et al., "Outcomes of Critically Ill Patients With Hematologic Malignancies: Prospective Multicenter Data From France and Belgium–A Groupe de Recherche Respiratoire en Reanimation Onco-Hematologique Study," *Journal of Clinical Oncology* 31 (2013): 2810–2818.

13. L. Pagano, M. Caira, A. Candoni, et al., "The Epidemiology of Fungal Infections in Patients With Hematologic Malignancies: The SEIFEM-2004 Study," *Haematologica* 91 (2006): 1068–1075.

14. O. A. Cornely, J. Maertens, D. J. Winston, et al., "Posaconazole vs. Fluconazole or Itraconazole Prophylaxis in Patients With Neutropenia," *New England Journal of Medicine* 356 (2007): 348–359.

15. A. J. Ullmann, J. H. Lipton, D. H. Vesole, et al., "Posaconazole or Fluconazole for Prophylaxis in Severe Graft-Versus-Host Disease," *New England Journal of Medicine* 356 (2007): 335–347.

16. D. Neofytos, O. Chatzis, D. Nasioudis, et al., "Epidemiology, Risk Factors and Outcomes of Invasive Aspergillosis in Solid Organ Transplant Recipients in the Swiss Transplant Cohort Study," *Transplant Infectious Disease* 20 (2018): e12898.

17. P. G. Pappas, B. D. Alexander, D. R. Andes, et al., "Invasive Fungal Infections Among Organ Transplant Recipients: Results of the Transplant-Associated Infection Surveillance Network (TRANSNET)," *Clinical Infectious Diseases* 50 (2010): 1101–1111.

18. T. Gustot, E. Maillart, M. Bocci, et al., "Invasive Aspergillosis in Patients With Severe Alcoholic Hepatitis," *Journal of Hepatology* 60 (2014): 267–274.

19. T. Lahmer, A. Brandl, S. Rasch, et al., "Prevalence and Outcome of Invasive Pulmonary Aspergillosis in Critically Ill Patients With Liver Cirrhosis: An Observational Study," *Scientific Reports* 9 (2019): 11919.

20. T. Lahmer, P. M. Pecanha-Pietrobom, R. M. Schmid, and A. L. Colombo, "Invasive Fungal Infections in Acute and Chronic Liver Impairment: A Systematic Review," *Mycoses* 65 (2022): 140–151.

21. E. Levesque, N. Ait-Ammar, D. Dudau, et al., "Invasive Pulmonary Aspergillosis in Cirrhotic Patients: Analysis of a 10-Year Clinical Experience," *Annals of Intensive Care* 9 (2019): 31.

22. X. Zhang, M. Yang, J. Hu, H. Zhao, and L. Li, "Epidemiology of Invasive Pulmonary Aspergillosis in Patients With Liver Failure: Clinical Presentation, Risk Factors, and Outcomes," *Journal of International Medical Research* 46 (2018): 819–827.

23. C. Delsuc, A. Cottereau, E. Frealle, et al., "Putative Invasive Pulmonary Aspergillosis in Critically Ill Patients With Chronic Obstructive Pulmonary Disease: A Matched Cohort Study," *Critical Care* 19 (2015): 421.

24. A. Schauwvlieghe, B. J. A. Rijnders, N. Philips, et al., "Invasive Aspergillosis in Patients Admitted to the Intensive Care Unit With Severe Influenza: A Retrospective Cohort Study," *Lancet Respiratory Medicine* 6 (2018): 782–792.

25. J. Ballard, L. Edelman, J. Saffle, et al., "Positive Fungal Cultures in Burn Patients: A Multicenter Review," *Journal of Burn Care & Research* 29 (2008): 213–221.

26. C. K. Murray, F. L. Loo, D. R. Hospenthal, et al., "Incidence of Systemic Fungal Infection and Related Mortality Following Severe Burns," *Burns* 34 (2008): 1108–1112.

27. J. V. Schaal, T. Leclerc, C. Soler, et al., "Epidemiology of Filamentous Fungal Infections in Burned Patients: A French Retrospective Study," *Burns* 41 (2015): 853–863.

28. C. Shi, Q. Shan, J. Xia, et al., "Incidence, Risk Factors and Mortality of Invasive Pulmonary Aspergillosis in Patients With Influenza: A Systematic Review and Meta-Analysis," *Mycoses* 65 (2022): 152–163.

29. W. H. Chong, B. K. Saha, and C. K. Tan, "Clinical Characteristics and Outcomes of Influenza-Associated Pulmonary Aspergillosis Among Critically Ill Patients: A Systematic Review and Meta-Analysis," *Journal of Hospital Infection* 120 (2022): 98–109.

30. L. Y. Lu, H. M. Lee, A. Burke, et al., "Prevalence, Risk Factors, Clinical Features, and Outcome of Influenza-Associated Pulmonary Aspergillosis in Critically Ill Patients: A Systematic Review and Meta-Analysis," *Chest* 165 (2024): 540–558.

31. I. S. Schwartz, D. Z. P. Friedman, L. Zapernick, et al., "High Rates of Influenza-Associated Invasive Pulmonary Aspergillosis May Not be Universal: A Retrospective Cohort Study From Alberta, Canada," *Clinical Infectious Diseases* 71, no. 7 (2020): 1760–1763.

32. S. Feys, K. Lagrou, H. M. Lauwers, et al., "High Burden of COVID-19-Associated Pulmonary Aspergillosis in Severely Immunocompromised Patients Requiring Mechanical Ventilation," *Clinical Infectious Diseases* 78 (2024): 361–370.

33. F. Gioia, L. N. Walti, A. Orchanian-Cheff, and S. Husain, "Risk Factors for COVID-19-Associated Pulmonary Aspergillosis: A Systematic Review and Meta-Analysis," *Lancet Respiratory Medicine* 12 (2024): 207–216.

34. R. M. Kariyawasam, T. C. Dingle, B. E. Kula, B. Vandermeer, W. I. Sligl, and I. S. Schwartz, "Defining COVID-19-Associated Pulmonary Aspergillosis: Systematic Review and Meta-Analysis," *Clinical Microbiology and Infection* 28 (2022): 920–927.

35. J. Salmanton-Garcia, R. Sprute, J. Stemler, et al., "COVID-19-Associated Pulmonary Aspergillosis, March-August 2020," *Emerging Infectious Diseases* 27 (2021): 1077–1086.

36. A. Fekkar, D. Neofytos, M. H. Nguyen, C. J. Clancy, D. P. Kontoyiannis, and F. Lamoth, "COVID-19-Associated Pulmonary Aspergillosis (CAPA): How Big a Problem Is It?," *Clinical Microbiology and Infection* 27 (2021): 1376–1378.

37. B. E. Kula, C. J. Clancy, M. Hong Nguyen, and I. S. Schwartz, "Invasive Mould Disease in Fatal COVID-19: A Systematic Review of Autopsies," *Lancet Microbe* 2 (2021): e405–e414.

38. B. Schurink, E. Roos, T. Radonic, et al., "Viral Presence and Immunopathology in Patients With Lethal COVID-19: A Prospective Autopsy Cohort Study," *Lancet Microbe* 1 (2020): e290–e299.

39. L. Vanderbeke, C. Jacobs, S. Feys, et al., "A Pathology-Based Case Series of Influenza- and COVID-19-Associated Pulmonary Aspergillosis: The Proof Is in the Tissue," *American Journal of Respiratory and Critical Care Medicine* 208 (2023): 301–311.

40. A. Rouze, E. Lemaitre, I. Martin-Loeches, et al., "Invasive Pulmonary Aspergillosis Among Intubated Patients With SARS-CoV-2 or Influenza Pneumonia: A European Multicenter Comparative Cohort Study," *Critical Care* 26 (2022): 11.

41. A. Fekkar, A. Lampros, J. Mayaux, et al., "Occurrence of Invasive Pulmonary Fungal Infections in Patients With Severe COVID-19 Admitted to the ICU," *American Journal of Respiratory and Critical Care Medicine* 203 (2021): 307–317.

42. J. P. Gangneux, E. Dannaoui, A. Fekkar, et al., "Fungal Infections in Mechanically Ventilated Patients With COVID-19 During the First Wave: The French Multicentre MYCOVID Study," *Lancet Respiratory Medicine* 10 (2022): 180–190.

43. J. Prattes, J. Wauters, D. R. Giacobbe, et al., "Risk Factors and Outcome of Pulmonary Aspergillosis in Critically Ill Coronavirus Disease 2019 Patients-A Multinational Observational Study by the European Confederation of Medical Mycology," *Clinical Microbiology and Infection* 28 (2022): 580–587.

44. F. Waldeck, F. Boroli, N. Suh, et al., "Influenza-Associated Aspergillosis in Critically-Ill Patients-A Retrospective Bicentric Cohort Study," *European Journal of Clinical Microbiology & Infectious Diseases* 39 (2020): 1915–1923.

45. F. Waldeck, F. Boroli, S. Zingg, et al., "Higher Risk for Influenza-Associated Pulmonary Aspergillosis (IAPA) in Asthmatic Patients: A Swiss Multicenter Cohort Study on IAPA in Critically Ill Influenza Patients," *Influenza and Other Respiratory Viruses* 17 (2023): e13059.

46. F. Lamoth, E. Glampedakis, N. Boillat-Blanco, M. Oddo, and J. L. Pagani, "Incidence of Invasive Pulmonary Aspergillosis Among Critically Ill COVID-19 Patients," *Clinical Microbiology and Infection* 26 (2020): 1706–1708.

47. F. Khasawneh, T. Mohamad, M. K. Moughrabieh, Z. Lai, J. Ager, and A. O. Soubani, "Isolation of Aspergillus in Critically Ill Patients: A Potential Marker of Poor Outcome," *Journal of Critical Care* 21 (2006): 322–327.

48. E. Pardo, V. Lemiale, D. Mokart, et al., "Invasive Pulmonary Aspergillosis in Critically Ill Patients With Hematological Malignancies," *Intensive Care Medicine* 45 (2019): 1732–1741.

49. J. Ahmed, G. Singh, A. Mohan, et al., "Invasive Pulmonary Aspergillosis Infection in Severely Ill COPD Patients in Pulmonary Ward and ICU," *Indian Journal of Medical Microbiology* 40 (2022): 223–227.

50. J. Guinea, M. Torres-Narbona, P. Gijon, et al., "Pulmonary Aspergillosis in Patients With Chronic Obstructive Pulmonary Disease: Incidence, Risk Factors, and Outcome," *Clinical Microbiology and Infection* 16 (2010): 870–877.

51. T. Mir, M. Uddin, A. Khalil, et al., "Mortality Outcomes Associated With Invasive Aspergillosis Among Acute Exacerbation of Chronic Obstructive Pulmonary Disease Patient Population," *Respiratory Medicine* 191 (2022): 106720.

52. E. E. Tejerina, E. Abril, R. Padilla, et al., "Invasive Aspergillosis in Critically Ill Patients: An Autopsy Study," *Mycoses* 62 (2019): 673–679.

53. J. Chen, Q. Yang, J. Huang, and L. Li, "Risk Factors for Invasive Pulmonary Aspergillosis and Hospital Mortality in Acute-On-Chronic Liver Failure Patients: A Retrospective-Cohort Study," *International Journal of Medical Sciences* 10 (2013): 1625–1631.

54. J. Klein, J. Rello, G. Dimopoulos, et al., "Invasive Pulmonary Aspergillosis in Solid-Organ Transplant Patients in the Intensive Care Unit," *Transplant Infectious Disease* 24 (2022): e13746.

55. B. Denis, M. Guiguet, N. de Castro, et al., "Relevance of EORTC Criteria for the Diagnosis of Invasive Aspergillosis in HIV-Infected Patients, and Survival Trends Over a 20-Year Period in France," *Clinical Infectious Diseases* 61 (2015): 1273–1280.

56. O. Lortholary, M. C. Meyohas, B. Dupont, et al., "Invasive Aspergillosis in Patients With Acquired Immunodeficiency Syndrome: Report of 33 Cases. French Cooperative Study Group on Aspergillosis in AIDS," *American Journal of Medicine* 95 (1993): 177–187.

57. J. Gavalda, O. Len, R. San Juan, et al., "Risk Factors for Invasive Aspergillosis in Solid-Organ Transplant Recipients: A Case-Control Study," *Clinical Infectious Diseases* 41 (2005): 52–59.

58. C. S. Durga, N. Gupta, M. Soneja, et al., "Invasive Fungal Infections in Critically Ill Patients: A Prospective Study From a Tertiary Care Hospital in India," *Drug Discoveries & Therapeutics* 12 (2018): 363–367.

59. J. Garnacho-Montero, R. Amaya-Villar, C. Ortiz-Leyba, et al., "Isolation of Aspergillus spp. From the Respiratory Tract in Critically Ill Patients: Risk Factors, Clinical Presentation and Outcome," *Critical Care* 9 (2005): R191–R199.

60. N. Massart, E. Plainfosse, Y. Benameur, et al., "Prediction of Pulmonary Aspergillosis in Patients With Ventilator-Associated Pneumonia," *Annals of Intensive Care* 13 (2023): 109.

61. I. Rodriguez-Goncer, S. Thomas, P. Foden, et al., "Invasive Pulmonary Aspergillosis Is Associated With Adverse Clinical Outcomes in Critically Ill Patients Receiving Veno-Venous Extracorporeal Membrane Oxygenation," *European Journal of Clinical Microbiology & Infectious Diseases* 37 (2018): 1251–1257.

62. Y. Liu, Z. Zhang, L. Zhou, et al., "Invasive Aspergillosis in Critically Ill Patients With Diabetes Mellitus: A Systematic Review and Meta-Analysis," *BMC Infectious Diseases* 25 (2025): 141.

63. C. W. Kuo, S. Y. Wang, H. P. Tsai, et al., "Invasive Pulmonary Aspergillosis Is Associated With Cytomegalovirus Viremia in Critically Ill Patients – A Retrospective Cohort Study," *Journal of Microbiology, Immunology, and Infection* 55 (2022): 291–299.

64. J. Barberan, F. Sanz, J. L. Hernandez, et al., "Clinical Features of Invasive Pulmonary Aspergillosis vs. Colonization in COPD Patients Distributed by Gold Stage," *Journal of Infection* 65 (2012): 447–452.

65. H. Xu, L. Li, W. J. Huang, L. X. Wang, W. F. Li, and W. F. Yuan, "Invasive Pulmonary Aspergillosis in Patients With Chronic Obstructive Pulmonary Disease: A Case Control Study From China," *Clinical Microbiology and Infection* 18 (2012): 403–408.

66. F. S. Taccone, A. M. Van den Abeele, P. Bulpa, et al., "Epidemiology of Invasive Aspergillosis in Critically Ill Patients: Clinical Presentation, Underlying Conditions, and Outcomes," *Critical Care* 19 (2015): 7.

67. L. Vanderbeke, N. A. F. Janssen, D. Bergmans, et al., "Posaconazole for Prevention of Invasive Pulmonary Aspergillosis in Critically Ill Influenza Patients (POSA-FLU): A Randomised, Open-Label, Proof-Of-Concept Trial," *Intensive Care Medicine* 47 (2021): 674–686.

68. L. Vanderbeke, I. Spriet, C. Breynaert, B. J. A. Rijnders, P. E. Verweij, and J. Wauters, "Invasive Pulmonary Aspergillosis Complicating Severe Influenza: Epidemiology, Diagnosis and Treatment," *Current Opinion in Infectious Diseases* 31 (2018): 471–480.

69. L. Claverias, X. Daniel, I. Martin-Loeches, et al., "Impact of Aspergillus spp. Isolation in the First 24 Hours of Admission in Critically Ill Patients With Severe Influenza Virus Pneumonia," *Med Intensiva (Engl Ed)* 46 (2022): 426–435.

70. A. Coste, A. Frerou, A. Raute, et al., "The Extent of Aspergillosis in Critically Ill Patients With Severe Influenza Pneumonia: A Multicenter Cohort Study," *Critical Care Medicine* 49 (2021): 934–942.

71. L. Huang, N. Zhang, X. Huang, et al., "Invasive Pulmonary Aspergillosis in Patients With Influenza Infection: A Retrospective Study and Review of the Literature," *Clinical Respiratory Journal* 13 (2019): 202–211.

72. W. C. Lee, C. C. Chang, M. C. Ho, et al., "Invasive Pulmonary Aspergillosis Among Patients With Severe Community-Acquired Pneumonia and Influenza in ICUs: A Retrospective Cohort Study," *Pneumonia (Nathan)* 16 (2024): 10.

73. J. Wauters, I. Baar, P. Meersseman, et al., "Invasive Pulmonary Aspergillosis Is a Frequent Complication of Critically Ill H1N1 Patients: A Retrospective Study," *Intensive Care Medicine* 38 (2012): 1761–1768.

74. M. Bartoletti, R. Pascale, M. Cricca, et al., "Epidemiology of Invasive Pulmonary Aspergillosis Among Intubated Patients With COVID-19: A Prospective Study," *Clinical Infectious Diseases* 73 (2021): e3606.

75. P. Chauvet, J. Mallat, C. Arumadura, et al., "Risk Factors for Invasive Pulmonary Aspergillosis in Critically Ill Patients With Coronavirus Disease 2019-Induced Acute Respiratory Distress Syndrome," *Critical Care Explorations* 2 (2020): e0244.

76. W. H. Chong, B. K. Saha, and K. P. Neu, "Comparing the Clinical Characteristics and Outcomes of COVID-19-Associate Pulmonary Aspergillosis (CAPA): A Systematic Review and Meta-Analysis," *Infection* 50 (2022): 43–56.

77. N. A. F. Janssen, R. Nyga, L. Vanderbeke, et al., "Multinational Observational Cohort Study of COVID-19-Associated Pulmonary Aspergillosis(1)," *Emerging Infectious Diseases* 27 (2021): 2892–2898.

78. N. Permpalung, T. P. Chiang, A. B. Massie, et al., "Coronavirus Disease 2019-Associated Pulmonary Aspergillosis in Mechanically Ventilated Patients," *Clinical Infectious Diseases* 74 (2022): 83–91.

79. P. L. White, R. Dhillon, A. Cordey, et al., "A National Strategy to Diagnose Coronavirus Disease 2019-Associated Invasive Fungal Disease in the Intensive Care Unit," *Clinical Infectious Diseases* 73 (2021): e1634–e1644.

80. Z. Hashim, A. Nath, A. Khan, et al., "Effect of Glucocorticoids on the Development of COVID-19-Associated Pulmonary Aspergillosis: A Meta-Analysis of 21 Studies and 5174 Patients," *Mycoses* 66 (2023): 941–952.

81. S. Delliere, E. Dudoignon, S. Fodil, et al., "Risk Factors Associated With COVID-19-Associated Pulmonary Aspergillosis in ICU Patients: A French Multicentric Retrospective Cohort," *Clinical Microbiology and Infection* 27, no. 790 (2020): e1–e5.

82. T. Lahmer, S. Kriescher, A. Herner, et al., "Invasive Pulmonary Aspergillosis in Critically Ill Patients With Severe COVID-19 Pneumonia: Results From the Prospective Asp COVID-19 Study," *PLoS One* 16 (2021): e0238825.

83. J. D. Jenks, S. R. Mehta, R. Taplitz, S. Aslam, S. L. Reed, and M. Hoenigl, "Point-Of-Care Diagnosis of Invasive Aspergillosis in Non-Neutropenic Patients: Aspergillus Galactomannan Lateral Flow Assay Versus Aspergillus-Specific Lateral Flow Device Test in Bronchoalveolar Lavage," *Mycoses* 62 (2019): 230–236.

84. J. D. Jenks, J. Prattes, J. Frank, et al., "Performance of the Bronchoalveolar Lavage Fluid Aspergillus Galactomannan Lateral Flow Assay With Cube Reader for Diagnosis of Invasive Pulmonary Aspergillosis: A Multicenter Cohort Study," *Clinical Infectious Diseases* 73 (2021): e1737–e1744.

85. U. Scharmann, H. L. Verhasselt, L. Kirchhoff, et al., "Evaluation of Two Lateral Flow Assays in BAL Fluids for the Detection of Invasive Pulmonary Aspergillosis: A Retrospective Two-Centre Study," *Mycoses* 63 (2020): 1362–1367.

86. T. Mercier, E. Guldentops, K. Lagrou, and J. Maertens, "Prospective Evaluation of the Turbidimetric Beta-D-Glucan Assay and 2 Lateral Flow Assays on Serum in Invasive Aspergillosis," *Clinical Infectious Diseases* 72 (2021): 1577–1584.

87. F. Lamoth, M. Cruciani, C. Mengoli, et al., "Beta-Glucan Antigenemia Assay for the Diagnosis of Invasive Fungal Infections in Patients With Hematological Malignancies: A Systematic Review and Meta-Analysis of Cohort Studies From the Third European Conference on Infections in Leukemia (ECIL-3)," *Clinical Infectious Diseases* 54 (2012): 633–643.

88. C. Mengoli, M. Cruciani, R. A. Barnes, J. Loeffler, and J. P. Donnelly, "Use of PCR for Diagnosis of Invasive Aspergillosis: Systematic Review and Meta-Analysis," *Lancet Infectious Diseases* 9 (2009): 89–96.

89. C. D. Pfeiffer, J. P. Fine, and N. Safdar, "Diagnosis of Invasive Aspergillosis Using a Galactomannan Assay: A Meta-Analysis," *Clinical Infectious Diseases* 42 (2006): 1417–1427.

90. A. M. Borman, M. D. Palmer, M. Fraser, et al., "COVID-19-Associated Invasive Aspergillosis: Data From the UK National Mycology Reference Laboratory," *Journal of Clinical Microbiology* 59 (2020): e02136-20.

91. J. Prattes, J. Wauters, D. R. Giacobbe, K. Lagrou, and M. Hoenigl, "Diagnosis and Treatment of COVID-19 Associated Pulmonary Apergillosis in Critically Ill Patients: Results From a European Confederation of Medical Mycology Registry," *Intensive Care Medicine* 47 (2021): 1158–1160.

92. C. Guervilly, A. Roch, S. Ranque, et al., "A Strategy Based on Galactomannan Antigen Detection and PCR for Invasive Pulmonary Aspergillosis Following Influenza A (H1N1) Pneumonia," *Journal of Infection* 65 (2012): 470–473.

93. K. van de Groep, D. M. Verboom, F. L. van de Veerdonk, et al., "Detection of Invasive Aspergillosis in Critically Ill Patients With Influenza: The Role of Plasma Galactomannan," *American Journal of Respiratory and Critical Care Medicine* 200 (2019): 636–638.

94. J. Acosta, M. Catalan, A. del Palacio-Perez-Medel, et al., "A Prospective Comparison of Galactomannan in Bronchoalveolar Lavage Fluid for the Diagnosis of Pulmonary Invasive Aspergillosis in Medical Patients Under Intensive Care: Comparison With the Diagnostic Performance of Galactomannan and of (1–> 3)-Beta-d-Glucan Chromogenic Assay in Serum Samples," *Clinical Microbiology and Infection* 17 (2011): 1053–1060.

95. T. Lahmer, M. Neuenhahn, J. Held, S. Rasch, R. M. Schmid, and W. Huber, "Comparison of 1,3-Beta-d-Glucan With Galactomannan in Serum and Bronchoalveolar Fluid for the Detection of Aspergillus Species in Immunosuppressed Mechanical Ventilated Critically Ill Patients," *Journal of Critical Care* 36 (2016): 259–264.

96. L. Loughlin, T. P. Hellyer, P. L. White, et al., "Pulmonary Aspergillosis in Patients With Suspected Ventilator-Associated Pneumonia in UK ICUs," *American Journal of Respiratory and Critical Care Medicine* 202 (2020): 1125–1132.

97. W. Meersseman, K. Lagrou, J. Maertens, et al., "Galactomannan in Bronchoalveolar Lavage Fluid: A Tool for Diagnosing Aspergillosis in Intensive Care Unit Patients," *American Journal of Respiratory and Critical Care Medicine* 177 (2008): 27–34.

98. Y. Yu, C. Zhu, H. Shen, et al., "Galactomannan Detection in Bronchoalveolar Lavage Fluid Corrected by Urea Dilution for the Diagnosis of Invasive Pulmonary Aspergillosis Among Nonneutropenic Patients," *Journal of Thoracic Disease* 11 (2019): 465–476.

99. S. Delliere, E. Dudoignon, S. Voicu, et al., "Combination of Mycological Criteria: A Better Surrogate to Identify COVID-19-Associated Pulmonary Aspergillosis Patients and Evaluate Prognosis?," *Journal of Clinical Microbiology* 60 (2022): e0216921.

100. M. Egger, F. Pruller, R. Krause, J. Prattes, and M. Hoenigl, "Utility of Serum 1,3-Beta-d-Glucan Testing for Diagnosis and Prognostication in COVID-19-Associated Pulmonary Aspergillosis," *Microbiology Spectrum* 10 (2022): e0137322.

101. M. Ergun, R. J. M. Bruggemann, A. Alanio, et al., "Aspergillus Test Profiles and Mortality in Critically Ill COVID-19 Patients," *Journal of Clinical Microbiology* 59 (2021): e0122921.

102. P. Pavone, G. Russello, G. Salati, et al., "Active Screening of COVID-19-Associated Pulmonary Aspergillosis With Serum Beta-Glucan and Endotracheal Aspirates Galactomannan and Fungal Culture," *Mycoses* 66 (2023): 219–225.

103. C. M. Roman-Montes, S. Bojorges-Aguilar, P. Diaz-Lomeli, et al., "Tracheal Aspirate Galactomannan Testing in COVID-19-Associated Pulmonary Aspergillosis," *Frontiers in Fungal Biology* 3 (2022): 855914.

104. C. M. Roman-Montes, A. Martinez-Gamboa, P. Diaz-Lomeli, et al., "Accuracy of Galactomannan Testing on Tracheal Aspirates in COVID-19-Associated Pulmonary Aspergillosis," *Mycoses* 64 (2021): 364–371.

105. S. van Biesen, D. Kwa, R. J. Bosman, and N. P. Juffermans, "Detection of Invasive Pulmonary Aspergillosis in COVID-19 With Nondirected BAL," *American Journal of Respiratory and Critical Care Medicine* 202 (2020): 1171–1173.

106. B. D. Alexander, F. Lamoth, C. P. Heussel, et al., "Guidance on Imaging for Invasive Pulmonary Aspergillosis and Mucormycosis: From the Imaging Working Group for the Revision and Update of the Consensus Definitions of Fungal Disease From the EORTC/MSGERC," *Clinical Infectious Diseases* 72 (2021): S79–S88.

107. E. Baratella, E. Roman-Pognuz, V. Zerbato, et al., "Potential Links Between COVID-19-Associated Pulmonary Aspergillosis and Bronchiectasis as Detected by High Resolution Computed Tomography," *Front Biosci (Landmark Ed)* 26 (2021): 1607–1612.

108. N. Brandi, F. Ciccarese, C. Balacchi, et al., "Co-Infections and Superinfections in COVID-19 Critically Ill Patients Are Associated With CT Imaging Abnormalities and the Worst Outcomes," *Diagnostics (Basel)* 12 (2022): 1617.

109. T. Fischer, Y. el Baz, N. Graf, et al., "Clinical and Imaging Features of COVID-19-Associated Pulmonary Aspergillosis," *Diagnostics (Basel)* 12 (2022): 1201.

110. W. Hong, P. L. White, M. Backx, et al., "CT Findings of COVID-19-Associated Pulmonary Aspergillosis: A Systematic Review and Individual Patient Data Analysis," *Clinical Imaging* 90 (2022): 11–18.

111. F. Reizine, K. Pinceaux, M. Lederlin, et al., "Influenza and COVID-19-Associated Pulmonary Aspergillosis: Are the Pictures Different?," *J Fungi (Basel)* 7 (2021): 388.

112. F. Lamoth, "Invasive Aspergillosis in Coronavirus Disease 2019: A Practical Approach for Clinicians," *Current Opinion in Infectious Diseases* 35 (2022): 163–169.

113. A. Estella, I. Martin-Loeches, M. R. Nunez, et al., "Microbiological Diagnosis of Pulmonary Invasive Aspergillosis in Critically Ill Patients With Severe SARS-CoV-2 Pneumonia: A Bronchoalveolar Study," *Annals of Clinical Microbiology and Antimicrobials* 22 (2023): 90.

114. R. Nyga, J. Maizel, S. Nseir, et al., "Invasive Tracheobronchial Aspergillosis in Critically Ill Patients With Severe Influenza. A Clinical Trial," *American Journal of Respiratory and Critical Care Medicine* 202 (2020): 708–716.

115. M. Bassetti, V. Zuccaro, E. Asperges, L. Scudeller, and D. R. Giacobbe, "Performance of Existing Definitions and Tests for the Diagnosis of Invasive Aspergillosis in Critically Ill, Non-Neutropenic, Adult Patients: An Update Including COVID-19 Data," *Journal of Infection* 85 (2022): 573–607.

116. M. Mikulska, E. Furfaro, S. Dettori, et al., "Aspergillus-PCR in Bronchoalveolar Lavage - Diagnostic Accuracy for Invasive Pulmonary Aspergillosis in Critically Ill Patients," *Mycoses* 65 (2022): 411–418.

117. J. P. Donnelly, S. C. Chen, C. A. Kauffman, et al., "Revision and Update of the Consensus Definitions of Invasive Fungal Disease From the European Organization for Research and Treatment of Cancer and the Mycoses Study Group Education and Research Consortium," *Clinical Infectious Diseases* 71 (2020): 1367–1376.

118. G. Pasquier, A. Bounhiol, F. Robert Gangneux, et al., "A Review of Significance of Aspergillus Detection in Airways of ICU COVID-19 Patients," *Mycoses* 64 (2021): 980–988.

119. D. A. Patel, X. Gao, J. M. Stephens, M. S. Forshag, and M. Tarallo, "US Hospital Database Analysis of Invasive Aspergillosis in the Chronic Obstructive Pulmonary Disease Non-Traditional Host," *Journal of Medical Economics* 14 (2011): 227–237.

120. R. Herbrecht, D. W. Denning, T. F. Patterson, et al., "Voriconazole Versus Amphotericin B for Primary Therapy of Invasive Aspergillosis," *New England Journal of Medicine* 347 (2002): 408–415.

121. G. Dimopoulos, M. P. Almyroudi, P. Myrianthefs, and J. Rello, "COVID-19-Associated Pulmonary Aspergillosis (CAPA)," *Journal of Intensive Medicine* 1 (2021): 71–80.

122. J. A. Maertens, I. I. Raad, K. A. Marr, et al., "Isavuconazole Versus Voriconazole for Primary Treatment of Invasive Mould Disease Caused by Aspergillus and Other Filamentous Fungi (SECURE): A Phase 3, Randomised-Controlled, Non-Inferiority Trial," *Lancet* 387 (2016): 760–769.

123. N. Ullah, C. Sepulcri, and M. Mikulska, "Isavuconazole for COVID-19-Associated Invasive Mold Infections," *Journal of Fungi (Basel, Switzerland)* 8 (2022): 674.

124. O. A. Cornely, J. Maertens, M. Bresnik, et al., "Liposomal Amphotericin B as Initial Therapy for Invasive Mold Infection: A Randomized Trial Comparing a High-Loading Dose Regimen With Standard Dosing (AmBiLoad Trial)," *Clinical Infectious Diseases* 44 (2007): 1289–1297.

125. J. A. Maertens, G. Rahav, D. G. Lee, et al., "Posaconazole Versus Voriconazole for Primary Treatment of Invasive Aspergillosis: A Phase 3, Randomised, Controlled, Non-Inferiority Trial," *Lancet* 397 (2021): 499–509.

126. R. Herbrecht, J. Maertens, L. Baila, et al., "Caspofungin First-Line Therapy for Invasive Aspergillosis in Allogeneic Hematopoietic Stem Cell Transplant Patients: An European Organisation for Research and Treatment of Cancer Study," *Bone Marrow Transplantation* 45 (2010): 1227–1233.

127. C. Viscoli, R. Herbrecht, H. Akan, et al., "An EORTC Phase II Study of Caspofungin as First-Line Therapy of Invasive Aspergillosis in Haematological Patients," *Journal of Antimicrobial Chemotherapy* 64 (2009): 1274–1281.

128. K. A. Marr, H. T. Schlamm, R. Herbrecht, et al., "Combination Antifungal Therapy for Invasive Aspergillosis: A Randomized Trial," *Annals of Internal Medicine* 162 (2015): 81–89.

129. P. P. Lestrade, R. G. Bentvelsen, A. Schauwvlieghe, et al., "Voriconazole Resistance and Mortality in Invasive Aspergillosis: A Multicenter Retrospective Cohort Study," *Clinical Infectious Diseases* 68 (2019): 1463–1471.

130. M. R. Hodges, M. Tawadrous, O. A. Cornely, et al., "Fosmanogepix for the Treatment of Invasive Mold Diseases Caused by Aspergillus Species and Rare Molds: A Phase 2, Open-Label Study (AEGIS)," *Clinical Infectious Diseases* (2025): ciaf185.

131. V. Michel, N. Mahlaoui, M. E. Bougnoux, D. Garcia-Hermoso, F. Lanternier, and R. Levy, "Prolonged Remission of Azole-Resistant Lung Aspergillosis With Olorofim, in an Adolescent With X-Linked Chronic Granulomatous Disease," *Journal of Clinical Immunology* 43 (2023): 1170–1172.

132. A. J. Lepak, K. Marchillo, J. VanHecker, and D. R. Andes, "Impact of In Vivo Triazole and Echinocandin Combination Therapy for Invasive Pulmonary Aspergillosis: Enhanced Efficacy Against Cyp51 Mutant Isolates," *Antimicrobial Agents and Chemotherapy* 57 (2013): 5438–5447.

133. A. Schauwvlieghe, J. B. Buil, P. E. Verweij, et al., "High-Dose Posaconazole for Azole-Resistant Aspergillosis and Other Difficult-To-Treat Mould Infections," *Mycoses* 63 (2020): 122–130.

134. I. I. Raad, H. A. Hanna, M. Boktour, et al., "Novel Antifungal Agents as Salvage Therapy for Invasive Aspergillosis in Patients With Hematologic Malignancies: Posaconazole Compared With High-Dose Lipid Formulations of Amphotericin B Alone or in Combination With Caspofungin," *Leukemia* 22 (2008): 496–503.

135. R. Y. Hachem, M. R. Boktour, H. A. Hanna, et al., "Amphotericin B Lipid Complex Versus Liposomal Amphotericin B Monotherapy for Invasive Aspergillosis in Patients With Hematologic Malignancy," *Cancer* 112 (2008): 1282–1287.

136. T. T. Ng and D. W. Denning, "Liposomal Amphotericin B (AmBisome) Therapy in Invasive Fungal Infections. Evaluation of United Kingdom Compassionate Use Data," *Archives of Internal Medicine* 155 (1995): 1093–1098.

137. T. J. Walsh, I. Raad, T. F. Patterson, et al., "Treatment of Invasive Aspergillosis With Posaconazole in Patients Who Are Refractory to or Intolerant of Conventional Therapy: An Externally Controlled Trial," *Clinical Infectious Diseases* 44 (2007): 2–12.

138. D. Neofytos, A. Pagliuca, K. Houghton, et al., "Effectiveness, Safety, and Patterns of Real-World Isavuconazole Use in Europe (2015-2019)," *Infectious Disease and Therapy* 13 (2024): 2527–2543.

139. D. W. Denning, P. Ribaud, N. Milpied, et al., "Efficacy and Safety of Voriconazole in the Treatment of Acute Invasive Aspergillosis," *Clinical Infectious Diseases* 34 (2002): 563–571.

140. J. Fortun, F. Gioia, C. Cardozo, et al., "Posaconazole Salvage Therapy: The Posifi Study," *Mycoses* 62 (2019): 526–533.

141. J. H. Kim, R. J. Benefield, and K. Ditolla, "Utilization of Posaconazole Oral Suspension or Delayed-Released Tablet Salvage Treatment for Invasive Fungal Infection," *Mycoses* 59 (2016): 726–733.

142. J. R. Perfect, K. A. Marr, T. J. Walsh, et al., "Voriconazole Treatment for Less-Common, Emerging, or Refractory Fungal Infections," *Clinical Infectious Diseases* 36 (2003): 1122–1131.

143. I. I. Raad, A. E. Zakhem, G. E. Helou, Y. Jiang, D. P. Kontoyiannis, and R. Hachem, "Clinical Experience of the Use of Voriconazole, Caspofungin or the Combination in Primary and Salvage Therapy of Invasive Aspergillosis in Haematological Malignancies," *International Journal of Antimicrobial Agents* 45 (2015): 283–288.

144. J. Maertens, A. Glasmacher, R. Herbrecht, et al., "Multicenter, Noncomparative Study of Caspofungin in Combination With Other Antifungals as Salvage Therapy in Adults With Invasive Aspergillosis," *Cancer* 107 (2006): 2888–2897.

145. K. A. Marr, M. Boeckh, R. A. Carter, H. W. Kim, and L. Corey, "Combination Antifungal Therapy for Invasive Aspergillosis," *Clinical Infectious Diseases* 39 (2004): 797–802.

146. A. A. Panackal, E. Parisini, and M. Proschan, "Salvage Combination Antifungal Therapy for Acute Invasive Aspergillosis May Improve Outcomes: A Systematic Review and Meta-Analysis," *International Journal of Infectious Diseases* 28 (2014): 80–94.

147. A. Candoni, M. Caira, S. Cesaro, et al., "Multicentre Surveillance Study on Feasibility, Safety and Efficacy of Antifungal Combination Therapy for Proven or Probable Invasive Fungal Diseases in Haematological Patients: The SEIFEM Real-Life Combo Study," *Mycoses* 57 (2014): 342–350.

148. H. Lellek, D. Waldenmaier, J. Dahlke, et al., "Caspofungin Plus Posaconazole as Salvage Therapy of Invasive Fungal Infections in Immunocompromised Patients," *Mycoses* 54, no. Suppl 1 (2011): 39–44.

149. C. N. Mihu, C. Kassis, E. R. Ramos, Y. Jiang, R. Y. Hachem, and I. I. Raad, "Does Combination of Lipid Formulation of Amphotericin B and Echinocandins Improve Outcome of Invasive Aspergillosis in Hematological Malignancy Patients?," *Cancer* 116 (2010): 5290–5296.

150. T. B. Aliff, P. G. Maslak, J. G. Jurcic, et al., "Refractory Aspergillus Pneumonia in Patients With Acute Leukemia: Successful Therapy With

Combination Caspofungin and Liposomal Amphotericin," *Cancer* 97 (2003): 1025–1032.

151. D. W. Denning, K. A. Marr, W. M. Lau, et al., "Micafungin (FK463), Alone or in Combination With Other Systemic Antifungal Agents, for the Treatment of Acute Invasive Aspergillosis," *Journal of Infection* 53 (2006): 337–349.

152. D. P. Kontoyiannis, R. Hachem, R. E. Lewis, et al., "Efficacy and Toxicity of Caspofungin in Combination With Liposomal Amphotericin B as Primary or Salvage Treatment of Invasive Aspergillosis in Patients With Hematologic Malignancies," *Cancer* 98 (2003): 292–299.

153. W. J. Heinz, G. Egerer, H. Lellek, A. Boehme, and J. Greiner, "Posaconazole After Previous Antifungal Therapy With Voriconazole for Therapy of Invasive Aspergillus Disease, a Retrospective Analysis," *Mycoses* 56 (2013): 304–310.

154. W. J. Heinz, D. Buchheidt, and A. J. Ullmann, "Clinical Evidence for Caspofungin Monotherapy in the First-Line and Salvage Therapy of Invasive Aspergillus Infections," *Mycoses* 59 (2016): 480–493.

155. J. Maertens, I. Raad, G. Petrikkos, et al., "Efficacy and Safety of Caspofungin for Treatment of Invasive Aspergillosis in Patients Refractory to or Intolerant of Conventional Antifungal Therapy," *Clinical Infectious Diseases* 39 (2004): 1563–1571.

156. J. W. Hiemenz, I. I. Raad, J. A. Maertens, et al., "Efficacy of Caspofungin as Salvage Therapy for Invasive Aspergillosis Compared to Standard Therapy in a Historical Cohort," *European Journal of Clinical Microbiology & Infectious Diseases* 29 (2010): 1387–1394.

157. N. A. Kartsonis, A. J. Saah, C. Joy Lipka, A. F. Taylor, and C. A. Sable, "Salvage Therapy With Caspofungin for Invasive Aspergillosis: Results From the Caspofungin Compassionate Use Study," *Journal of Infection* 50 (2005): 196–205.

158. R. J. Boots, D. L. Paterson, A. M. Allworth, and J. L. Faoagali, "Successful Treatment of Post-Influenza Pseudomembranous Necrotising Bronchial Aspergillosis With Liposomal Amphotericin, Inhaled Amphotericin B, Gamma Interferon and GM-CSF," *Thorax* 54 (1999): 1047–1049.

159. H. Trujillo, M. Fernandez-Ruiz, E. Gutierrez, et al., "Invasive Pulmonary Aspergillosis Associated With COVID-19 in a Kidney Transplant Recipient," *Transplant Infectious Disease* 23 (2021): e13501.

160. H. D. Huang, Q. Li, Y. Huang, et al., "Pseudomembranous Necrotizing Tracheobronchial Aspergillosis: An Analysis of 16 Cases," *Chinese Medical Journal* 125 (2012): 1236–1241.

161. S. N. Khan, R. Manur, J. S. Brooks, M. A. Husson, K. Leahy, and M. Grant, "Invasive Pseudomembranous Upper Airway and Tracheal Aspergillosis Refractory to Systemic Antifungal Therapy and Serial Surgical Debridement in an Immunocompetent Patient," *BMC Infectious Diseases* 20 (2020): 13.

162. K. S. Metin, B. S. Ugurlu, B. Kabakci, N. O. Sariosmanoglu, E. Hazan, and O. Oto, "Surgical Resection for Successful Treatment of Invasive Pulmonary Aspergillosis: Report of 3 Cases," *Scandinavian Journal of Infectious Diseases* 37 (2005): 694–696.

163. V. Gustainyte, E. Yan, M. Al-Roubaie, and H. Kocharyan, "Interventional Management of Aspergillus-Related Pulmonary Artery Pseudoaneurysm and Hemoptysis," *Radiology Case Reports* 19 (2024): 6318–6322.

164. A. Bandera, D. Trabattoni, G. Ferrario, et al., "Interferon-Gamma and Granulocyte-Macrophage Colony Stimulating Factor Therapy in Three Patients With Pulmonary Aspergillosis," *Infection* 36 (2008): 368–373.

165. C. E. Delsing, M. S. Gresnigt, J. Leentjens, et al., "Interferon-Gamma as Adjunctive Immunotherapy for Invasive Fungal Infections: A Case Series," *BMC Infectious Diseases* 14 (2014): 166.

166. J. Calderon-Parra, P. Mills-Sanchez, V. Moreno-Torres, et al., "COVID-19-Associated Pulmonary Aspergillosis (CAPA): Risk Factors and Development of a Predictive Score for Critically Ill COVID-19 Patients," *Mycoses* 65 (2022): 541–550.

167. N. Carbonell, M. J. Alcaraz, A. Serrano-Lazaro, et al., "CAPA in Progress: A New Real-Life Approach for the Management of Critically Ill COVID-19 Patients," *Biomedicine* 10 (2022): 1683.

168. F. Tissot, S. Agrawal, L. Pagano, et al., "ECIL-6 Guidelines for the Treatment of Invasive Candidiasis, Aspergillosis and Mucormycosis in Leukemia and Hematopoietic Stem Cell Transplant Patients," *Haematologica* 102 (2017): 433–444.

169. J. P. Botero Aguirre and A. M. Restrepo Hamid, "Amphotericin B Deoxycholate Versus Liposomal Amphotericin B: Effects on Kidney Function," *Cochrane Database of Systematic Reviews* 2015 (2015): CD010481.

170. H. K. Johansen and P. C. Gotzsche, "Amphotericin B Lipid Soluble Formulations Versus Amphotericin B in Cancer Patients With Neutropenia," *Cochrane Database of Systematic Reviews* 2014 (2014): CD000969.

171. J. R. Wingard, M. H. White, E. Anaissie, et al., "A Randomized, Double-Blind Comparative Trial Evaluating the Safety of Liposomal Amphotericin B Versus Amphotericin B Lipid Complex in the Empirical Treatment of Febrile Neutropenia. L Amph/ABLC Collaborative Study Group," *Clinical Infectious Diseases* 31 (2000): 1155–1163.

172. D. R. Falci, F. B. da Rosa, and A. C. Pasqualotto, "Comparison of Nephrotoxicity Associated to Different Lipid Formulations of Amphotericin B: A Real-Life Study," *Mycoses* 58 (2015): 104–112.

173. R. L. Wade, P. Chaudhari, J. L. Natoli, R. J. Taylor, B. H. Nathanson, and D. L. Horn, "Nephrotoxicity and Other Adverse Events Among Inpatients Receiving Liposomal Amphotericin B or Amphotericin B Lipid Complex," *Diagnostic Microbiology and Infectious Disease* 76 (2013): 361–367.

174. F. Alvarez-Lerma, M. C. Soriano, M. Rodriguez, et al., "Impact of Liposomal Amphotericin B on Renal Function in Critically Ill Patients With Renal Function Impairment," *Revista Española de Quimioterapia* 25 (2012): 206–215.

175. I. Sacanella, E. Esteve-Pitarch, J. Guevara-Chaux, et al., "A Real-World Data Observational Analysis of the Impact of Liposomal Amphotericin B on Renal Function Using Machine Learning in Critically Ill Patients," *Antibiotics (Basel)* 13 (2024): 760.

176. M. Aruanno, E. Glampedakis, and F. Lamoth, "Echinocandins for the Treatment of Invasive Aspergillosis: From Laboratory to Bedside," *Antimicrobial Agents and Chemotherapy* 63 (2019): e00399-19.

177. S. Ragozzino, D. Goldenberger, P. R. Wright, et al., "Distribution of Aspergillus Species and Prevalence of Azole Resistance in Respiratory Samples From Swiss Tertiary Care Hospitals," *Open Forum Infectious Diseases* 9 (2022): ofab638.

178. S. Schurch, K. Gindro, S. Schnee, et al., "Occurrence of *Aspergillus fumigatus* Azole Resistance in Soils From Switzerland," *Medical Mycology* 61 (2023): myad110.

179. P. E. Verweij, M. Ananda-Rajah, D. Andes, et al., "International Expert Opinion on the Management of Infection Caused by Azole-Resistant *Aspergillus fumigatus*," *Drug Resistance Updates* 21 (2015): 30–40.

180. C. Cordonnier, M. Bresnik, and R. Ebrahimi, "Liposomal Amphotericin B (AmBisome) Efficacy in Confirmed Invasive Aspergillosis and Other Filamentous Fungal Infections in Immunocompromised Hosts: A Pooled Analysis," *Mycoses* 50 (2007): 205–209.

181. K. C. van der Elst, A. Veringa, J. G. Zijlstra, et al., "Low Caspofungin Exposure in Patients in Intensive Care Units," *Antimicrobial Agents and Chemotherapy* 61 (2017): e01582-16.

182. M. Melchers, B. Festen, B. M. den Dekker, et al., "A 67-Year-Old Male Patient With COVID-19 With Worsening Respiratory Function and Acute Kidney Failure," *Chest* 161 (2022): e5–e11.

183. J. Fortun, E. Gomez-Garcia de la Pedrosa, A. Martinez-Lorca, et al., "A Phase I/IIa Prospective, Randomized, Open-Label Study on the Safety and Efficacy of Nebulized Liposomal Amphotericin for Invasive Pulmonary Aspergillosis," *Journal of Fungi (Basel)* 10 (2024): 191.

184. F. L. van de Veerdonk, R. J. M. Bruggemann, S. Vos, et al., "COVID-19-Associated Aspergillus Tracheobronchitis: The Interplay Between Viral Tropism, Host Defence, and Fungal Invasion," *Lancet Respiratory Medicine* 9 (2021): 795–802.

185. Group RC, P. Horby, W. S. Lim, et al., "Dexamethasone in Hospitalized Patients With COVID-19," *New England Journal of Medicine* 384 (2021): 693–704.

186. L. E. Lansbury, C. Rodrigo, J. Leonardi-Bee, J. Nguyen-Van-Tam, and W. Shen Lim, "Corticosteroids as Adjunctive Therapy in the Treatment of Influenza: An Updated Cochrane Systematic Review and Meta-Analysis," *Critical Care Medicine* 48 (2020): e98–e106.

187. S. Gaffney, D. M. Kelly, P. M. Rameli, E. Kelleher, and I. Martin-Loeches, "Invasive Pulmonary Aspergillosis in the Intensive Care Unit: Current Challenges and Best Practices," *APMIS* 131 (2023): 654–667.

188. J. A. Roberts, F. B. Sime, J. Lipman, et al., "Are Contemporary Antifungal Doses Sufficient for Critically Ill Patients? Outcomes From an International, Multicenter Pharmacokinetics Study for Screening Antifungal Exposure in Intensive Care Units-The SAFE-ICU Study," *Intensive Care Medicine* 51 (2025): 302–317.

189. D. R. Luke, K. Tomaszewski, B. Damle, and H. T. Schlamm, "Review of the Basic and Clinical Pharmacology of Sulfobutylether-Beta-Cyclodextrin (SBECD)," *Journal of Pharmaceutical Sciences* 99 (2010): 3291–3301.

190. S. H. Kim, J. C. Kwon, C. Park, et al., "Therapeutic Drug Monitoring and Safety of Intravenous Voriconazole Formulated With Sulfobutylether Beta-Cyclodextrin in Haematological Patients With Renal Impairment," *Mycoses* 59 (2016): 644–651.

191. T. H. Kiser, D. N. Fish, C. L. Aquilante, et al., "Evaluation of Sulfobutylether-Beta-Cyclodextrin (SBECD) Accumulation and Voriconazole Pharmacokinetics in Critically Ill Patients Undergoing Continuous Renal Replacement Therapy," *Critical Care* 19 (2015): 32.

192. A. A. Morris, S. W. Mueller, J. E. Rower, T. Washburn, and T. H. Kiser, "Evaluation of Sulfobutylether-Beta-Cyclodextrin Exposure in a Critically Ill Patient Receiving Intravenous Posaconazole While Undergoing Continuous Venovenous Hemofiltration," *Antimicrobial Agents and Chemotherapy* 59 (2015): 6653–6656.

193. D. Neofytos, L. R. Lombardi, R. K. Shields, et al., "Administration of Voriconazole in Patients With Renal Dysfunction," *Clinical Infectious Diseases* 54 (2012): 913–921.

194. R. B. Turner, J. L. Martello, and A. Malhotra, "Worsening Renal Function in Patients With Baseline Renal Impairment Treated With Intravenous Voriconazole: A Systematic Review," *International Journal of Antimicrobial Agents* 46 (2015): 362–366.

195. T. Wang, M. Yan, D. Tang, et al., "Using Child-Pugh Class to Optimize Voriconazole Dosage Regimens and Improve Safety in Patients With Liver Cirrhosis: Insights From a Population Pharmacokinetic Model-Based Analysis," *Pharmacotherapy* 41 (2021): 172–183.

196. J. Couchepin, I. Reinhold, I. Kronig, et al., "Isavuconazole for the Treatment of Fungal Infections: A Real-Life Experience From the Fungal Infection Network of Switzerland (FUNGINOS)," *Open Forum Infectious Diseases* 11 (2024): ofae223.

197. A. J. DiPippo, C. R. Rausch, and D. P. Kontoyiannis, "Tolerability of Isavuconazole After Posaconazole Toxicity in Leukaemia Patients," *Mycoses* 62 (2019): 81–86.

198. I. Kronig, S. Masouridi-Levrat, Y. Chalandon, et al., "Clinical Considerations of Isavuconazole Administration in High-Risk Hematological Patients: A Single-Center 5-Year Experience," *Mycopathologia* 186 (2021): 775–788.

199. A. Desai, A. H. Schmitt-Hoffmann, S. Mujais, and R. Townsend, "Population Pharmacokinetics of Isavuconazole in Subjects With Mild or Moderate Hepatic Impairment," *Antimicrobial Agents and Chemotherapy* 60 (2016): 3025–3031.

200. A. Schmitt-Hoffmann, B. Roos, J. Spickermann, et al., "Effect of Mild and Moderate Liver Disease on the Pharmacokinetics of Isavuconazole After Intravenous and Oral Administration of a Single Dose of the Prodrug BAL8557," *Antimicrobial Agents and Chemotherapy* 53 (2009): 4885–4890.

201. T. Gustot, R. ter Heine, E. Brauns, F. Cotton, F. Jacobs, and R. J. Bruggemann, "Caspofungin Dosage Adjustments Are Not Required for Patients With Child-Pugh B or C Cirrhosis," *Journal of Antimicrobial Chemotherapy* 73 (2018): 2493–2496.

202. G. C. Mistry, E. Migoya, P. J. Deutsch, et al., "Single- and Multiple-Dose Administration of Caspofungin in Patients With Hepatic Insufficiency: Implications for Safety and Dosing Recommendations," *Journal of Clinical Pharmacology* 47 (2007): 951–961.

203. L. Kriegl, S. Hatzl, G. Schilcher, et al., "Antifungals in Patients With Extracorporeal Membrane Oxygenation: Clinical Implications," *Open Forum Infectious Diseases* 11 (2024): ofae270.

204. L. Kriegl, S. Hatzl, C. Zurl, et al., "Isavuconazole Plasma Concentrations in Critically Ill Patients During Extracorporeal Membrane Oxygenation," *Journal of Antimicrobial Chemotherapy* 77 (2022): 2500–2505.

205. H. Lyster, K. Shekar, K. Watt, A. Reed, J. A. Roberts, and M. H. Abdul-Aziz, "Antifungal Dosing in Critically Ill Patients on Extracorporeal Membrane Oxygenation," *Clinical Pharmacokinetics* 62 (2023): 931–942.

206. R. van Daele, B. Bekkers, M. Lindfors, et al., "A Large Retrospective Assessment of Voriconazole Exposure in Patients Treated With Extracorporeal Membrane Oxygenation," *Microorganisms* 9 (2021): 1543.

207. R. van Daele, R. J. Bruggemann, E. Dreesen, et al., "Pharmacokinetics and Target Attainment of Intravenous Posaconazole in Critically Ill Patients During Extracorporeal Membrane Oxygenation," *Journal of Antimicrobial Chemotherapy* 76 (2021): 1234–1241.

208. G. Aguilar, R. Ferriols, J. A. Carbonell, et al., "Pharmacokinetics of Anidulafungin During Venovenous Extracorporeal Membrane Oxygenation," *Critical Care* 20 (2016): 325.

209. Q. Wang, Z. Zhang, D. Liu, et al., "Population Pharmacokinetics of Caspofungin Among Extracorporeal Membrane Oxygenation Patients During the Postoperative Period of Lung Transplantation," *Antimicrobial Agents and Chemotherapy* 64 (2020): e00687-20.

210. A. Desai, M. Helmick, N. Heo, et al., "Pharmacokinetics and Bioequivalence of Isavuconazole Administered as Isavuconazonium Sulfate Intravenous Solution via Nasogastric Tube or Orally in Healthy Subjects," *Antimicrobial Agents and Chemotherapy* 65 (2021): e0044221.

211. S. Grau, A. J. Mateu-De, F. Alvarez-Lerma, M. Marin-Casino, and J. M. Torres-Rodriguez, "Successful Treatment of an *Aspergillus fumigatus* Infection With Voriconazole via a Nasogastric Tube," *Journal of Chemotherapy* 18 (2006): 445–446.

212. A. Manesh, E. Devasagayam, K. Bhanuprasad, et al., "Efficacy of Crushed Delayed-Release Posaconazole Tablets in Rhino-Orbito-Cerebral Mucormycosis," *Antimicrobial Agents and Chemotherapy* 66 (2022): e0108522.

213. E. K. McCreary, M. H. Nguyen, M. R. Davis, et al., "Achievement of Clinical Isavuconazole Blood Concentrations in Transplant Recipients With Isavuconazonium Sulphate Capsules Administered via Enteral

Feeding Tube," *Journal of Antimicrobial Chemotherapy* 75 (2020): 3023–3028.

214. I. Mohammedi, M. A. Piens, C. Padoin, and D. Robert, "Plasma Levels of Voriconazole Administered via a Nasogastric Tube to Critically Ill Patients," *European Journal of Clinical Microbiology & Infectious Diseases* 24 (2005): 358–360.

215. P. S. Prayag, S. P. Panchakshari, N. P. Mahalle, et al., "Factors Associated With Subtherapeutic Levels of Oral Posaconazole Tablet: A Detailed Analysis From a Tertiary Care Center in India," *International Journal of Infectious Diseases* 124 (2022): 76–80.

216. K. D. Payne and R. G. Hall, "Dosing of Antifungal Agents in Obese People," *Expert Review of Anti-Infective Therapy* 14 (2016): 257–267.

217. R. E. Wasmann, C. Smit, E. P. H. van Dongen, et al., "Fixed Dosing of Liposomal Amphotericin B in Morbidly Obese Individuals," *Clinical Infectious Diseases* 70 (2020): 2213–2215.

218. R. E. Wasmann, C. Smit, M. H. van Donselaar, et al., "Implications for IV Posaconazole Dosing in the Era of Obesity," *Journal of Antimicrobial Chemotherapy* 75 (2020): 1006–1013.

219. R. G. Hall, S. Liu, W. C. Putnam, R. Kallem, T. Gumbo, and M. P. Pai, "Optimizing Anidulafungin Exposure Across a Wide Adult Body Size Range," *Antimicrobial Agents and Chemotherapy* 67 (2023): e0082023.

220. A. G. Martson, K. C. M. van der Elst, A. Veringa, et al., "Caspofungin Weight-Based Dosing Supported by a Population Pharmacokinetic Model in Critically Ill Patients," *Antimicrobial Agents and Chemotherapy* 64 (2020): e00905.

221. R. E. Wasmann, R. ter Heine, E. P. van Dongen, et al., "Pharmacokinetics of Anidulafungin in Obese and Normal-Weight Adults," *Antimicrobial Agents and Chemotherapy* 62 (2018): e00063.

222. M. J. Dolton, J. E. Ray, S. C. Chen, K. Ng, L. G. Pont, and A. J. McLachlan, "Multicenter Study of Voriconazole Pharmacokinetics and Therapeutic Drug Monitoring," *Antimicrobial Agents and Chemotherapy* 56 (2012): 4793–4799.

223. A. Pascual, T. Calandra, S. Bolay, T. Buclin, J. Bille, and O. Marchetti, "Voriconazole Therapeutic Drug Monitoring in Patients With Invasive Mycoses Improves Efficacy and Safety Outcomes," *Clinical Infectious Diseases* 46 (2008): 201–211.

224. A. Pascual, C. Csajka, T. Buclin, et al., "Challenging Recommended Oral and Intravenous Voriconazole Doses for Improved Efficacy and Safety: Population Pharmacokinetics-Based Analysis of Adult Patients With Invasive Fungal Infections," *Clinical Infectious Diseases* 55 (2012): 381–390.

225. P. F. Troke, H. P. Hockey, and W. W. Hope, "Observational Study of the Clinical Efficacy of Voriconazole and Its Relationship to Plasma Concentrations in Patients," *Antimicrobial Agents and Chemotherapy* 55 (2011): 4782–4788.

226. O. A. Cornely, R. F. Duarte, S. Haider, et al., "Phase 3 Pharmacokinetics and Safety Study of a Posaconazole Tablet Formulation in Patients at Risk for Invasive Fungal Disease," *Journal of Antimicrobial Chemotherapy* 71 (2016): 1747.

227. O. A. Cornely, M. N. Robertson, S. Haider, et al., "Pharmacokinetics and Safety Results From the Phase 3 Randomized, Open-Label, Study of Intravenous Posaconazole in Patients at Risk of Invasive Fungal Disease," *Journal of Antimicrobial Chemotherapy* 72 (2017): 3406–3413.

228. O. A. Cornely and A. J. Ullmann, "Lack of Evidence for Exposure-Response Relationship in the Use of Posaconazole as Prophylaxis Against Invasive Fungal Infections," *Clinical Pharmacology and Therapeutics* 89 (2011): 351–352.

229. D. C. Sabatino, N. W. Lange, D. M. Salerno, and J. Scheffert, "Elevated Posaconazole Trough Concentrations Are Not Associated With Increased Risk for Posaconazole Toxicity in Lung Transplant Recipients," *Clinical Transplantation* 37 (2023): e14826.

230. D. R. Andes, M. A. Ghannoum, P. K. Mukherjee, et al., "Outcomes by MIC Values for Patients Treated With Isavuconazole or Voriconazole for Invasive Aspergillosis in the Phase 3 SECURE and VITAL Trials," *Antimicrobial Agents and Chemotherapy* 63 (2019): e01634-18.

231. A. Desai, L. Kovanda, D. Kowalski, Q. Lu, R. Townsend, and P. L. Bonate, "Population Pharmacokinetics of Isavuconazole From Phase 1 and Phase 3 (SECURE) Trials in Adults and Target Attainment in Patients With Invasive Infections due to Aspergillus and Other Filamentous Fungi," *Antimicrobial Agents and Chemotherapy* 60 (2016): 5483–5491.

232. A. V. Desai, L. L. Kovanda, W. W. Hope, et al., "Exposure-Response Relationships for Isavuconazole in Patients With Invasive Aspergillosis and Other Filamentous Fungi," *Antimicrobial Agents and Chemotherapy* 61 (2017): e01034-17.

233. M. Martin-Cerezuela, C. Maya Gallegos, M. R. Marques-Minana, et al., "Isavuconazole Pharmacokinetics in Critically Ill Patients: Relationship With Clinical Effectiveness and Patient Safety," *Antibiotics (Basel)* 13 (2024): 706.

234. B. Rochat, S. Bolay, A. Pascual, T. Calandra, and O. Marchetti, "Liquid Chromatography-Mass Spectrometry Method for Quantification of Caspofungin in Clinical Plasma Samples," *Journal of Mass Spectrometry* 42 (2007): 440–449.

235. C. Adembri, G. Villa, E. Rosi, et al., "Caspofungin PK in Critically Ill Patients After the First and Fourth Doses: Suggestions for Therapeutic Drug Monitoring?," *Journal of Chemotherapy* 32 (2020): 124–131.

236. M. G. Sinnollareddy, J. A. Roberts, J. Lipman, et al., "Pharmacokinetic Variability and Exposures of Fluconazole, Anidulafungin, and Caspofungin in Intensive Care Unit Patients: Data From Multinational Defining Antibiotic Levels in Intensive Care Unit (DALI) Patients Study," *Critical Care* 19 (2015): 33.

237. D. Baracaldo-Santamaria, J. D. Cala-Garcia, G. J. Medina-Rincon, L. C. Rojas-Rodriguez, and C. A. Calderon-Ospina, "Therapeutic Drug Monitoring of Antifungal Agents in Critically Ill Patients: Is There a Need for Dose Optimisation?," *Antibiotics* 11 (2022): 645.

238. B. H. Segal, R. Herbrecht, D. A. Stevens, et al., "Defining Responses to Therapy and Study Outcomes in Clinical Trials of Invasive Fungal Diseases: Mycoses Study Group and European Organization for Research and Treatment of Cancer Consensus Criteria," *Clinical Infectious Diseases* 47 (2008): 674–683.

239. S. Koo, J. M. Bryar, L. R. Baden, and F. M. Marty, "Prognostic Features of Galactomannan Antigenemia in Galactomannan-Positive Invasive Aspergillosis," *Journal of Clinical Microbiology* 48 (2010): 1255–1260.

240. L. L. Kovanda, A. V. Desai, and W. W. Hope, "Prognostic Value of Galactomannan: Current Evidence for Monitoring Response to Antifungal Therapy in Patients With Invasive Aspergillosis," *Journal of Pharmacokinetics and Pharmacodynamics* 44 (2017): 143–151.

241. S. B. Gressens, C. Rouzaud, F. Lamoth, T. Calandra, F. Lanternier, and O. Lortholary, "Duration of Systemic Antifungal Therapy for Patients With Invasive Fungal Diseases: A Reassessment," *Molecular Aspects of Medicine* 103 (2025): 101347.

242. J. Frost, M. Gornicec, A. C. Reisinger, P. Eller, M. Hoenigl, and J. Prattes, "COVID-19 Associated Pulmonary Aspergillosis in Patients Admitted to the Intensive Care Unit: Impact of Antifungal Prophylaxis," *Mycopathologia* 189 (2024): 3.

243. S. Hatzl, A. C. Reisinger, F. Posch, et al., "Antifungal Prophylaxis for Prevention of COVID-19-Associated Pulmonary Aspergillosis in Critically Ill Patients: An Observational Study," *Critical Care* 25 (2021): 335.

244. H. Hagiya, Y. Nishimura, and F. Otsuka, "Safety and Usefulness of Nebulized Liposomal Amphotericin B: Systematic Scoping Review," *Pulmonary Pharmacology & Therapeutics* 82 (2023): 102233.

245. V. Monforte, P. Ussetti, J. Gavalda, et al., "Feasibility, Tolerability, and Outcomes of Nebulized Liposomal Amphotericin B for Aspergillus Infection Prevention in Lung Transplantation," *Journal of Heart and Lung Transplantation* 29 (2010): 523–530.

246. M. Peghin, V. Monforte, M. T. Martin-Gomez, et al., "10 Years of Prophylaxis With Nebulized Liposomal Amphotericin B and the Changing Epidemiology of Aspergillus spp. Infection in Lung Transplantation," *Transplant International* 29 (2016): 51–62.

247. K. Umemura, Y. Katada, S. Nakagawa, et al., "Comparison of the Safety and Cost-Effectiveness of Nebulized Liposomal Amphotericin B and Amphotericin B Deoxycholate for Antifungal Prophylaxis After Lung Transplantation," *Journal of Infection and Chemotherapy* 30 (2024): 741–745.

248. L. Kirchhoff, L. M. Braun, D. Schmidt, et al., "COVID-19-Associated Pulmonary Aspergillosis in ICU Patients in a German Reference Centre: Phenotypic and Molecular Characterisation of *Aspergillus fumigatus* Isolates," *Mycoses* 65 (2022): 458–465.

249. R. Lee, W. B. Kim, S. Y. Cho, et al., "Genetic Relationships of *Aspergillus fumigatus* in Hospital Settings During COVID-19," *Microbiology Spectrum* 13 (2025): e0190224.

250. T. Pelaez-Garcia de la Rasilla, I. Gonzalez-Jimenez, A. Fernandez-Arroyo, et al., "COVID-19 Associated Pulmonary Aspergillosis (CAPA): Hospital or Home Environment as a Source of Life-Threatening *Aspergillus fumigatus* Infection?," *Journal of Fungi (Basel, Switzerland)* 8 (2022): 316.

Supporting Information

Additional supporting information can be found online in the Supporting Information section. **Data S1:** myc70132-sup-0001-Supinfo.docx.

Appendix A

Members of the scientific committee of the Fungal Infection Network of Switzerland (FUNGINOS): Werner Albrich (Cantonal Hospital of Sankt Gallen), Christoph Berger (Children Hospital of Zurich), Anne Bergeron (University Hospital of Geneva), Sabina Berezowska (Lausanne University Hospital), Pierre-Yves Bochud (Lausanne University Hospital), Katia Boggian (Cantonal Hospital of Sankt Gallen), Anna Conen (Cantonal Hospital of Aarau), Julie Delaloye (Ensemble Hospitalier de La Côte), Stéphane Emonet (Hospital of Wallis), Véronique Erard (Hospital of Fribourg), Christian Garzoni (Clinica Luganese Moncucco), Daniel Goldenberger (University Hospital of Basel), Vladimira Hinic (University Hospital of Zurich), Cedric Hirzel (Bern Inselspital), Eleftheria Evdokia Kampouri (Lausanne University Hospital), Nina Khanna (University Hospital of Basel), Malte Kohns (Children University Hospital of Basel), Andreas Kronenberg (Bern Inselspital), Frederic Lamoth (Lausanne University Hospital), Basile Landis (University Hospital of Geneva), Oscar Marchetti (Ensemble Hospitalier de La Côte), Konrad Mühlethaler (Bern Inselspital), Linda Müller (Cantonal Hospital of Bellinzona), Dionysios Neofytos (University Hospital of Geneva), Michael Osthoff (University Hospital of Basel), Jean-Luc Pagani (Lausanne University Hospital), Chantal Quiblier (University Hospital of Zurich), Arnaud Riat (University Hospital of Geneva), Niels Rupp (University Hospital of Zurich), Bettina Schulthess (University Hospital of Zurich), Peter Werner Schreiber (University Hospital of Zurich), Martin Siegemund (University Hospital of Basel), Laura Walti (Bern Inselspital).