European Journal of Cancer 243 (2026) 116764

Contents lists available at ScienceDirect

European Journal of Cancer

journal homepage: www.ejcancer.com

Review

European consensus-based interdisciplinary guideline for invasive cutaneous squamous cell carcinoma: Part 2. Treatment - update 2026

Alexander J. Stratigos [a,*,1], Clio Dessinioti [a,1], Claus Garbe [b], Celeste Lebbe [c], Teresa Amaral [d], Veronique Bataille [e], Brigitte Dreno [f], Reinhard Dummer [g,h], Maria Concetta Fargnoli [i], Ana Maria Forsea [j,k], Christoffer Gebhardt [l], Catherine A. Harwood [m], Axel Hauschild [n], Christoph Hoeller [o], Lidija Kandolf-Sekulovic [p], Roland Kaufmann [q], Nicole WJ Kelleners-Smeets [r], Peter Koelblinger [s], Aimilios Lallas [t], Ulrike Leiter [b], Konstantinos Liopyris [a], Veronique del Marmol [u], David Moreno-Ramirez [v], Giovanni Pellacani [w], Ketty Peris [x,y], Philippe Saiag [z], Luca Tagliaferri [aa,ab,2], Myrto Trakatelli [ac], Ricardo Vieira [ad], Iris Zalaudek [ae], Petr Arenberger [af,3], Alexander C.J. van Akkooi [ag,ah,ai,4], Alexander M.M. Eggermont [aj,ak,4], Paul Lorigan [al,4], Mario Mandala [am,4], Josep Malvehy [an], On behalf of EADO[5], EDF[6], ESTRO[7], UEMS-DV[8], EORTC[9]

[a] 1st Department of Dermatology-Venereology, Andreas Sygros Hospital, Medical School, National and Kapodistrian University of Athens, Athens, Greece
[b] Centre for Dermatooncology, Department of Dermatology, Eberhard Karls University, Tuebingen, Germany
[c] Université Paris Cite,AP-HP Dermato-oncology and CIC, Cancer institute APHP.nord Paris cité, INSERM U1342 - Equipe 1 - CNRS EMR8000, Saint Louis Hospital, Paris, France
[d] Institute Strauss, 3 Rue de la Prte de l'Hôpital, Strasbourg 67000, France
[e] Mount Vernon Cancer Centre, East and North NHS Trust, Northwood, UK
[f] Nantes Université, INSERM, CNRS, Immunology and New Concepts in ImmunoTherapy, INCIT, UMR 1302/EMR6001, F-44000 Nantes, France
[g] Skin cancer Centre at University Hospital Zurich and University Zurich, Zurich, Switzerland
[h] Kantonsspital Aarau, Switzerland
[i] San Gallicano Dermatological Institute, IRCCS, Rome, Italy
[j] Carol Davila University of Medicine and Pharmacy Bucharest, Department of Oncologic Dermatology, Elias University Hospital Bucharest, Romania
[k] Health and Medical University Potsdam, Potsdam, Germany
[l] Department of Dermatology, University Medical Center Hamburg-Eppendorf, Hamburg, Germany
[m] Centre for Cell Biology and Cutaneous Research, Blizard Institute, Barts and the London School of Medicine and Dentistry, Queen Mary University of London, UK
[n] Department of Dermatology, University Hospital (UKSH), Kiel, Germany
[o] Department of Dermatology, Medical University of Vienna, Austria
[p] Department of Dermatology, Medical Faculty, Military Medical Academy, Belgrade, Serbia
[q] Department of Dermatology, Mainz University Medicine, Mainz, Germany
[r] Department of Dermatology, Maastricht University Medical Centre+, GROW-School for Oncology and Reproduction, Maastricht University, Maastricht, Netherlands
[s] Department of Dermatology and Venerology, Paracelsus Medical University, Salzburg, Austria
[t] First Department of Dermatology, School of Medicine, Faculty of Health Sciences, Aristotle University, Thessaloniki, Greece
[u] Department of Dermatology, University Hospital Erasme, Université Libre de Bruxelles, Belgium
[v] Department of Medical-&-Surgical Dermatology Service. Hospital Universitario Virgen Macarena, Sevilla, Spain
[w] Dermatology Unit, University of Rome La Sapienza, Rome, Italy
[x] UOC di Dermatologia, Dipartimento di Scienze Mediche e Chirurgiche Addominali ed Endocrino Metaboliche, Fondazione Policlinico Universitario A. Gemelli - IRCCS, Rome, Italy
[y] Dermatologia, Università Cattolica del Sacro Cuore, Rome, Italy
[z] Department of General and Oncologic Dermatology, Ambroise-Paré hospital, APHP, & EA 4340 "Biomarkers in cancerology and hemato-oncology", UVSQ, Université Paris-Saclay, Boulogne-Billancourt, France
[aa] Dipartimento di Diagnostica per Immagini e Radioterapia Oncologica, Fondazione Policlinico Universitario A. Gemelli IRCCS, Rome, Italy
[ab] Dipartimento di Scienze Radiologiche ed Ematologiche, Università Cattolica del Sacro Cuore, Rome, Italy
[ac] Department of Dermatology, Papageorgiou Hospital, Aristotle University Department of Medicine, Thessaloniki, Greece
[ad] Coimbra Hospital and University Centre, Coimbra, Portugal
[ae] Department of Dermatology, University of Trieste, Italy

* Correspondence to: 1st Department of Dermatology-Venereology, National and Kapodistrian University of Athens, Andreas Sygros Hospital, Athens, Greece.
E-mail address: alstrat2@gmail.com (A.J. Stratigos).

https://doi.org/10.1016/j.ejca.2026.116764
Received 19 March 2026; Accepted 17 April 2026
Available online 6 May 2026
0959-8049/© 2026 The Author(s). Published by Elsevier Ltd. This is an open access article under the CC BY-NC license (http://creativecommons.org/licenses/by-nc/4.0/).

[af] Department of Dermatovenereology, Third Faculty of Medicine, Charles University, Prague, Czech Republic
[ag] Department of Melanoma and Surgical Oncology, Institute of Academic Surgery, Royal Prince Alfred Hospital, Sydney, New South Wales, Australia
[ah] Faculty of Medicine & Health, University of Sydney, Sydney, New South Wales, Australia
[ai] Melanoma Institute Australia, Sydney, New South Wales, Australia
[aj] University Medical Center Utrecht & Princess Máxima Center, Utrecht 3584 CS, the Netherlands
[ak] Comprehensive Cancer Center Munich, Technical University Munich & Ludwig Maximilian University, Munich, Germany
[al] Department of Medical Oncology, Christie NHS Foundation Trust, Division of Cancer Sciences, University of Manchester, United Kingdom
[am] University of Perugia, Perugia, Italy
[an] Dermatology Department of Hospital Clinic of Barcelona, University of Barcelona, IDIBAPS, CIBER de enfermedades raras, Instituto Carlos III, Spain

ARTICLE INFO

Keywords:
Cutaneous squamous cell carcinoma
Locally advanced
Metastatic
Treatment
Surgical excision
Radiotherapy
Adjuvant
Neoadjuvant
Anti-PD-1
Cemiplimab
Pembrolizumab
Chemotherapy
Cetuximab
Clinical trials
Follow-up

ABSTRACT

Part 2 of the guideline addresses the updates on treatment recommendations in immunocompetent as well as immunosuppressed patients with invasive cutaneous squamous cell carcinoma (CSCC), based on current literature and expert consensus. A multidisciplinary panel of experts from the European Association of Dermato-Oncology (EADO), the European Dermatology Forum (EDF), the European Society for Radiotherapy and Oncology (ESTRO), the European Union of Medical Specialists (UEMS)-Dermatology Venereology and the European Organization of Research and Treatment of Cancer (EORTC), was formed to update the previous guideline on CSCC (version 2023). For common primary CSCC, first-line treatment is surgical excision with post-operative margin assessment or micrographically controlled surgery. Achieving clear histological margins is key for patients with CSCC amenable to surgery. Radiotherapy should be considered for non-surgical candidates/tumors. For patients with macroscopic regional lymph node metastases, individualized treatment should be discussed in the multidisciplinary tumor board. For patients with metastatic or locally advanced CSCC who are not candidates for curative surgery or radiotherapy, anti-PD-1 agents are the first-line systemic treatment, with cemiplimab being the approved systemic agent for advanced CSCC by the EMA. Second-line systemic treatments for advanced CSCC, include clinical trials, EGFR inhibitors (cetuximab) combined with anti-PD-1 immunotherapy, or chemotherapy or radiotherapy. The decision for adjuvant cemiplimab for CSCC at high risk of recurrence after surgery and radiotherapy should be discussed in the multidisciplinary tumor board. In addition, multidisciplinary board decisions are mandatory for all patients with advanced CSCC, considering the risks of toxicity, the age and frailty of patients and co-morbidities, including immunosuppression. Patients should be engaged in informed, shared decision-making on management and be provided with best supportive care to improve symptom management and quality of life. Frequency of follow-up visits and investigations for subsequent new CSCC depend on underlying risk characteristics.

INFORMATION ABOUT THE GUIDELINE

The European Interdisciplinary Guideline on invasive squamous cell carcinoma of the skin was written as a uniform text and then published in two separate but integral parts: Part 1 on diagnostics and prevention and Part 2 on treatment. Information about the Guideline is detailed in Stratigos et al. Part 1, including the information about societies in charge, financing of the guideline, scope, target population, objectives, methodology, audience and period of validity. The levels of evidence were graded according to the Oxford classification (detailed in Stratigos et al. Part 1). Recommendations were based on the level of best quality available evidence. The grades of recommendation were classified as follows:

A: Strong recommendation. Syntax: ‘shall’. Color green.

B: Recommendation. Syntax: ‘should’. Color light green.

C: Weak recommendation. Syntax: ‘may/can’. Color yellow.

X: Contraindication. Syntax: “Shall not/should not” be recommended. Color red.

GPP: Good clinical practice point. Based on consensus, when adequate evidence was not available. Color white.

Expert consensus was provided wherever adequate evidence is not available (described in Appendix-guideline part 2, Supplementary Methods). The guideline manuscripts were additionally externally reviewed by reviewers from each participating society, who were not included as authors of the guidelines.

The changes in the guideline update 2026 compared with the guideline version 2023 are presented in Supplementary Appendix-guideline part 2. In view of the regulatory approval of adjuvant cemiplimab for CSCC at “high risk of recurrence”, the classification of CSCC was revised to “low risk” and “higher-risk” throughout the guideline. Also, the previously termed “high-risk” factors were revised to “risk factors” to avoid confusion with the tumors at high risk of recurrence eligible for adjuvant cemiplimab.

Disclaimer

Medicine is subject to a continuous development process. Therefore, all statements, in particular on diagnostic and therapeutic procedures, can only correspond to the scientific knowledge at the time of printing of this guideline. The attending physician invoking these guideline recommendations must consider scientific progress since the publication of the guideline.

Scope

This guideline has been written in order to assist clinicians in treating patients with invasive squamous cell carcinoma of the

[1] Contributed equally.
[2] ESTRO
[3] UEMS-DV
[4] EORTC
[5] European Association of Dermato-Oncology
[6] European Dermatology Forum
[7] European SocieTy for Radiotherapy and Oncology
[8] European Union of Medical Specialists (Union Européenne des Médecins Spécialistes) -Dermatology Venereology
[9] European Organization for Research and Treatment of Cancer

skin. This publication was conceptualized mainly due to advances in the medical treatment of patients with invasive squamous cell carcinoma of the skin, which justify a newer multidisciplinary therapeutic strategy. The use of these guidelines in clinical routine should improve patients' care.

1. General considerations for the treatment of CSCC

The primary treatment of CSCC is surgery, aiming at the clinical and microscopic clearance of the tumor (R0 surgery). The preservation of function and cosmesis are additional objectives of treatment. Achieving clear histological margins is the most important treatment consideration for patients with CSCCs amenable to surgery. Radiotherapy (RT) may be considered as a primary treatment in patients/tumors who are not candidates for surgery (e.g. locally infiltrating tumor, comorbidities or declined surgery) or in cases when curative surgery is not possible or could be disfiguring. The very low risk of radiation-induced, in-field malignancy in the future, in patients younger than 60 years old with CSCC, should be considered during the decision making [1].

Adjuvant therapy is defined as additional treatment, either systemic and/or radiotherapy, given after complete resection at the primary surgical treatment (R0), with the aim to reduce the risk of recurrence. The benefit of adjuvant RT to the nodal basin has been shown after lymph node dissection for CSCC with nodal metastasis. Cemiplimab, a PD-1 antibody was approved by FDA and EMA for the adjuvant systemic treatment of CSCC with high risk of recurrence after surgery and radiation therapy.

Systemic treatment options used for advanced CSCC include clinical trials, immunotherapy with programmed death receptor-1 (PD-1) and PD-ligand 1 (PD-L1) blocking antibodies, epidermal growth factor receptor (EGFR) inhibitors, and chemotherapy. Currently, the anti-PD-1 agent cemiplimab is the only systemic treatment approved in Europe for the treatment of patients with metastatic CSCC (mCSCC) or locally advanced CSCC (laCSCC) who are not candidates for curative surgery or radiotherapy.

The decision for adjuvant cemiplimab for CSCC at high risk of recurrence after surgery and radiotherapy should be discussed in the multidisciplinary tumor board. In addition, a multidisciplinary tumor board approach is mandatory for all patients with advanced disease. For patients with macroscopic regional lymph node metastases, individualized treatment should be discussed in the multidisciplinary tumor board. The risks of toxicity, age and frailty of patients, in addition to comorbidities, including immunosuppression, should be considered [2]. The systematic review of Leus et al., reported that the age of elderly patients did not significantly affect surgery outcomes, including recurrence rate, complication rate and disease-specific survival [3]. However, frailty may be a more relevant issue. Frail patients (ECOG performance status 2 or higher) have not been included in pivotal clinical trials for CSCC. Real-world studies report encouraging results for response and toxicity with anti-PD-1 agents in frail patients with CSCC, although the number of such included patients is currently small [4–6].

All treatment considerations are based on the informed consent of the patient (or an appointee having the legal authority to decide on the patient's behalf in case of a patient lacking mental capacity of informed consent, according to national legal requirements) and on offering a shared decision making. The treating physician will inform the patient about the first and other lines of treatment based on current best evidence and guidelines, explain the expected benefit and risks, and involve the preferences and priorities of the individual patient in the shared decision process.

2. Surgery for common primary CSCC

Surgical excision is considered the primary treatment of primary CSCC, regardless of the age of the patient or the anatomic location. Surgery provides a high rate of clinical and microscopic complete resection (R0 surgery).

Two different approaches may be offered: (1) Excision with standardized safety margins and post-operative margin assessment (where only part of the actual resection margin is being examined), or (2) micrographically controlled surgery (3D) with a mapping of the entire circumferential and deep tumor borders followed by step-wise re-excisions in case of any residual tumor nests [7,8]. Frequently, a reconstructive procedure (i.e. flap or graft closure) is necessary to repair the surgical defect resulting from tumor resection. With few exceptions (e.g. partial or interim linear closure to control bleeding or protect exposed underlying structures), final reconstruction is discouraged before histological confirmation of clear margins [9,10]. The surgical management of tumors requiring extensive excisions should be performed by surgeons (dermato-surgeons, plastic surgeons or head and neck surgeons) with appropriate expertise in reconstructive procedures.

2.1. Standard excision

Surgical excision including all visible tumor borders together with a risk-adapted adjacent safety margin of clinically normal-appearing skin is the standard treatment of invasive CSCC. Conventional excision should be followed by post-operative pathologic assessment of resection margins to ensure an appropriate lateral and deep tumor free margin and thus minimize the risk of local recurrence and metastases [1,11,12]. Routinely, histological examination of the excised tumor bed is performed in a cross-sectional fashion with vertical sample cuts (bread-loaf sections for 2D histology) obtained from formalin-fixed, paraffin-embedded tissue [8,13].

Clinical safety excision margins should be adapted to the likelihood of subclinical extensions and recurrence [14], as defined by risk factors including clinical (tumor diameter > 2 cm, high-risk sites), histological (thickness > 6 mm or invasion beyond subcutaneous fat, perineural invasion, poor differentiation, desmoplasia) and patient- and treatment-related criteria (immunosuppression, positive histological margins, see part 1 of the guideline). There are no randomized studies investigating optimal clinical safety margins for excision. In clinically well-defined low-risk CSCCs with a diameter of less than 2 cm, a clinical safety margin of 4 mm has achieved cure rates of 95–97% in prospective studies [15,16]. Nevertheless, diameter is only an approximate reflection of the actual degree of tumor aggressiveness and additional histological features may increase the risk of margin involvement, even in smaller tumors [17]. Therefore, several national guidelines discuss margins between 4 and 6 mm for tumors lacking risk features [1,12,18–20]. A recent prospective study reported a 98% complete excision in T1 tumors excised with 5 mm margin versus 91% of T2 tumors and 81% of T3 tumors excised with 1 cm. Most of the residual tumor involved the deep margin [21]. In the event, that a CSCC thought to be low-risk at biopsy is proven to have a risk factor after excision with a 5 mm clinical safety margins, a re-excision with a histological clear margin can be discussed. The European consensus group suggests a 5 mm clinical safety margin for low-risk lesions but now also suggests a margin between 4 and 6 mm as a more flexible choice and in accordance with major national guidelines. (Fig. 1)

For higher-risk CSCC, however, even though wider margins are recommended, there is currently no unified recommendation on appropriate safety margins [22]. Some recent guidelines discuss the need for complete excision without further specifying margins or emphasize the value of micrographically controlled surgery in higher-risk CSCC, primarily due to the wide variability of characteristics that may define CSCC at higher risk [9,12,13]. According to an early work from Brodland et al, for larger CSCCs (> 2 cm in maximum clinical diameter) and/or other risk factors, an excision margin of at least 6 mm is required [15]. The British guideline recommends ≥ 6 mm for high-risk, and ≥ 10 mm for "very high-risk" CSCC [1]. Additional

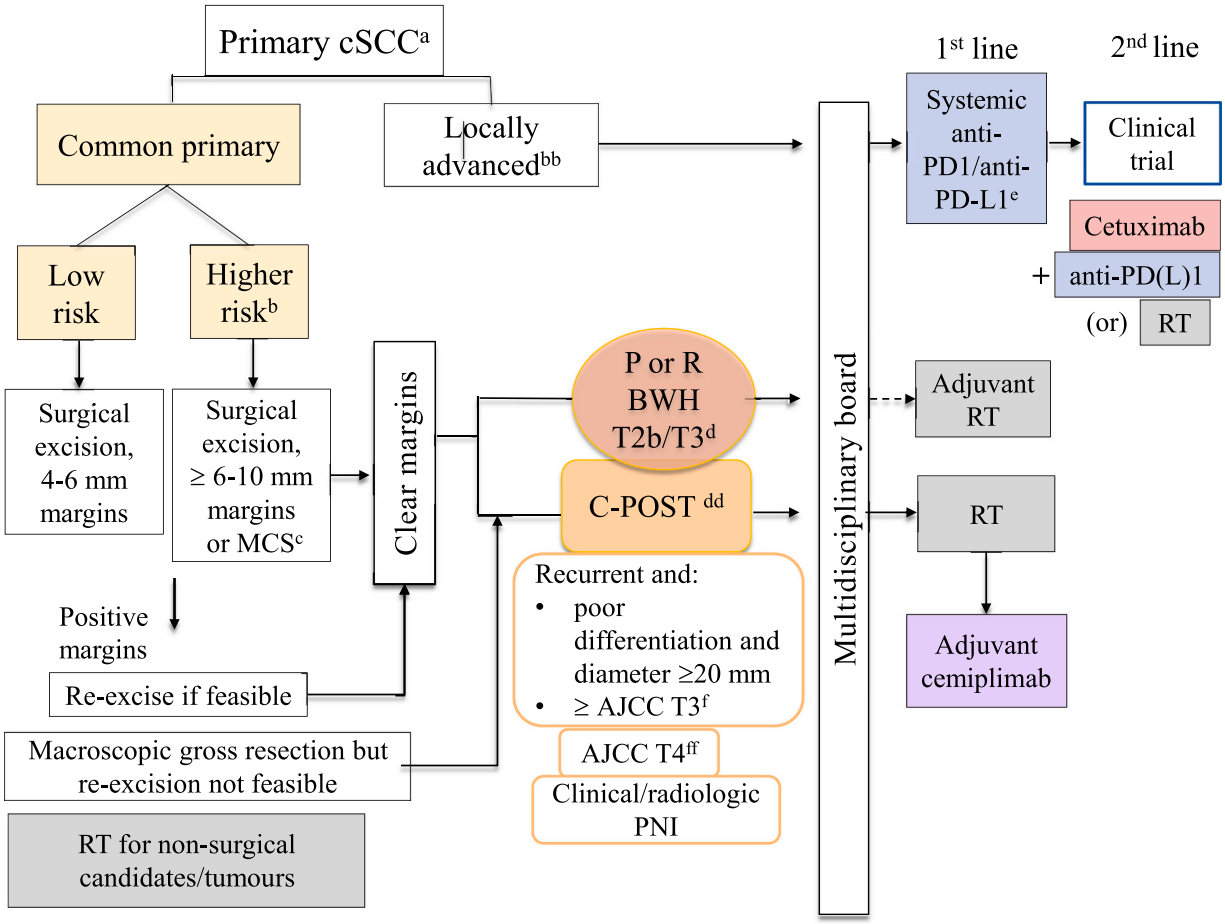

Fig. 1. Proposed treatment algorithm for patients with common primary or locally advanced cSCC. Strength of consensus: 100%. MCS: micrographically controlled surgery, RT: radiotherapy. [a] For detailed indications and recommendations of treatment, refer to relevant section text in the Guidelines. [b] With any one risk factor. [bb] Locally advanced by definition not amenable to curative surgery or RT. [c] MCS instead of sectional assessment is advised, when available. [d] BWH T2b: 2–3 risk factors, T3: 4 risk factors or bone invasion. BWH risk factors: diameter ≥ 20 mm, poor differentiation, histological PNI ≥ 0.1 mm, tumor invasion beyond fat. [dd] In C-POST trial, non-nodal criteria for high risk of recurrence for localized cSCC with macroscopic gross resection of disease included: clinical and /or radiologic involvement of named nerves, or T4 lesions with invasion of cortical bone or skull base, or recurrent cSCC plus ≥ 1 additional feature of ≥T3, or poorly differentiated histology and ≥ 20 mm diameter. [e] All systemic treatments are off-label, except for anti-PD-1 agent cemiplimab that is approved by FDA/EMA for patients with locally advanced or metastatic CSCC who are not candidates for curative surgery or curative radiation, and pembroblizumab that is approved by FDA for recurrent or metastatic cSCC that is not curable by surgery or radiation, and cosibelimab that is approved by FDA for adults with metastatic or locally advanced CSCC who are not candidates for curative surgery or curative radiation. [f] As included in C-POST trial, AJCC 8th edition, T3: tumor > 4 cm in greatest dimension or minor bone erosion or deep invasion > 6 mm measured from the granular layer of normal adjacent epithelium. [ff] As included in C-POST trial, AJCC8 T4: with invasion of cortical bone or skull base. P: Primary, R: Recurrent. Dashed line: weaker recommendation than solid line.

recommendations from reviews or guidelines also vary from a lower limit of 6 up to ≥ 10 mm, or favor micrographically controlled excisions as first-line treatment instead [19,20,23–26]. As the independent prognostic effect of high-risk factors has not been consistently reported, a specific recommendation on the clinical safety margins cannot be given, but should fall within the 6–10 mm range and be based on individual risk assessment and tumor- and patient-related characteristics. In addition to the European consensus group also the Japanese Dermatology Society suggests 6–10 mm safety margins for CSCC with risk factors [20,27]. A retrospective study from Japan has challenged the need for wider excision margins for patients with CSCCs at NCCN "high-risk" and "very-high-risk" categories. They compared two cohorts excised either with safety margins adherent to national guidelines (6 – 10 mm) or with narrower margins (≤ 5 mm). Though there was a significantly higher incomplete excision rate in the narrow-margin-group of "very-high-risk" tumors, the authors did not find significant differences between both groups with regard to cumulative incidence of local relapse, CSCC relapse (local, regional nodal, or distant relapse), or CSCC death [28].

In patients with skin areas covered by a cluster of multiple invasive CSCCs (e.g. on the dorsal hands or scalp), *en bloc* excision of the involved field with subsequent skin grafting can be offered as an effective treatment.

The depth of excision should include the subcutaneous tissue (together with the underlying galea-aponeurosis in scalp locations) while sparing the perichondrium or periosteum, provided these structures are not affected by the tumor [18,29,30].

In case of positive margins, a re-excision shall be done for operable cases [31]. Post-operative radiotherapy should be considered after surgical excision for CSCC with positive margins and for which re-excision with clear margins is not possible. Wider excision should be considered when margins appear more limited than the recommended safety margins, as described in the pathology report, after considering the tissue shrinkage during the process (Fig. 1).

Instead of extended standard margins, micrographically controlled surgery should be considered in selected cases of higher-risk CSCC,

though evidence of superiority of the method over standard excisions is based only on retrospective studies [32–35].

2.2. Micrographically controlled surgery

Micrographically controlled surgery is used as a collective term for a range of surgical techniques used to remove skin cancer with complete margin control. These stepwise procedures allow for peritumoral examination that is repeated until all circumferential and deep borders are completely free of tumor. Micrographically controlled surgery thus provides complete margin assessment, enables histological clearance prior to reconstruction, and minimizes the removal of uninvolved tissue [36]. Two techniques are mainly being used in Europe with diverse modification of sectioning the tissue specimen: Mohs micrographic surgery (MMS) and 3D histology [37], the first one making use of intra-operative frozen sections whereas the second one uses paraffin sections [38] (https://esms-mohs.eu/fileadmin/user_upload/ESMS_Position_Paper_-_WEB.pdf). The NCCN Guidelines on CSCC uses the descriptive term „Peripheral and deep en face margin assessment (PDEMA)", referring to the techniques, in which the entire marginal surface of the surgical specimen (including the complete deep and peripheral margin) is microscopically visualized and histopathologically analysed for the presence of SCC [12]. Among the available techniques and modifications of micrographically controlled surgery achieving this purpose of en face margin assessment are MMS with frozen sectioning (Supplementary Figure 1), or the Tübingen Muffin (Supplementary Figure 2) and Tübingen Torte techniques, both employing formalin fixation and paraffin embedding and complete margin assessment [12, 39] (https://esms-mohs.eu/fileadmin/user_upload/ESMS_Position_Paper_-_WEB.pdf). Furthermore, the NCCN guidelines include a checklist to apply before naming a technique PDEMA as many other surgical techniques exist such as square technique, perimeter technique, moat technique and quadrant technique where the deep margin is examined in vertical sections and therefore a complete visualization of the deep margin is not given [12]. An advantage of MMS is that the tumor can be removed and on the same day a reconstruction can be performed shortly after. There have been attempts to replace the traditional MMS frozen tissue with the use of fresh-tissue sections examined intra-operatively by ex-vivo confocal microscopy [40], but in CSCC this approach has yet failed at reliably detecting small areas of residual tumor or more specific morphological features such as perineural growth.

There is yet no randomized trial that compares micrographically controlled surgery techniques with conventional surgical excision for CSCC. Micrographically controlled surgery provides the highest rate of R0 resection, above 90%, and lower recurrence rates (0%-4%) compared to conventional surgery (recurrence rates: 2.5%-8.0%)] [32,36,41–49].

The systematic review and meta-analysis of Fraga et al., compared recurrence for complete margin assessment versus excision with sectional assessment in higher-risk keratinocyte carcinomas. They reported significantly lower locoregional recurrences with complete margin assessment versus sectional assessment for all keratinocyte carcinomas (3.9% vs 13.5%, $p = 0.001$) and for CSCC with PNI (9.8% vs 32%, $p < 0.001$) [50]. The value of MMS has been documented, especially for head and neck tumors [41–44]. The value of MMS in the prevention of local recurrence has been reported in retrospective studies. In one study, including 647 high risk CSCC there were 19 local recurrences (LR) (2.9%), 31 nodal metastases (4.8%), 7 distant metastases (1.1%), and 7 disease-specific deaths (DSD) (1.1%) [45]. The other retrospective study including 579 patients with 672 CSCCs of the head and neck (380 treated with MMS and 292 with standard excision) concluded that MMS might be superior to standard excision for CSCCs of the head and neck because of a lower recurrence rate after adjustment for tumor size and deep tumor invasion (3% vs 8%) [32].

When modelling the expenses of MMS under theoretical assumptions based on the data from previous studies on intermediate risk CSCC, MMS was more cost-effective than wide local excision in an outpatient setting [51]. The higher complexity of this multi-step procedure usually limits its use to patients with high risk tumors, in whom micrographically controlled surgery provides the best guarantee for complete tumor resection with optimal anatomic, aesthetic and functional preservation. In conclusion, the various modifications of micrographically controlled surgery are tissue conservative and effective treatments in cases of higher-risk CSCC, particularly in the head and neck area. (Fig. 1)

Recommendation 1.
Surgical excision of primary CSCC (same with 2023)[12,27,36,52,45].

Surgical excision of primary CSCC	**Guideline 2026** **Evidence-based recommendation**
Grade of recommendation A	Surgical excision with histological control shall be performed as standard treatment. The aim of CSCC surgery shall be a complete excision (R0) with histological confirmation of peripheral and deep excision margins. Large tumors or tumors on the head and neck can undergo a punch or incisional biopsy for histological confirmation and planning of a subsequent complete excision. In case of positive margins, a re-excision shall be done, for operable cases.
Level of evidence 2	Guideline adaptation [12, 27] Systematic review [36, 52] Retrospective study [45]
	Strength of consensus: 100%

Recommendation 2.
(updated from recommendation 2023)[10,12,18,19,23,25–27,34,35].

Surgery and safety margins	**Guideline 2026** **Evidence-based recommendation**
Grade of recommendation B	Low-risk CSCC should be excised with a clinical safety margin of 4-6 mm. CSCC with risk factors should be excised with a clinical safety margin of ≥ 6 up to 10 mm whenever possible or by micrographically controlled surgery. Micrographically controlled surgery should be considered for CSCC in functional/cosmetical sensitive areas.
Level of evidence 2-3	Guideline adaptation [12, 18, 19, 23, 25-27] Delphi consensus[10] Retrospective studies [34, 35]
	Strength of consensus: 100%

Recommendation 3.
(same with 2023).

Wound closure	Guideline 2026
GPP	As long as an R0 resection is not histologically confirmed, wound closure with local tissue movements (flaps) should be avoided. Strength of consensus: 100%

3. Surgery for regional nodal disease

The standard first-line management for patients with CSCC presenting with resectable nodal metastases has traditionally consisted of complete or radical lymph node dissection, followed eventually by adjuvant radiotherapy when additional risk factors are present, an approach largely extrapolated from studies in head and neck mucosal SCC [53,54]. Neck dissection in addition to superficial parotidectomy should be performed if the parotid gland is affected, since a lower disease-specific survival was observed with radiation therapy alone [55]. In a retrospective multicenter study of 1151 patients with CSCC of the head/neck metastatic to parotid and/or cervical nodes treated with curative intent by surgery ± adjuvant therapy, the estimated 5-year locoregional failure rate was 24.5%, the 5-year disease-specific death was 22.4%. In that study, distant metastases occurred in 7.5% of patients at a median follow up of 3.2 years [56].

Huis In 't Veld et al. reported a 5-year disease-specific survival of 52% in patients with CSCC with nodal involvement treated with therapeutic lymph node dissection (of whom 65% also received adjuvant radiotherapy), indicating that lymph node dissection + /- adjuvant radiotherapy can achieve durable survival in approximately half of regionally metastatic CSCC cases. It is obvious that despite curative intent surgery + adjuvant radiotherapy, these patients are at high risk of recurrence/metastases, and would potentially benefit from additional effective systemic therapy [57].

The extent of lymph node dissection should be discussed in an interdisciplinary tumor board after thorough evaluation of tumor-related (aggressiveness, involved basin, tumor burden), surgical (potential complications, morbidity), and patient-related factors (overall condition, performance status, preferences, expectations).

Primary definitive radiotherapy alone should be considered for patients who are not amenable to surgery, either because of patient-related factors or because a R0 resection cannot be achieved, based on multidisciplinary decision-making. (See Section 4. Radiotherapy)

Adjuvant cemiplimab shall be offered as standard of care for CSCC with high-risk of recurrence after surgery and radiation therapy (see Section 6. Adjuvant systemic therapy).

Neoadjuvant immunotherapy has recently emerged as a promising off-label alternative for resectable high-risk CSCC, including those with nodal metastatic disease. Although phase III randomized trials are still lacking, the consistent evidence of high pathological response rates, and the possibility of surgical de-escalation observed in phase II trials and real-world series support the need to investigate the place of neoadjuvant immunotherapy compared to-upfront radical lymph-node dissection in patients with resectable nodal disease. (see Section 7. Neoadjuvant systemic therapy). Neoadjuvant strategies lack EMA approval. Once neoadjuvant therapy becomes established as an upfront option, attention will inevitably shift to defining the optimal surgical approach after treatment. While some trials and real-world series have allowed selected patients with strict clinical complete responses to forgo or de-escalate surgery and adjuvant radiotherapy, most prospective studies of neoadjuvant PD-1 blockade in resectable CSCC have still mandated standard surgery—wide excision or complete lymph-node dissection as appropriate—regardless of pathological response, and no randomised comparisons of different surgical strategies have yet been conducted. Notably, a retrospective cohort of 41 patients with head and neck CSCC treated with neoadjuvant cemiplimab compared response-adapted oncologic surgery (RAOS) with standard resection; in this series, not all patients with nodal metastases underwent mandatory complete dissection, and the extent of lymph-node surgery was individualised according to post-neoadjuvant response and multidisciplinary assessment [58]. Likewise, the phase II study of neoadjuvant pembrolizumab also applied a response-adapted surgical strategy after PD-1 blockade [59]. These findings indicate that neoadjuvant PD-1 therapy may allow a response-adapted approach to lymph-node surgery in patients with nodal disease.

Therapeutic radical regional lymph node dissection remains the standard of care for resectable nodal disease [13,27,49–58]. Nevertheless, over the last decade, a trend toward less extensive and more selective lymph node dissections has developed, particularly in head-and-neck CSCC, where this approach has yielded regional control and survival rates of 85%–100%, comparable to those reported for conventional radical neck dissections [56,60,61]. The extent of lymph node dissection should therefore be discussed in an interdisciplinary tumour board after thorough evaluation of tumour-related (aggressiveness, involved basin, tumour burden), surgical (potential complications, morbidity), and patient-related factors (overall condition, performance status, preferences, expectations).

Recommendation 4.
(updated from 2023)[12,25,60–69].

Therapeutic lymph node dissection	**Guideline 2026** **Evidence-based recommendation**
Grade of recommendation: B	The need and extent of surgical resection/lymph node dissection is determined by the surgeon in collaboration with the multidisciplinary tumor board. For patients with macroscopic regional lymph node metastases, individualized treatment should be discussed in the multidisciplinary tumor board.
Level of evidence: 3	Review[60, 61] Prospective study[62] Retrospective study[63-68] Guidelines[12, 25, 69]
	Strength of consensus: 100%

4. Radiotherapy

Modern radiotherapy (RT), empowered by recent technological innovations, plays a crucial role within an interdisciplinary approach to oncology, with an increasingly central involvement in treatment personalization. Advanced techniques such as Intensity-Modulated Radiotherapy (IMRT), Image-Guided Radiotherapy (IGRT), and Interventional Radiotherapy (modern brachytherapy) allow for greater precision, reduced side effects, and improved functional and aesthetic outcomes [70,71]. FLASH radiotherapy is a promising innovation for treating skin cancer, with the potential to improve tolerance in normal tissue while preserving tumour control. Further clinical trials are needed to evaluate its role in clinical practice [72–74].

4.1. Primary definitive radiotherapy

Definitive primary radiotherapy represents a valid alternative and curative treatment strategy to surgery for small CSCCs. RT should be considered as primary treatment option in patients who are not candidates for surgery (e.g. locally infiltrating CSCC not amenable to surgery, presence of comorbidities or when patients decline surgery) or in cases when curative surgery is not possible or could be disfiguring or burdened by poor functional outcome, especially CSCCs located on the face (i.e. eyelid, nose, lip) or large lesions on the ear, forehead or scalp [75]. The discussion about radiotherapy should be done in multidisciplinary context involving a radiation oncologist with recognized expertise in the management of skin cancer.

Prospective randomized trials comparing the effectiveness of primary radiotherapy in terms of local tumor control and patient survival compared to other local therapy modalities are not available. A meta-analysis (2013) of 14 observational studies of radiotherapy for 1018 primary CSCCs reported a pooled average local recurrence rate of 6.4% [44].

Modern radiotherapy represents a versatile treatment modality and depending on tumor and/or patient factors, can be delivered as an external beam technique or via brachytherapy (Interventional Radiotherapy, BT, IRT). External beam RT (EBRT) may involve electron beams or photons. Treatment can be delivered to a small superficial area (e.g. nasal ala) or a large complex volume (e.g. whole scalp or skull base). The radiotherapy technique should be selected based on the location, size and thickness of the lesion, favoring techniques that allow for precise dose conformity while limiting the dose to surrounding tissues as much as possible.

Total prescribed dose and fractionation should reflect the differences in radiobiological effectiveness between different radiation modalities. Doses of 60–64 Gy in fractions of 2 Gy for tumors of < 2 cm (or other schedules with equivalent radiobiological dose) and 60–70 Gy in fractions of 2 Gy for tumors of ≥ 2 cm (or other schedules with equivalent radiobiological dose) are recommended. Hypo-fractionated RT (larger dose per fraction) have been shown to have equally high efficacy and could result in better patients' compliance (fewer fractions) [76]. Interventional radiotherapy could also be proposed based on the tumor size and location as an alternative to EBRT. Prescribed doses must encompass all visible tumor plus an appropriate variable margin (clinical target volume), sparing as much as possible of the surrounding healthy structures [77–79]. Irrespective of treatment intent (definitive, adjuvant, palliative), dosimetry and technical considerations should be surveyed by a certified radiation oncologist.

Radiotherapy is an overall safe procedure, although it may be associated with complications such as acute radiation-induced dermatitis and chronic onset of depigmentation and telangiectasias. The latter will become more visible over the years, and this must be considered when offering treatment for younger patients. Higher doses per fraction lead to higher rates of late toxicity [80]. Therefore, hypofractionation schedules should be proposed for elderly, especially frail patients, or when long-term cosmetic outcome is of lesser importance.

RT may be combined with systemic therapies including immunotherapy, chemotherapy or targeted therapies (i.e. cetuximab) in more advanced cases.

Recommendation 5.
(updated from recommendation 2023)[44,81,82].

Definitive primary RT	Guideline 2026 Evidence-based recommendation
Grade of recommendation B	Primary radiotherapy should be considered for inoperable or difficult-to-operate tumors or in patients not amenable to surgery.
Level of evidence 3	Systematic review/meta-analysis, high-risk of bias [44] Retrospective studies in small numbers and heterogeneous group of patients [81, 82]
	Strength of consensus: 100%

4.2. Postoperative RT

4.2.1. Definitive salvage post-operative radiotherapy

Definitive salvage post-operative RT should be considered after surgical excision for CSCC with positive margins (residual microscopic (R1) or macroscopic (R2) tumor) where re-excision is not possible [12,83]. Recommended dose for postoperative RT is 60–66 Gy in 30–33 fractions, 5 fractions per week [12,25,83], but in the case of R2, specific considerations should be made according to the size of residual disease.

The majority of studies defining risk factors for local recurrence are restricted to the head and neck area. An international consensus guideline by the Head and Neck Cancer International Group (HNCIG) for the delivery of postoperative RT in the head and neck region was published in 2020 [79]. The guideline from HNCIG also includes a detailed description of recommended radiotherapy techniques to be used.Evidence indicates that postoperative radiotherapy is less effective than exclusive radiotherapy, therefore, if the risk of positive surgical margins is considered high by the surgeon, exclusive primary radiotherapy should be carefully considered and discussed in multidisciplinary context as a potential radical treatment [84].

4.2.2. Adjuvant radiotherapy

Adjuvant RT refers to RT performed after complete surgical resection of the tumor (R0). Adjuvant RT is offered as part of clinical practice in many medical centers for patients with CSCC with risk factors, particularly for tumors with PNI. Current practice is influenced by the standard use of adjuvant RT for mucosal SCC of the head and neck. An important limitation of most studies on the use of adjuvant RT for primary common CSCC, is the fact that they do not specify the results of histological margin assessment or include patients treated with RT for CSCC with positive margins as well as those with negative margins. Recent studies have shown no benefit for adjuvant RT focusing on CSCC with clear surgical margins [85–89]. The meta-analysis of Kim et al., in non-metastatic CSCC with any risk factor present treated with margin-negative resection (29 retrospective, 2 prospective, 2 case series), reported no statistically significant differences in poor outcomes between surgery alone and surgery with adjuvant RT [86]. On the other hand, the meta-analysis of Zhang et al., reported lower recurrence, longer disease-free survival and longer overall survival with adjuvant radiotherapy, but included primary as well as metastatic CSCC, and the benefit of adjuvant RT may have concerned nodal metastatic CSCC [90]. Adjuvant RT was associated with a lower risk for locoregional recurrence compared to surgery alone, for CSCC with multiple risk factors (at least 2 BWH risk factors) in the study of Ruiz et al. There was no significant effect on the risk for disease-specific death [91]. In a modified Delphi consensus process involving 30 experts the recommendations support the consideration of adjuvant RT in selected patients with risk features, such as perineural invasion, deep tissue or bone infiltration, poor differentiation, tumor size $\geq$ 2 cm, or recurrence, even in the presence of negative surgical margins, to improve local control [92]. In a retrospective study of 10,000 CSCCs, having large-caliber PNI as the sole risk factor was rarely observed in only 16 tumors. In addition, these CSCCs with PNI had a relatively low cumulative 5-year incidence of 8% for local recurrence, thus limiting the benefit of adjuvant RT for this risk factor alone [89].

Regarding nodal metastatic CSCC, adjuvant RT has been recommended for CSCC of the head and neck following lymph node dissection, although it may not be necessary in immunocompetent patients with a single, small cervical lymph node metastasis ($<$ 3 cm) without extracapsular extension. Adjuvant RT can be considered for surgically treated CSCC of the trunk with nodal metastasis following lymph node dissection, although the evidence is less robust compared to CSCC of the head and neck [12,54,93].

Recommendation 6.
(updated from 2023)[53,54,83,93–96].

Post-operative RT	Guideline 2026 Evidence-based recommendation
Grade of recommendation B	Post-operative radiotherapy should be considered after surgical excision for CSCC with positive margins and for which re-excision with clear margins is not possible.
Level of evidence 3	Meta-analysis (20 observational studies and 1 randomized phase III study)[54] Randomized phase III study[94] Retrospective studies[53, 83, 95, 96] Guidelines[93]
	Strength of consensus: 100%

Recommendation 7.
(same with recommendation 2023)[53,54,83,93–95].

Adjuvant RT for resected nodal metastatic CSCC	**Guideline 2026** **Evidence-based recommendation**
Grade of recommendation B	Adjuvant radiotherapy following therapeutic lymphadenectomy, should be considered in CSCC of the head and neck with regional nodal metastases and extracapsular extension.
Level of evidence 3	Meta-analysis (20 observational studies and 1 randomized phase III study)[54] Randomized phase III study[94] Retrospective studies[53, 83, 95] Guideline[93]
	Strength of consensus: 100%

Recommendation 8.
Adjuvant RT for CSCC (updated from 2023)[91].

Adjuvant RT treatment for CSCC with risk factors	**Guideline 2026** **Evidence-based recommendation**
Grade of recommendation C	Adjuvant radiotherapy may be discussed for CSCC with multiple risk factors (BWH T2b/T3) and clear surgical margins.
Level of evidence: 4	Retrospective study[91]
	Strength of consensus: 100%

5. Systemic treatments for advanced CSCC

5.1. Immunotherapy with checkpoint inhibitors

A pivotal clinical trial for CSCC with cemiplimab, a PD-1 antibody, was initially reported by Migden and co-workers [97] and has received several updates [98–102] (Table 1, Supplementary Table 1). In this phase 2 non-randomized clinical trial ("EMPOWER-CSCC-1") 59 adult CSCC patients with metastatic disease and 78 patients with locally advanced disease who were not candidates for curative surgery or irradiation were treated with 3mg/kg body weight cemiplimab every 2 weeks for up to 2 years. Another 56 adult patients with metastatic CSCC received cemiplimab with a flat dose of 350 mg every 3 weeks intravenously for up to 1 year. 33.7% of the whole study population had received prior systemic therapy. The endpoint of the clinical trial was the response rate assessed by an independent review committee per RECIST 1.1 (for scans) and modified WHO criteria (for photos). Additionally, a confirmatory cohort (group 6) of 167 patients – 59.9% with metastatic and 40.4% with locally advanced disease - for the fixed-dose of 350 mg was included.

The final analyses of this trial for groups 1–3 was published together with the primary analysis of the confirmatory cohort [102]. (Table 1) At a median follow-up of 42.5 months, the overall response rate (ORR), complete response (CR) and partial response (PR) was 50.8%, 20.3% and 30.5% for group 1, 44.9%, 12.8% and 32.1% for group 2 and 46.4%, 19.6% and 26.8% for group 3, respectively. (Table 1) Summarizing the results of the 3 groups (n = 193), the ORR was 47.2% including CR in 17.1% of patients and PR in 30.1%. The median duration of response was 41.3 months, median progression-free survival (PFS) 22.1 months and the median overall survival (OS) had not been reached at the data cut-off (95% CI for OS 56m-not evaluable). In the confirmatory cohort for the 350 mg dose the median follow-up was 8.7 months and ORR was 45.1% including 5.5% complete responses. Median PFS was 14.7 months, whereas the duration of response and OS have not reached the median yet. A total of 10.4% (groups 1–3) and 13.7% (group 6) of patients needed to discontinue the treatment due to adverse events. The most frequent adverse events were fatigue, diarrhea, nausea, and pruritus. There were no grade 5 adverse events [101,102].

Another PD-1 antibody, pembrolizumab, has been investigated in a phase 2 trial (KEYNOTE-629) [103]. However, in this clinical trial the vast majority of patients have been pre-treated with chemotherapy and only a small subgroup was treatment-naïve. 105 locally advanced and metastatic CSCC patients have been included. The ORR was 34.3% including 3.8% complete responses. The median progression-free survival was 6.9 months, the median overall survival has not been reached. At 12 months 60.3% of the patients were still alive. The tolerability was very similar to the phase 2 trial on cemiplimab. The treatment discontinuation rate accounted for 12.1% [103]. Subsequent updates on KEYNOTE-629 [104,105] confirmed antitumor activity of pembrolizumab in both locally advanced and metastatic CSCC patients and demonstrated no unexpected new safety signals.

A phase 1 trial reported objective response rates of 47.4% with the PD-L1 antibody cosibelimab 800 mg every 2 weeks in 78 patients with metastatic CSCC. The median follow-up was 15.4 months. The only adverse event of grade 3 or higher that occurred in more than two patients was anemia (6.4%) [106]. Long-term efficacy and safety data of

Table 1
Cemiplimab for advanced CSCC. Final long-term analysis of groups 1, 2, and 3, and primary analysis of fixed-dose treatment group 6 (EMPOWER-CSCC-1 trial) [102].

	Group 1mCSCC 3 mg/kg Q2W (n = 59)	Group 2laCSCC 3 mg/kg Q2W (n = 78)	Group 3(mCSCC) 350 mg Q3W (n = 56)	Group 6 laCSCC and mCSCC 350 mg Q3W (n = 167)
Median FU, m	35	43	33	8.7
ORR, %	50.8	44.9	46.4	44.8
Complete response, %	20.3	12.8	19.6	5.5
Partial response, %	30.5	32.1	26.8	39.4
Stable disease, %	15.3	34.6	14.3	25.5
Progression of disease, %	16.9	12.8	25.0	13.9
DOR, median, m	NR	NR	41.3	NR
1-y estimate of DOR, % (95% CI)	89.5 (70.9–96.5)	83.9 (65.5–93.0)	88.5 (68.4–96.1)	80.2 (62.1–90.3)
Prior systemics	55.9%	15.4%	35.7%	3%
PFS, median, m	18.4	18.5	21.7	14.7
OS, median, m	57.7	NR	48.4	NR

CI: confidence intervals, DOR: duration of response (complete or partial), FU: follow-up, m: months, NR: not reached, OS: overall survival, PFS: progression-free survival, ORR: objective response rate, Q2W: every 2 weeks, Q3W: every 3 weeks

this trial (median follow-up of approximately 25 months)l in these 78 patients with mCSCC and 31 with laCSCC reported ORR of 50% and 54.8%, respectively [107].

An investigator-initiated single arm phase II trial on the use of the PD-1 inhibitor nivolumab included 31 patients, 19% with locally advanced-, 52% with locoregionally metastatic and 26% with distant metastatic disease. 22% of patients had received prior systemic therapies. This trial did also include 11 patients with concomitant hematological malignancies (CHM), mostly CLL. The investigator assessed ORR was 61.3% with 22.6% achieving a CR. Median PFS was 11.1 months and median OS was not reached for the whole study group at a median follow up of 23.8 months. In the group of patients with CHMs ORR was 45.5%, median PFS was 10.9 months and median OS was 20.7 months, indicating that PD-1 inhibition can also show robust activity in this group of patients. The most frequent AEs were pruritus, fatigue and rash, grade 3 adverse events were seen in 19.4% of patients. Although there was a numerical difference, no significant difference in AEs was seen between the group with or without CHM [108]. However, neither nivolumab nor pembrolizumab has been approved by EMA in Europe, However, pembrolizumab, cosibelimab and nivolumab have not been approved by EMA in Europe, whereas pembrolizumab is FDA-approved since June 2020 for recurrent or metastatic CSCC that is not curable by surgery or radiation and cosibelimab is FDA-approved since December 2024 for adults with locally advanced or metastatic CSCC who are not candidates for curative surgery or curative radiation. Thus, cemiplimab remains the only PD-1 inhibitor approved for advanced CSCC in Europe.

In a systematic review, Keeping et al., performed an indirect comparison on the efficacy of cemiplimab versus other systemic treatments for advanced CSCC in 11 studies (phase 2 study of cemiplimab NCT02760498 (n = 193), 7 studies on EGFRi, 2 trials on pembrolizumab, 1 trial on platinum chemotherapy [109]). In indirect comparison, cemiplimab versus EGFRi, was associated with benefits in OS (HR range: 0.07–0.47) and PFS (HR range: 0.30–0.67 in various studies). Cemiplimab was more efficacious in OS versus platinum-based chemotherapy (HR: 0.19, 95% CI: 0.10–0.39), while not statistically different in PFS (HR: 0.66, 95% CI: 0.38–1.16) [110]. Another systematic review and nonrandomized comparison analysis by Petzold et al., reported that ICB (cemiplimab, pembrolizumab, nivolumab) showed the highest median PFS (9.9 months [8.1–19.9]) and median OS (not reached, [95% CI: 31.5 months-not reached]), compared to chemotherapy (PFS: 3 months, OS 12.6 months), targeted therapy to EGF (PFS: 4.9 months, OS: 12.7 months), and combination therapies without ICB (PFS: 9.1 months, OS: 18.1 months). The survival benchmark with ICB after 26 months for metastatic CSCC was 70.8% (95% CI: 61.5–81.5) versus 17.1% (9.5–30.8) for chemotherapy and 37.9% (29.5–48.8) for the combination group [111].

Recommendation 9.
(updated from 2023)[97–104,106,107,112,113].

Immunotherapy for locally advanced or metastatic CSCC	Guideline 2026 Evidence-based recommendation
Grade of recommendation B	Patients with metastatic CSCC or locally advanced CSCC, who are not candidates for curative surgery or curative radiation, should receive first-line treatment with a PD-1/PD-L1 antibody*.
Level of evidence 2	Phase 1 and 2 study of cemiplimab. [97-102] Phase 1 and 2 of pembrolizumab. [103, 104, 112, 113] Phase 1 study of cosibelimab[106, 107]
	Strength of consensus: 96% (24 agree, 1 disagree)

* In Europe, cemiplimab is the only approved systemic medication, while pembrolizumab and cosibelimab are approved by US FDA.

5.2. EGFR inhibitors

Several EGFR inhibitors (EGFRi) have been evaluated in advanced CSCC, including monoclonal antibodies targeting the extracellular domain of EGFR (cetuximab, panitumumab) and small molecule tyrosine kinase inhibitors (TKI) (erlotinib, gefitinib, lapatinib and dacomitinib) [114]. Among these agents, cetuximab has been the most extensively investigated while evidence supporting the use of panitumumab, erlotinib, gefitinib, lapatinib, and dacomitinib remains very limited.

Cetuximab, in combination with RT or platinum-based chemotherapy, is approved for the treatment of locally advanced disease or metastatic head and neck SCC. In a prospective phase II trial, cetuximab showed efficacy as a first-line monotherapy for unresectable CSCC. At 6 weeks, the disease control rate (DCR) was 69% with an ORR of 28%. The median duration of disease control was 5 months, the median PFS was 4.1 months, and the mean OS was 8.1 months [115]. Prospective studies of treatment with EGFRi are detailed in Supplementary Table 2. Additional small trials and case series have evaluated cetuximab in the first-, second- and third-line settings, either as monotherapy (off-label) or in combination with RT or chemotherapy in patients with advanced CSCC [114–126] Combination regimens generally yielded higher ORRs compared with monotherapy. A recent systematic review and meta-analysis of 12 studies (six prospective and six retrospective) including 324 patients, assessed the overall efficacy of EGFRi in advanced CSCC. The pooled ORR was 26%, with a median PFS of 4.8 months, and median OS of 11.7 months. Efficacy outcomes were similar between anti-EGFR monoclonal antibodies and tyrosine kinase inhibitors [127].

EGFRi are generally better tolerated than standard cytotoxic agents. Most adverse events are cutaneous, dose-dependent and occur in aesthetically sensitive areas with a great impact on patient's quality of life. Common toxicities include a papulopustular/acneiform rash typically appearing within 1–2 weeks after treatment initiation, dry skin, pruritus and hand/nail toxicity [116]. In the meta-analysis by Pham et al., AEs of any grade were reported in 93% of patients while grade 3 and higher AEs occurred in 30% of patients [127].

More recently, cetuximab has been explored as a second-line therapeutic option to overcome resistance to immunotherapy and improve response rates in la/mCSCC. A retrospective single institution review suggested that cetuximab administered immediately after PD-1 progression was associated with higher and more durable overall responses

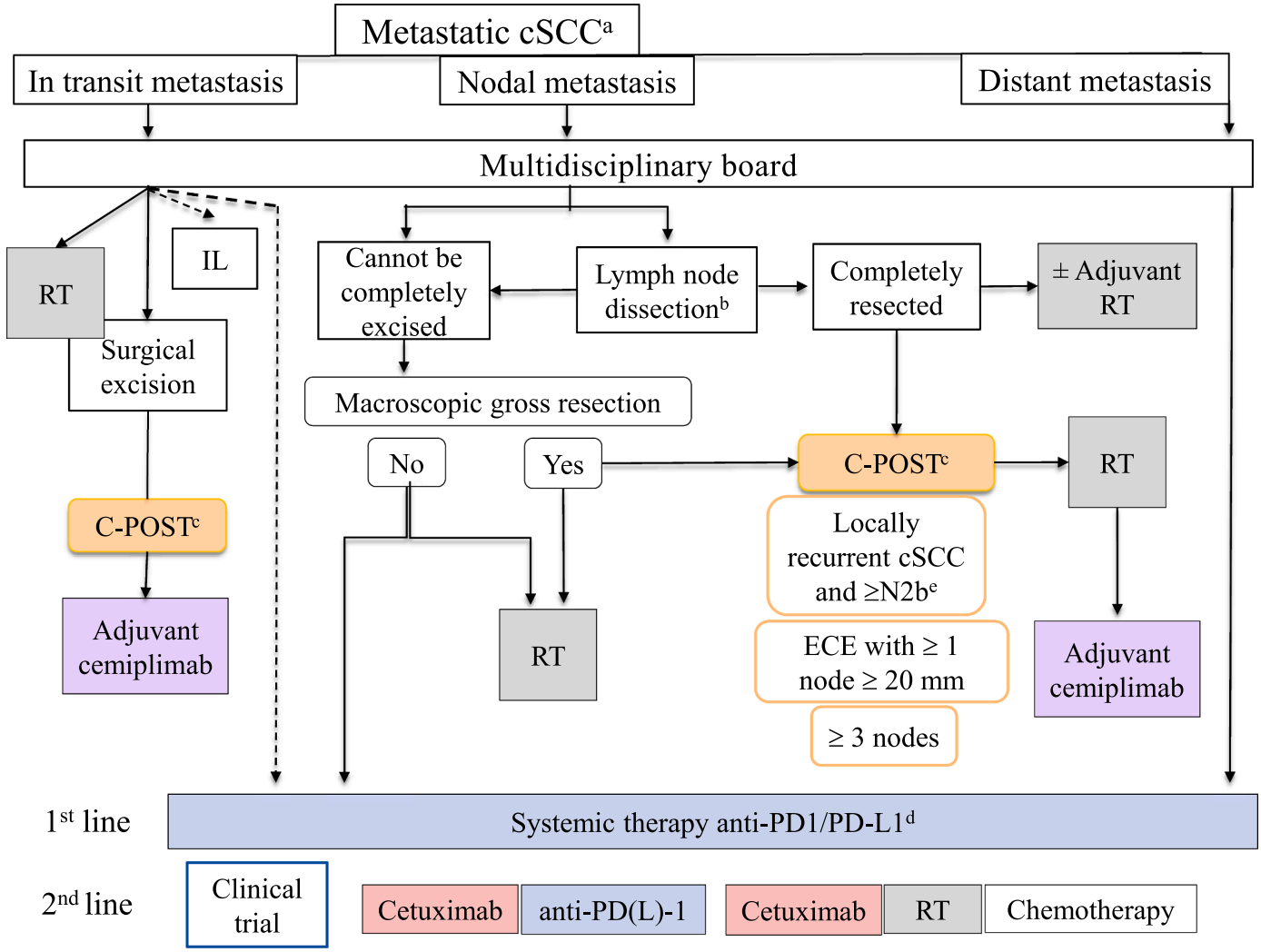

Fig. 2. Proposed treatment algorithm for patients with metastatic cSCC. Strength of consensus: 100%, [a] For detailed indications and recommendations of treatment, refer to relevant section text in the Guidelines. [b] Lymph node dissection as indicated, [c] In C-POST trial, criteria high risk of recurrence for metastatic CSCC included in-transit metastases, extracapsular extension in ≥ 1 node at least 20 mm in diameter, involvement of ≥ 3 nodes, local recurrence with ≥N2b. [d] All systemic treatments are off-label, except for anti-PD-1 agent cemiplimab that is approved by FDA/EMA for patients with locally advanced or metastatic cSCC who are not candidates for curative surgery or curative radiation, and pembroblizumab and cosibelimab that are approved by FDA. [e] AJCC8 stage ≥N2b: metastasis in a lymph node > 3 cm in greatest dimension with ECE, or > 6 cm without ECE, or in multiple lymph nodes. IL: intralesional treatments, ECE: extracapsular extension.

compared with historical data on cetuximab given prior to PD-1 blockade, without substantial differences in the toxicity profile [128]. These findings require confirmation in larger prospective studies. An ongoing clinical trial is currently investigating the role of anti-EGFR therapy with afatinib in patients who have failed immunotherapy (NCT05070403). Cetuximab may play a role in patients with advanced CSCC who have either contraindications to, or who progress on, first-line anti-PD1 immunotherapy (cemiplimab), favoring its combination with RT and/or immunotherapy (Figures 1, 2).

5.3. Systemic combination therapies

Approximately 50% of patients with advanced CSCC do not benefit from systemic therapy with cemiplimab, underscoring a substantial unmet medical need for additional treatment options in this population. EGFRi as monotherapy have shown only limited efficacy. More recently, several small clinical trials have investigated combinations of anti–PD-1 or anti–PD-L1 antibodies with the EGFRi cetuximab, either as sequential or upfront strategies in this clinical setting.

The Italian I-TACKLE phase II trial, an open-label study conducted across three centers, evaluated pembrolizumab (200 mg every 3 weeks) as a backbone regimen in patients with la/mCSCC [129] Cetuximab was added in non-responder patients, including those with stable disease or progression (n = 23). The cumulative ORR was 63%, with 19 of 43 (44%) patients responding to pembrolizumab alone and 8 of 21 (38%) responding to the combination after resistance. The median PFS was approximately 12 months. Grade 3–4 TRAEs occurred in 7 of 43 patients (16%) on pembrolizumab and 8 of 23 patients (35%) on the combination, with no unexpected toxicities reported. (Supplementary Table 3)

In a multicenter phase II trial, Becker et al. investigated the anti–PD-L1 antibody avelumab (10 mg/kg every 2 weeks) combined with cetuximab (500 mg/m^2 every 2 weeks) for up to 1 year in a heterogeneous cohort of 52 patients with advanced CSCC, either treatment-naïve or pretreated, including 18 with perianogenital tumors [130]. Twenty patients (41%) achieved an objective response (9 PRs and 11 CRs). Treatment-naïve patients (n = 35) demonstrated a higher ORR (46%) compared with pretreated patients (29%). Among 14 pretreated patients, 4 showed a response, including 2 previously exposed to PD-1 inhibition. Among the 18 peri anogenital cases, 36% responded, including 4 complete responses. At a median follow-up of 35 months, the median PFS was 8.4 months and median OS 23.1 months. Treatment was generally well tolerated, with grade 3 or higher AEs occurring in 20% of patients, consistent with the known safety profiles of the agents. (Supplementary Table 3)

Another randomized phase II trial (Alliance A091802) evaluated avelumab (800 mg IV every 2 weeks) plus cetuximab (500 mg/m^2 IV every 2 weeks) versus avelumab monotherapy for up to 2 years in 60 patients with metastatic or unresectable laCSCC, who were PD-1/PD-L1 inhibitor–naïve and had no prior cetuximab exposure [131]. Avelumab plus cetuximab significantly improved PFS compared with avelumab alone (median 11.1 vs 3.0 months; HR 0.48). Among the 9 patients who crossed over from avelumab monotherapy to the combination, median PFS was 11.3 months after crossover. Confirmed ORR was 27.6% with the combination versus 21.4% with monotherapy. Grade 3 TRAEs occurred in 48.3% and 21.5% of patients in the combination and monotherapy arms, respectively. (Supplementary Table 3)

Traditional chemotherapy remains of limited utility due to the short-lived, non-curative nature of responses as well as comorbidities and concomitant medications that often preclude intensive regimens. According to a systematic review of cisplatin-based regimens, the overall response rate was 45%, with a median DFS of 14.6 months [116]. Other exploratory strategies showing signals of activity in anti–PD-1–resistant disease included combinations with chemotherapy, electrochemotherapy, radiotherapy, and EGFR inhibition.

In summary, current evidence supports the use of an anti–PD-1/PD-L1 antibody combined with the EGFRi cetuximab in patients with CSCC resistant to anti–PD-1 monotherapy. However, therapeutic options for this patient population remain limited.

Recommendation 10.
(updated from 2023) [115,116,118–120,123–133].

EGFR inhibitors	Guideline 2026 Evidence-based recommendation
Grade of recommendation: C	Cetuximab may be considered for patients with locally advanced and metastatic CSCC who are contraindicated for or progress on first-line anti-PD1 immunotherapy, favoring its combination with RT and/or immune checkpoint inhibitors.
Level of evidence: 3	Small number of patients in prospective studies [115, 125] A small number of patients with metastatic CSCC treated [116, 118, 119, 125, 126, 132, 133] Only two prospective non-randomized study in small number of patients [123, 125] Small number of patients from retrospective studies [119, 120, 124, 126, 128, 133] Systematic review and meta-analysis [127] Small prospective clinical trials [129-131]
	Strength of consensus: 100%

5.4. Electrochemotherapy

Electrochemotherapy (ECT) exerts its anti-tumor effect through the ability of high-voltage electric pulses to increase the permeability (electroporation) of the cell membrane allowing intracellular access of chemotherapeutic drugs [134,135]. A large European study including 156 CSCC reported an ORR of 80% with CR in 63% of patients. The highest response rates were observed in tumors < 3 cm, suggesting that intravenous rather than intratumoral bleomycin administration should be preferred in larger lesions. Notably, previously irradiated lesions exhibited a markedly reduced CR rate [136]. In a series of 342 primary, recurrent or laCSCCs of 162 patients, local response was assessed using the RECIST criteria after 45–90 days of follow-up; CR was observed in 62% of patients, PR in 21%, SD in 11% and PD in 5%. Predictors of better outcome included a lesion size < 3 cm and intravenous bleomycin use. Side effects - as ulceration, suppuration, necrosis, flu-like symptoms, and nausea - were observed in 11% of patients. After a median follow-up of 5.6 months, recurrences occurred in 10% of patients and disease progression in 22%. Of the 16 patients who recurred after CR, 5 were successfully treated with additional ECT sessions [137]. Another study from the InspECT registry evaluated the ECT for skin cancers or cutaneous metastases in 61 elderly patients (>90 years), who represent a very frail population. After ECT, the objective response in patients > 90 years was comparable to that observed in younger patients. These elderly patients were managed with local/locoregional rather than general anesthesia [138].

ECT has been used in patients with laCSCC, or with persistent or recurrent primary CSCC lesions when other treatment options, including surgery and radiotherapy, failed or were not feasible, if the patient refused any other treatments, and as palliative care to relieve symptoms. Advantages of ECT consist of a favorable response, particularly in small (<3 cm) and non-ulcerated tumors [139], low toxicity, and preservation/improvement of quality of life. However, there is limited evidence on the duration of local control and progression-free survival, as a short follow-up is available.

6. Adjuvant systemic therapy

Despite many trials, apart from adjuvant radiotherapy, there has not been another effective adjuvant treatment for CSCC primary tumors with risk factors, or for loco-regional recurrences after standard R0 resection with clear surgical margins for many years [94,140–144]. In particular, adjuvant chemotherapies showed no benefits and therefore were not recommended at all in national or international guidelines. The situation has changed significantly since 2025, when two large-sized clinical trials on adjuvant therapies with PD1-antibodies data have released their (first) results.

In a phase 3, randomized trial ("C-POST") [145] 415 patients were enrolled with local or regional cutaneous squamous-cell carcinoma, after surgical resection and postoperative radiotherapy, at high risk for recurrence owing to nodal features (extracapsular extension with largest node ≥20 mm in diameter or at least three involved nodes) or non-nodal features (in-transit metastases, T4 lesion [with bone invasion], radiologic or clinical evidence of perineural invasion of named nerves, or locally recurrent tumor with ≥1 additional risk feature of ≥N2b, ≥T3 lesion, or poorly differentiated disease at least 20 mm in diameter. Patients were assigned in a 1:1 ratio to receive adjuvant cemiplimab (350 mg) or placebo, administered intravenously every 3 weeks for 12 weeks, followed by a dose increase to 700 mg administered every 6 weeks for up to 36 weeks (≤48 weeks total). The primary study end point was disease-free survival. Secondary end points included freedom from locoregional recurrence, freedom from distant recurrence, and safety. (Tables 2, 3)

The median follow-up was 24 months. Cemiplimab was superior to placebo with respect to disease-free survival (24 vs. 65 events; hazard ratio for disease recurrence or death, 0.32; 95% confidence interval [CI], 0.20–0.51; P < 0.001). The estimated 24-month disease-free survival was 87.1% (95% CI, 80.3–91.6) with cemiplimab and 64.1% (95% CI, 55.9–71.1) with placebo. Cemiplimab led to lower risks of locoregional recurrence (9 events, vs. 40 with placebo; hazard ratio, 0.20) and distant recurrence (10 vs. 26 events; hazard ratio, 0.35). Adverse events of grade 3 or higher occurred in 23.9% of the patients who received cemiplimab and in 14.2% of those who received placebo; discontinuation due to adverse events occurred in 9.8% and 1.5%, respectively [145]. FDA and EMA approval for the adjuvant treatment of adult patients with CSCC at high risk of recurrence following surgery and irradiation was granted in the fall of 2025 [146,147]. The C-POST trial is summarized in Tables 2 and 3.

Table 2
Summary characteristics of included patients in the phase 3, randomized C-POST trial: Adjuvant cemiplimab or placebo for adult patients with cutaneous squamous cell carcinoma at high risk of recurrence. Patients had completed both curative-intent surgery, with macroscopic gross resection of all disease and postoperative radiotherapy (or concurrent chemoradiotherapy) within 2–10 weeks before randomization. (Rischin et al. 2025) [145].

Characteristics	Adjuvant treatment arms	
	Cemiplimab	Placebo
N randomized (ITT)	209	206
Location of resected CSCCs, n (%)		
Head and neck	166 (79.4)	117 (56.8)
Non-head and neck	43 (20.6)	89 (43.2)
Definition of high-risk criteria, n (%)[a,b]		
Nodal		
a. ECE with ≥ 1 node ≥ 20 mm	105 (50.2)	96 (46.6)
b. ≥ 3 nodes	33 (15.8)	37 (18)
Nonnodal		
c. in-transit metastasesd.	20 (9.6)	21 (10.2)
d. clinical and/or radiologic involvement of named nerves	32 (15.3)	32 (15.5)
e. T4 (with bone invasion)	17 (8.1)	16 (7.8)
f. Local recurrence with at least one of:	55 (26.3)	50 (24.3)
• ≥N2b	17 (8.1)	13 (6.3)
• ≥T3 (diameter >4.0 cm or minor bone erosion or deep invasion >6 mm)	37 (17.7)	29 (14.1)
• poorly differentiated histology and ≥ 20 mm diameter	16 (7.7)	13 (6.3)
High-risk group[b]		
Nodal	125 (59.8)	117 (56.8)
Nonnodal	84 (40.2)	89 (43.2)
Median FU, m (range)	24 (2–64)	

ECE: extracapsular extension, ITT: intention-to-treat
[a] The total for the high-risk criteria is more than 100% because tumors could have more than one high-risk criterion.
[b] patients with both nodal and nonnodal disease were classified as having nodal disease.

Table 3
Summary results of efficacy and safety of the phase 3, randomized C-POST trial: Adjuvant cemiplimab or placebo for adult patients with cutaneous squamous cell carcinoma at high risk of recurrence after surgery and radiotherapy. (Rischin et al. 2025) [145].

Results	C-POST trial adjuvant treatment arms	
	Cemiplimab (n=209)	**Placebo (n=206)**
Primary endpoint: Disease-free survival		
Events, n *Recurrence* *Death*	24 18 6	65 61 4
DFS, HR (95% CI)	0.32 (0.20-0.51)	
Median DFS, m (95% CI)	NR	49.4 (48.5-NE)
Estimated probability of DFS, (95% CI) *At 12 m* *At 24 m*	 92.4 (87.5-95.5) 87.1 (80.3-91.6)	 69.5 (62.1-75.7) 64.1 (55.9-71.1)
Secondary endpoints		
Freedom from locoregional recurrence		
Events, n	9	40
HR (95% CI)	0.20 (0.09-O.40)	
Estimated probability, (95% CI) *At 12 m* *At 24 m*	 96.6 (92.5-98.5) 94.6 (89.1-97.3)	 79.1 (72.2-84.4) 76.7 (69.1-82.6)
Freedom from distant recurrence		
Events, n	10	26
HR (95% CI)	0.35 (0.17-0.72)	
Overall survival		
Deaths, n	12	13
HR (95% CI)	0.86 (0.39-1.90)	
Estimated probability, (95% CI) *At 12 m* *At 24 m*	 97.9 (94.4-99.2) 94.8 (89.6-97.4)	 98.3 (94.8-99.5) 92.3 (86.5-95.7)
Adverse events		
Treatment-emergent grade ≥ 3, n (%)	49 (23.9)	29 (14.2)
Treatment-related grade ≥ 3, n (%)	20 (9.8)	1 (0.5)
Immune-related AE, %	22.9	6.4
Immune-related AE grade ≥ 3, %	7.3	0
Discontinued due to AE, %	9.8	1.5
Death related to treatment, n	1	0

AE: adverse event, DFS: disease-free survival, defined as recurrence or death from any cause. CI: confidence intervals, NR: not reached, NE: not established

Conversely, the phase-3 KEYNOTE-630 study failed to show any statistically significant for DFS or DMFS improvement with adjuvant pembrolizumab versus placebo in a very similar study setting [147,148]. The reasons for the different study results ("C-POST" vs. "KEYNOTE-630") remain widely unclear. However, the study sponsor announced that the company is not applying for an approval of pembrolizumab in this adjuvant setting.

Recommendation 11.
Adjuvant systemic treatment.

Adjuvant systemic treatment	**Guideline 2026** **Evidence-based recommendation**
Grade of recommendation A	Adjuvant cemiplimab shall be offered for CSCC at high risk of recurrence after surgery and radiation therapy**.
Level of evidence 1	Phase 3, randomized C-POST trial [145]
	Strength of consensus: 100%

**C-POST criteria for high risk of recurrence. Nodal criteria: extracapsular extension with ≥ 1 node ≥ 20 mm, or ≥ 3 nodes regardless of extracapsular extension, or recurrent CSCC (that arises within the area of previously resected tumor) plus ≥N2b. Non-nodal criteria: In-transit metastases, clinical and/or radiologic involvement of named nerves, T4 lesions (invasion of cortical bone or skull base), or recurrent CSCC plus ≥T3 or poorly differentiated histology in recurrent lesion ≥ 20 mm diameter [145].

7. Neoadjuvant systemic therapy

Neoadjuvant therapy aims to reduce the size of a tumor prior to surgery, so that there is a smaller surgical defect and easier reconstruction. Ideally tumors disappear completely after neoadjuvant treatment without the need for subsequent treatment modalities like surgery or irradiation. Neoadjuvant systemic immunotherapy has been evaluated in prospective studies and phase 2 clinical trials in relatively small number of patients [59,149–153].

A pilot phase-2 study of neoadjuvant intravenous cemiplimab in 20 patients reported 70% complete or major pathological responses [154]. A larger phase-2, multicenter, non-randomized study in 79 patients with resectable stage II, III, or IV (M0) CSCC, evaluated neoadjuvant intravenous cemiplimab 350 mg every 3 weeks for up to 4 doses, before undergoing surgery with curative intent. A pathological complete response was observed in 40 patients (51%), and a pathological major response in 10 patients (13%). The second part of this study allowed for optional adjuvant cemiplimab therapy, adjuvant RT, or observation only [151].

A study update has been published after a median follow-up of 18.7 months for all 79 patients [152]. Among 70 patients who had surgery, 65 (93%) had post-surgical management data: 32 (49%) of 65 were observed postoperatively, 16 (25%) received adjuvant cemiplimab, and 17 (26%) received adjuvant radiotherapy. 11 (14%) of 79 patients had event-free survival events, with an estimated 12-month event-free survival of 89% (95% CI 79–94) for all patients. None of 40 patients who had a pathological complete response and one (10%) of ten patients with major pathological response had recurrence. Six (9%) of 70 patients who completed surgery had a disease-free survival event, with an estimated 12-month disease-free survival of 92% (95% CI 82–97). Nine (11%) of 79 patients died, with an estimated 12-month overall survival for all patients of 92% (95% CI 83–96). Four (25%) of 16 patients who received adjuvant cemiplimab treatment had grade 3 adverse events, including one (6%) who had increased blood potassium, one (6%) who had traumatic limb amputation, and two who had serious adverse events (one [6%] cardiomyopathy and one [6%] hypophysitis). There were no grade 4 adverse events or treatment-related deaths [152]. However, today it remains questionable if patients with a pathologically confirmed CR after cemiplimab need an adjuvant irradiation or systemic treatment at all.

The MATISSE phase 2, randomized trial included a total of 50 patients with stage I-Iva CSCC resectable with indication for extensive or disfiguring surgery, and evaluated only 2 doses of neoadjuvant nivolumab (3 mg/kg every 2 weeks) either alone or combined with one low-dose ipilimumab (1 mg/kg at day 0) (NIVO+IPI). At a median follow-up of 31 months, a major pathological response (MPR) was reached by 45% and 50% patients, respectively. A partial pathological response (PPR) was reached in 10% of patients with nivolumab alone and in 30% with NIVO+IPI. MPR or PPR was accompanied by 2-year disease-specific survival of 100%. Grade 3 immune-related adverse events occurred in 12% of nivolumab treated patients and in 8% of NIVO+IPI. Out of 10 patients who did not wish to undergo standard-of-care surgery, 9 patients had a complete clinical response and remained cancer free at a median follow-up of 31 months [153].

The issue of response-adapted interventions was addressed in a phase-2, multicenter study ("De-Squamate") [59] and evaluated pembrolizumab in patients with resectable stage II-IV (M0) CSCC. 27 patients received intravenous pembrolizumab, administered at a dose of 200 mg once every 3 weeks for four cycles, before undergoing an 18F-labeled fluorodeoxyglucose-positron emission tomography assessment. Patients who achieved a clinical complete response (cCR), defined as a complete metabolic response and negative mapping biopsies of the target site(s), avoided planned surgery and radiotherapy (total de-escalation). In the absence of a cCR, patients underwent surgery with the recommendation of omitting adjuvant radiotherapy (partial de-escalation) on the basis of a pCR. Patients proceeded to 13 additional cycles of maintenance pembrolizumab. The primary end point of a clinical or pathologic complete response (cpCR) was the combined rate of cCR and pCR. A cpCR was observed in 17 patients (63%), composed of a pCR in four (15%) and a cCR in 13 (48%). Total and partial de-escalation was achieved in 48% and 15%, respectively. With a median follow-up of 18 months, no recurrence was seen in those patients with a cpCR. Treatment-related AEs of grade ≥ 3 were observed in two patients (7%). Disease progression during neoadjuvant pembrolizumab occurred in one patient, which precluded surgery and resulted in death. In the conclusions the authors highlighted the potential to avoid surgery and radiotherapy with this treatment regimen [59].

Recommendation 12.
(new recommendation)[59,149–154].

Neoadjuvant systemic treatment	**Guideline 2026** **Evidence-based recommendation**
Grade of recommendation: C	Neoadjuvant immune checkpoint inhibitors may be offered as upfront treatment before definitive surgery for resectable, higher-risk CSCC primary tumors or loco-regional metastases (skin and/or lymph nodes) after a discussion in a multidisciplinary board.
Level of evidence: 3	Phase 2, uncontrolled trials [59, 151, 152, 154] Phase 2, randomized trial [153] Prospective studies [149, 150]
	Strength of consensus: 100%

8. Treatment for in-transit metastases

The presence of in-transit metastases is an independent factor associated with nodal metastasis and disease-specific death [155]. Patients with satellite or in-transit metastases have been shown to have recurrence rates and 5-year disease-specific survival rates comparable to those of patients with nodal metastases [156]. Satellite or in-transit metastases should be removed surgically if the number, size and location allow complete removal of the metastatic sites. According to a case series, adjuvant radiation therapy can be helpful in such cases [157]. For multiple unresectable metastases on the limbs, amputation used to be a common option, however currently it is no longer performed as it has no proven impact on the prognosis and several local and systemic alternatives are available to prevent mutilation [157]. In a retrospective, multicenter study including 77 patients with satellite/in-transit metastases, the most frequently used treatment was a combination of surgery and radiation therapy in 36.4% of patients [155]. Local options include radiotherapy, intralesional chemotherapy (5-fluorouracil, bleomycin or methotrexate), intralesional recombinant interferon alpha, electrochemotherapy or isolated limb perfusion [157–161]. Systemic options include oral retinoids, chemotherapy (platin-based regimens), EGFR inhibitors and anti-PD1 immunotherapy [157,158]. The only systemic drug approved for advanced CSCC is the anti-PD1 agent cemiplimab [97].

9. Treatment alternatives

9.1. Curettage & Electrodessication (C&E)

There are still no prospective studies comparing curettage alone or C&E with other modalities. In a retrospective series of 89 mostly well differentiated and smaller CSCC (mean pre-treatment size 0.9 cm) removed by curettage alone, Yakish et al reported an overall cure rate of 97% after a median follow-up of 6 years [162]. A systemic review and pooled analysis of observational studies on combined C&E reported low recurrence rates for small CSCC (<2 cm) [44], which was confirmed by a recent meta-analysis for *in situ* and invasive CSCC, studied together [163]. Updated NCCN guidelines 2026 state that C&E may be used for low-risk primary CSCC (based on NCCN risk stratification) and may have a lower cure rate than excision [12]. C&E (2 cycles) in experienced hands can be performed in small, low risk tumors, and in selected cases (patients with multiple CSCCs) but surgery is always to be preferred to this blind method.

9.2. Other destructive treatments: Cryosurgery, lasers, PDT

Also, cryosurgery, superficial skin ablation (laser, dermabrasion) or photodynamic therapy share the limitation of no histological control, raising concern for recurrences and potentially more difficult subsequent surgery. NCCN guidelines on CSCC list laser ablation among therapeutic options in field cancerization or actinic cheilitis[12], but there is no evidence to consider the use of lasers in invasive CSCC [44, 164]. PDT remains formally approved only for Bowen's disease (*in situ* CSCC), but there is inadequate evidence regarding its efficacy for invasive CSCC. Also, when used in field cancerization, the effect of PDT to prevent the development of new CSCC remains limited [165,166]. A systematic review and pooled analysis of observational studies reported low recurrence rates after cryotherapy but most CSCC included were small and low-risk tumors, and the quality of evidence was low [44].

Surgery should be discussed and considered with preference to any destructive and "blind" options.

Recommendation 13.
(same with recommendation 2023)

Destructive modalities	Guideline 2026
GPP	Destructive modalities such as ED & C, cryotherapy, PDT and lasers should not be performed in the treatment of primary invasive CSCC. Exceptions can be considered in small-sized and/or multiple CSCCs in low-risk areas where surgery and/or RT are not possible or have unacceptable consequences. Strength of consensus: 100%

9.3. Intralesional cytostatic drugs

Minimal invasive intralesional treatments could be alternatives in select patients for whom surgical excision is not acceptable and are entirely discussed in Section 10 "Intralesional therapies".

10. Intralesional therapies

Unlike melanoma, no intralesional therapy is currently approved for the treatment of resectable or locally advanced CSCC. Yet, both established agents and novel injectables have demonstrated certain clinical activity.

Intralesional methotrexate (MTX) has been evaluated in the treatment of primary tumors - keratoacanthomas and invasive CSCC - in numerous small studies with reported resolution rates of 71–100 % [167]. Recently, neoadjuvant MTX (two injections, one week apart) was investigated in a controlled prospective trial including 200 patients with CSCC. A pathological complete response was observed in 56% of patients alongside a significant reduction in the need for complex surgical construction after neoadjuvant MTX (15 vs. 40 %) [168]. 5-fluorouracil (5-FU) has also been investigated intralesional. The largest retrospective cohort study reported a resolution rate (of mostly invasive primary CSCCs) of 92% in 148 patients after use of 5FU in a 50mg/ml concentration and at a maximum dose of 150 mg. 24% of patients required more than one treatment to achieve resolution. In patients showing clinical resolution only 1 recurrence was reported [169].

Talimogene laherparepvec (T-VEC), a modified HSV-1 virus, showed promising efficacy in a recent small phase II trial (NCT03714828, n = 11). The objective response rate (ORR) was 100%, with 91% complete responses (CR) and 9 % partial responses (PR). Of 24 injected lesions, 96% responded completely. Median time to response was 35 days with a median duration of response of 209 days [170].

RP1, another HSV-1–based oncolytic virus is currently investigated in different scenarios. The CERPASS trial (NCT04050436) assessed RP1 with or without cemiplimab in 211 patients with locally advanced or metastatic CSCC. According to a press release in 2023 [171], the study did not meet either of the two primary endpoints complete or overall response rate. Of note, a complete response rate of 48.1% was observed in the RP1 plus cemiplimab group versus 22.6% in the cemiplimab only group. The ARTACUS trial (NCT04349436) is testing RP1 monotherapy in solid organ transplant recipients (SOTRs) with advanced skin cancers [172]. Interim data including 27 patients (24 with CSCC) showed a promising ORR of 34.8%, of which 21.7% were complete responses. RP1

is also studied in combination with nivolumab in advanced non-melanoma skin cancers (NCT03767348).

The PD-1 antibody Cemiplimab was tested as intralesional application in doses from 5 to 43.75 mg weekly in a phase I trial (NCT03889912). In 14 patients the rate of pathological complete remissions was 71.4%.

Several other intralesional agents are in early-phase clinical trials in different therapeutic settings as mono- or combination therapy but have either not yet reported data or only limited data in CSCC. These include cytokine-based injectables (fused L19IL2 and L19TNF (daromun): NCT04362722, NCT05329792), TLR-agonists (vidutolimod (TLR9): NCT04916002), CV8102: NCT03291002, TransCon-TLR 7/8 agonist: NCT04799054), various other virus-based products (T3011-HSV-1: NCT05602792, MEM-288 adenovirus: NCT05076760), TBio-6517 (vaccinia virus: NCT0430101), MQ710 (NCT05859074) and mRNA vaccines (SAR441000, NCT03871348).

Intralesional treatment of locally advanced CSCC cannot be routinely recommended due to limited evidence and lack of approval. Intralesional treatment may, however be considered as an individual treatment strategy in selected cases after discussion in an MDT.

11. Considerations of treatment in Immunocompromised patients

Immunocompromised patients including solid organ transplant recipients (OTRs), people with hematologic malignancies and hematopoietic stem cell transplants, people living with HIV (PLWH) and patients requiring chronic immunosuppressive drug treatment for immune mediated inflammatory disorders (e.g., inflammatory bowel disease, rheumatoid arthritis, psoriasis) are at increased risk for CSCC and generally have worse outcomes [173]. There is limited evidence from RCTs to guide management of these high-risk CSCC groups in immunocompromised patients. Close dialogue and multidisciplinary decision-making shared between patients, dermatologists, oncologists, surgeons, transplant clinicians and other relevant health care professionals is essential [174–177].

11.1. Primary CSCC

Given the increased risk, potentially atypical presentation and worse outcomes in immunocompromised patients, the clinical index of suspicion for CSCC should be high [174,178]. Confirmed CSCC is usually considered to be 'high risk' for the purposes of management decisions in immunocompromised patients (Stratigos 2026, Guideline part 1) [1]. However, two recently reported risk stratification tools have differed in whether immunocompromise is included as an independent risk factor predicting poor outcomes, with one finding it to be so [179], , whereas a second has not [180].

Staging investigations: Evidence for the utility of staging investigations such as sentinel lymph node biopsy is limited, but may be considered on a case-by case basis [177,181]. PET-CT may be useful in nodal staging of CSCC in patients with CLL [182].

Surgery: Optimal excision margins and the role of Mohs micrographic surgery (MMS)/intraoperative margin assessment are not proven in prospective RCTs, although frequently recommended [174,177, 183–185]. Few data exist on post-operative complications rates including infection and the need for prophylactic antibiotics, but this may be higher is immunocompromised patients [185,186].

Radiotherapy: although not usually first-line, particularly as immunocompromised patients are often younger and develop multiple primary CSCCs, radiotherapy nonetheless remains an option when surgery is not appropriate [183]

11.2. Locally advanced (laCSCC) and metastatic CSCC (mCSCC)

In advanced CSCC, there are specific considerations relevant to immunocompromised patients regarding use of checkpoint inhibitors, chemotherapy and EGFR inhibitors. Immunosuppression modification may also be considered, but there is no consensus on how this should be undertaken [174,183,187].

Pivotal clinical trials of anti-PD1 immune checkpoint inhibitor immunotherapy (ICI) excluded immunocompromised individuals and information on their safety and efficacy in these patients is restricted to case reports and retrospective series and a single phase I study [188–191]. No consensus guidelines exist for use of ICI in immunosuppressed patients, and this should be considered on a case-by-case basis in multidisciplinary consultation with the patient and their healthcare team. Key considerations include the high risk of allograft rejection in OTRs, the type of allograft and the options for replacement therapy should the allograft fail and the possibility that treatment efficacy may be reduced by immune compromise [192]. However, data from retrospective studies and meta-analyses as well as 3 phase I or II trials in organ transplant recipients, are providing increasing support for anti-PD1 therapy in OTRs, particularly in kidney transplant recipients for whom dialysis is possible in the event of graft loss and for whom it has been proposed that anti-PD1 therapy may be considered first [188–198]. The incidence of acute rejection and graft loss is around 23% and 18% respectively for CSCC in OTRs, with a 61% overall response rate at 1 year [188]. Maintenance immunosuppression may be held stable [190] or modified by both converting from calcineurin inhibitors to mTOR inhibitors with additional use of peri-infusional pulsed corticosteroids [191]. PD1 blockade for metastatic CSCC has also been reported in people living with HIV [199] and in patients with hematological malignancies, although in the latter group, disease control rates appear to be lower than in OTRs [200]. Further challenges for the future include understanding how to uncouple alloreactive immunity from anti-tumor immunity, biomarker identification for immunocompromised patients likely to benefit from ICI therapy and biomarkers for early detection of allograft rejection [192].

Regarding conventional chemotherapy, transplant-directed dosage adjustment, close monitoring of allograft function and potential drug interactions are important considerations [187]. Information on use of anti-EGFR inhibitors such as cetuximab is limited to case reports and small series [201–203]. Fatal pulmonary toxicity has been reported in lung transplant recipients treated with cetuximab [204].

11.3. Pre-transplant CSCC and re-transplantation after CSCC

Patients with a history of pre-transplant CSCC are increasingly common and consensus guidelines recommend that no waiting time is required for transplantation after a low-risk CSCC, 2–4 years for high-risk CSCC, and 5 yrars for CSCC with nodal metastasis. Transplantation was previously regarded as contraindicated for distant metastasis [174,205], although this approach may be revised given the rapidly changing therapeutic landscape [206]. Time to first post-transplant CSCC is shorter in OTRs with pre-transplant CSCC [207]

and for OTRs with a history of post-transplant CSCC being considered for re-transplantation, the increased risk of developing aggressive post-transplant CSCC also needs to be considered [208].

12. Best supportive care

Although treatment options continue to expand for CSCC, there is still a group of patients that cannot be cured and is often left with a growing, ulcerated tumor. Initially, palliative treatments like local surgery, RT or electrochemotherapy can be deployed to try to control tumor extension and relieve symptoms [209]. RT is often used to relieve pain, to stop hemorrhage and to try to confine tumor expansion in functional areas like the eye or the facial nerve [210]. Hypo-fractionated schemes (24–35 Gy in 3–6 fractions) or single dose (16–20 Gy) can be applied depending on the location of the tumor, the performance status (physical and mental fitness) of the patient [210,211].

If no further (palliative) treatments are desired or possible, the focus of care is on quality of life. The patient should be consulted about his/her individual wishes, needs and values. Supportive care includes wound care and pain management, nutritional and psychological support. Consultation with a palliative care team is advised [212].

Quality of life can seriously be affected by pain and should therefore be thoroughly tackled [213]. The ladder of the World Health Organization is a helpful tool for adequate pain management [214]. Paracetamol or non-steroidal anti-inflammatory drugs are first step pain relievers, followed by opioids. Application of morphine gel can be of help in smaller wounds [215,216].

To prevent malodor, the tumor should be rinsed daily with tap water or a disinfectant solution that contains sodium chloride solution of 0.9% or povidone iodine in a 2% or 10% solution [217]. Silver and honey dressings are effective in reducing malignant fungating wound discharge and malodor [218]. Topical metronidazole or oral metronidazole (250 mg, three times a day for 7–10 days) may also be considered [219]. Maceration of the surrounding skin of the tumor because of exudate can be prevented by applying zinc oxide paste or silicone gel on the surrounding skin. Slight bleeding can temporarily be stopped by application of calcium alginate dressings, dressings with xylometazoline or adrenaline (1:1000) or silver nitrate [219].

The Society of Integrative Oncology-ASCO guideline 2022 provided evidence-based recommendations on integrative approaches to managing pain in patients with cancer, including massage, acupuncture, reflexology or acupressure [220].

13. Follow-up

The prediction and identification of higher-risk CSCC patients that require strict surveillance are major issues in CSCC management due to the lack of clinically relevant biomarkers or a staging system with a reliable high predictive value [221,222]. A recent systematic review revealed significant inconsistency in the guidelines on follow-up of patients with CSCC and pointed towards the need of randomized clinical trials [223].

CSCC typically affects elderly patients with multiple co-morbidities, ECOG status commonly > 1 and often associated with multiple tumors at different stages in the progression of keratinocyte skin cancer. Thus, the aims of follow-up in this special cohort of geriatric-oncologic patients differ in some aspects from other types of cancers [6]. Certainly, aims of follow-up of patients affected by higher-risk CSCC included early detection of 1. recurrence (both locally and distant) and 2. secondary cancers as well as education of patients and relatives. In the post treatment situation, clinically and radiographic assessment is necessary to evaluate response and long-term side effects of medical treatment. However, it should additionally include the validation of the need of alternative, contemporary treatments especially for patients with severe field cancerization and multiple primary CSCCs or for OTRs [224,225]., and assessment of frailty, quality of life and life expectancy [226].

Risk assessment for local recurrence:

Based on current available literature, the highest risk for local and distant recurrence appears within the first 2 years after diagnosis of a primary CSCC [227,228]. First site of metastatic spread appears most frequently in the lymph node, thus follow-up should focus on this sites including clinical examination, and, depending on patient's risk profile, lymph node sonography and section imaging techniques. Special attention requires the cohort of patients with immunosuppression such as hematological co-morbidities or iatrogenic immunosuppression (OTR or others), who were reported to develop regional lymph node metastases in a mean of 6.7 months after diagnosis of the primary tumor [229].

Risk assessment for distant metastases:

In a large study evaluating 3455 tumors in 2522 patients, 116 (4.5%) patients developed nodal metastasis and 26 patients with nodal disease developed radiologically confirmed distant metastasis. The mean time to first nodal metastasis was 0.83 (1.29) and 0.98 (1.18) years, and 26 of 105 (24.8%) and eight of 26 (31%) patients were immunosuppressed. In total, 103 of 105 patients (98.1%) with nodal disease received therapy (surgery, radiotherapy and/or chemotherapy) aimed at treating nodal disease. Eighteen of 26 patients (69%) developed distant metastases following previously adjuvant treated isolated nodal disease surveillance, while eight of 26 (31%) had concomitant nodal and distant metastatic disease at follow-up, with subsequent confirmation of CSCC as the metastasis source [227].

Risk assessment for multiple tumors:

Patients with multiple CSCCs are at higher risk for nodal disease and local recurrence. Thus, patients with multiple tumors (> 2–10 tumors) would benefit form close surveillance programs, especially when associated with immunosuppression [230]. The development of new secondary primary CSCCs is a common problem, especially in high-risk patients. These include patients with field cancerization of the face, hands and capillitium as well as chronic immunosuppression. The aim here is to detect and treat secondary PEK at an early stage. Secondary prevention of PEK also includes early treatment of precursor lesions such as AK.

Risk assessment for immunocompromised patients:

Solid organ transplant recipients (SOTRs) have a 100-fold increased risk of squamous cell carcinoma (SCC), and they may develop more aggressive SCCs compared with immunocompetent individuals. It has been shown that close dermatological surveillance along with field related treatments may reduce an aggressive course of disease [231]. Further patients at high risk of further primary tumors are those with hematological comorbidities, genetic predisposition, previous multiple PEK.

In summary, the dilemma in providing clinically relevant and reliable evidence-based follow-up guidelines for CSCC are related to the lack of studies evaluating the heterogeneous characteristics of patients affected by CSCC.

Taking these metastatic patterns and time to first metastasis into account, patients should be followed up closely in the years 1–2 after primary diagnosis. This applies in particular to patients with a higher risk of recurrence, such as patients with immunosuppression, organ transplants and multiple tumors. Intensified follow-up care includes

Table 4
Consensus-based proposal for follow–up schedule for patients with history of CSCC proposed by EADO-EDF-ESTRO-UEMS-DV-EORTC. Follow-up will also depend based on individual symptoms and response to treatment. Consensus.

		Clinical/physical examination				Ultrasound of regional lymph nodes or parotid gland[1]				CT, MRI, PET/CT			
Year of follow-up		**1**	**2**	**3–5**	**6 +**	**1**	**2**	**3–5**	**6 +**	**1**	**2**	**3**	**4 +**
CSCC	**Low risk**	12 m	12 m	-	-	-	-	-	-	-	-	-	-
	With risk factor*	3–6 m	3–6 m	12 m**	12 m**	3–6 m	3–6 m	-	-	-	-	-	-
	laCSCC or mCSCC	3 m	3 m	3 m	6–12 m	3–6 m	3–6 m	3–6 m	6–12 m	3–6 m	3–6 m	3–6 m	Based on response
	IS* **	Every 3–6 m lifelong +according to the characteristics of CSCC				According to the characteristics of individual CSCC				According to the characteristics of individual CSCC			

laCSCC: locally advanced cutaneous squamous cell carcinoma, mCSCC: metastatic CSCC, IS: immunosuppressed, m: months, CT: computed tomography, MRI: magnetic resonance imaging, PET: positron emission tomography

* Risk factors as defined by EADO guidelines. As the independent prognostic effect of risk factors has not been consistently studied, an individual risk assessment is advised to guide follow-up decisions. The more the risk factors the higher the risk.

** based on individual risk factor profile

*** OTR, hematologic diseases associated with immunosuppression or genetic disorders prone to develop cSCC (xeroderma pigmentosum, dysplasia verruciformis)

[1] Lymph node ultrasonography should be performed in patients with a risk factor(s)*–or with unclear palpation findings and in cases of locally advanced and metastatic squamous cell carcinoma of the skin.

three-monthly check-ups, see Table 4. The individual follow-up examinations can be carried out using different diagnostic methods depending on the risk. If the risk decreases, the follow-up intervals can be extended beyond a 6-month interval up to 1-year intervals. Patients at low risk may not require long-term follow-up but should be instructed to seek immediate visit in the case of any new lesions or symptoms

Since the independent prognostic effect of high-risk factors has not been consistently reported, follow-up should be based on individual risk assessment and tumor- and patient-related characteristics, with special consideration for patients with more than one risk factor.

The optimal length of necessary follow-up has not been established, considering that follow-up aims include not only the early detection of local recurrence or metastasis but also of new primary skin cancers.

In addition, there is no solid evidence on the recommended follow-up procedures, highlighting a knowledge gap for further research. There is limited data on imaging for the follow-up of patients with CSCC and prospective studies are needed to determine best practices. Below is a synopsis of some evidence that assisted in the development of the guideline's consensus-based proposal for follow–up schedule for patients with a history of localized CSCC (Table 4):

When are poor outcomes expected to occur after the diagnosis of a localized CSCC?

- In a multicenter retrospective study of more than 23,000 CSCCs, at a mean follow-up of 3.8 years, there were 740 patients with a poor outcome and approximately 55% of recurrences, metastases, and deaths were detected within 1 year, 80% by 2 years, and 89% by 3 years. The authors concluded that the highest yield period for detection of CSCC recurrence is within the first 2 years and that the majority of poor outcomes occur by 3 years after primary treatment [228].
- A review of studies by Rowe et al., reported that 75% of local recurrences and metastases occur within 2 years after treatment and that 95% of local recurrences and metastases occur within 5 years after treatment. It was noted that the metastatic rate increases with the duration of patient follow-up [33].
- Most metastatic CSCCs are diagnosed within 2 years of the primary CSCC [232].

Which primary CSCCs are at risk for poor outcomes?

- CSCC with a risk factor has increased risk of nodal metastases, for example: 1.9-fold increased risk for thickness 6 mm or more, 2-fold increased risk for invasion beyond subcutaneous fat, 2-fold increased risk for size 2 cm or larger, 2.6-fold risk for poor differentiation, 2.7-fold risk for PNI, 2.8-fold risk for location on temple, as reported in meta-analyses [233,234].
- The risk is further modified by the number of risk factors present, as reported in the Brigham and Women's Hospital (BWH) classification system. In BWH classification, high-stage CSCC (T2b/T3, with 2–4 risk factors present) accounted for 70% of nodal metastasis [235]. Among VWH T2b tumors (with 2–3 risk factors), those with 3 risk factors represent a higher risk subset for local recurrence, nodal metastasis and disease-specific death [236].

Imaging for follow-up of patients with CSCC with risk factors

- Imaging in high-stage CSCC altered management in 33% of patients [237].
- Detection of subclinical disease achieved with baseline and surveillance imaging in CSCC with risk factors [238].

This study offered patients with high-stage CSCC imaging at baseline and then every 4–6 months for 2 years.

The authors reported that a majority (56%) of detections were not seen initially but rather during surveillance imaging in the 2 years post treatment. In the follow-up imaging cohort, imaging identified nodal metastasis that was not palpable on clinical examination in 19% of patients [238].

- For patients without clinical lymphadenopathy, it was suggested that preoperative nodal staging with ultrasonography may be more useful than CT or MRI [239].
- Early detection and management of nodal metastasis may identify patients with CSCC at high risk for recurrence eligible for adjuvant cemiplimab [145].

Recommendation 14.
Follow-up (same with recommendation 2023).

	Guideline 2026Consensus-based recommendation
GPP	• CSCC patients shall be followed-up for recurrences and development of new NMSC and melanoma. • Follow-up in all patients shall include regular clinical examination, including inspection of the entire skin and inspection and palpation of the excision site, the in-transit route and the regional lymph nodes, and advice on self-skin examination. • Frequency of follow-up visits and imaging depend on underlying risk characteristics for CSCC patient: low-risk or higher-risk common primary, advanced or regional disease, immunosuppression setting (detailed in Table 4). Strength of consensus: 100%

14. Communication with the patient

When diagnosing common primary CSCC, the clinician will need to give information about the type of CSCC diagnosed and the risk of relapse or metastasis. Patients should be reminded that most CSCCs are well-differentiated tumors which have a low risk of recurrence and/or metastases. For well differentiated tumors which represent more than 80% of the tumors, the risk of local recurrence is around 2 % and the risk of nodal metastases is also 2–5%. Patients may need support from clinical nurse specialists in case of disfiguring surgery or the delivery of bad news and need to be offered access to support services when deemed necessary. Self-examination should be discussed for the diagnosis of new primaries and detection of lymph nodes in the draining basins.

Patients with CSCCs should also be informed of different treatment modalities and these need to be discussed when appropriate with the patient/family/caregiver. Considering that the median age of CSCCs is 80 years, it is important to give patient's choice about modalities of treatment and avoid surgery with high morbidity if the tumor is not high risk. The potential consequences of foregoing treatment should also be explained. Patients should be made aware that radiotherapy may not be the best treatment option in young age groups as radiotherapy scars could worsen over time and there is a risk of secondary malignancies, although it is very low.

Surgery for high-risk tumors should not be less than optimal in elderly patients as the consequences of not offering optimal treatments in a timely manner may lead to difficult tumors to manage with subsequent morbidity and possible impact on mortality. However, it is important to consider the patient's morbidities and treatments options should always be discussed with the patient, their family or carers even after multi-disciplinary discussions.

An information leaflet should be provided giving facts about CSCCs and that these tumors are the second most commons skin cancer after basal cell carcinomas. Risk factors should be explained such as high levels of chronic sun exposure, genetic and host factors such as fair skin, immunosuppression, or the presence of syndromes with increased susceptibility to skin cancers such as xeroderma pigmentosum and albinism. In patients with CSCCs and family history of uterus and/or bowel cancer, clinicians should discuss genetic counselling and testing for DNA mismatch repair genes to rule out Lynch or Hereditary Non-Polyposis Colon Cancer (HNPCC) syndrome. If the gene mutation is confirmed, the patient and their family will be offered colon and uterus cancer screening and it is important that these patients are managed by cancer geneticists and other specialists.

Patients may have different types of follow-up schedules depending on age, location of tumor, histological subtype, previous primaries, recurrences and other host factors such as immunosuppression. The risk of recurrence should be discussed taking account of the tumor characteristics and other risk factors. Patients should be advised how to perform self-examination. For immunosuppressed patients, it is recommended that patients are followed up for life, ideally in dedicated clinics with experience in the management of these complex patients. Patients will also need advice about sun protection and how to use treatments for field cancerization at home with topical products if appropriate.

A qualitative study looked at the needs and preferences of patients with CSCC regarding treatment and follow-up care: patients mentioned that clear information on self-inspection would reduce the need for follow-up visits and that they wished information preferably on paper. Patients preferred periodic follow-up visits with a possibility to come in-between visits in case of suspicious new lesions and believed it was too hard to self-detect cancer or make self-skin examination of the whole body [240].

Summarizing box of recommendations

Practice points	Recommendation	GOR
1. Surgical excision of primary CSCC	Surgical excision with histological control shall be performed as standard treatment. The aim of CSCC surgery shall be a complete excision (R0) with histological confirmation of peripheral and deep excision margins. Large tumors or tumors on the head and neck can undergo a punch or incisional biopsy for histological confirmation and planning of a subsequent complete excision. In case of positive margins, a re-excision shall be done, for operable cases.	A
2. Surgery and safety margins	Low-risk CSCC should be excised with a clinical safety margin of 4-6 mm. CSCC with risk factors should be excised with a clinical safety margin of $\geq$ 6 up to 10 mm whenever possible or by micrographically controlled surgery. Micrographically controlled surgery should be considered for CSCC in functional/cosmetical sensitive areas.	B
3. Wound closure	As long as an R0 resection is not histologically confirmed, wound closure with local tissue movements (flaps) should be avoided.	GPP
4. Therapeutic lymph node dissection	The need and extent of surgical resection/lymph node dissection is determined by the surgeon in collaboration with the multidisciplinary tumor board. For patients with macroscopic regional lymph node metastases, individualized treatment should be discussed in the multidisciplinary tumor board.	B
5. Definitive primary RT	Primary radiotherapy should be considered for inoperable or difficult-to-operate tumors or in patients not amenable to surgery.	B
6. Post-operative RT	Post-operative radiotherapy should be considered after surgical excision for CSCC with positive margins and for which re-excision with clear margins is not possible.	B
7. Adjuvant RT for resected nodal metastatic CSCC	Adjuvant radiotherapy following therapeutic lymphadenectomy, should be considered in CSCC of the head and neck with regional nodal metastases and extracapsular extension.	B
8. Adjuvant RT for CSCC with risk factors	Adjuvant radiotherapy may be discussed for CSCC with multiple risk factors (BWH T2b/T3) and with clear surgical margins.	C
9. Immunotherapy for advanced CSCC	Patients with metastatic CSCC or locally advanced CSCC, who are not candidates for curative surgery or curative radiation, should receive first-line treatment with a PD-1/PD-L1 antibody*.	B
10. EGFR inhibitors	Cetuximab may be considered for patients with locally advanced and metastatic CSCC who are contraindicated for or progress on first-line anti-PD1 immunotherapy, favoring its combination with RT and/or immune checkpoint inhibitors.	C

(*continued on next page*)

Summarizing box of recommendations (*continued*)

11. Adjuvant systemic therapy	Adjuvant cemiplimab shall be offered for CSCC at high risk of recurrence after surgery and radiation therapy**.	A
12. Neoadjuvant systemic treatment	Neoadjuvant immune checkpoint inhibitors may be offered as upfront treatment before definitive surgery for resectable, higher-risk CSCC primary tumors or loco-regional metastases (skin and/or lymph nodes) after discussion in a multidisciplinary board.	C
13. Destructive modalities for CSCC	Destructive modalities such as ED & C, cryotherapy, PDT and lasers should not be performed in the treatment of primary invasive CSCC. Exceptions can be considered in small-sized and/or multiple CSCCs in low-risk areas where surgery and/or RT are not possible or have unacceptable consequences.	GPP
14. Follow-up	CSCC patients shall be followed-up for recurrences and development of new NMSC and melanoma. Follow-up in all patients shall include regular clinical examination, including inspection of the entire skin and inspection and palpation of the excision site, the in-transit route and the regional lymph nodes, and advice on self-skin examination. Frequency of follow-up visits and imaging depend on underlying risk characteristics for CSCC patient: low-risk or higher-risk common primary, advanced or regional disease, immunosuppression setting (detailed in Table 4).	GPP

GOR: grade of recommendation, GPP: good practice point, NMSC: nonmelanoma skin cancer* In Europe, cemiplimab is currently the only approved systemic medication, while pembrolizumab and cosibelimab are approved by US FDA.** C-POST criteria for high risk of recurrence. Nodal criteria: extracapsular extension with $\geq$ 1 node $\geq$ 20 mm, or $\geq$ 3 nodes regardless of extracapsular extension, or recurrent CSCC (that arises within the area of previously resected tumor) plus $\geq$N2b. Non-nodal criteria: In-transit metastases, clinical and/or radiologic involvement of named nerves, T4 lesions (invasion of cortical bone or skull base), or recurrent CSCC plus $\geq$T3 or poorly differentiated histology in recurrent lesion $\geq$ 20 mm diameter [145].

Funding

The development of the current set of guidelines was supported solely by funds of the EADO which were used to mainly support the consensus meeting without honoraria and without reimbursement of travel costs.

Declaration

The author Alexander Eggermont is an Editor of the EJC and was not involved in the editorial review or the decision to publish this article.

Declaration of Competing Interest

The authors declare the following financial interests/personal relationships which may be considered as potential competing interests:

Alexander J. Stratigos: reports a relationship with Regeneron Pharmaceuticals Inc that includes: consulting or advisory, and lecture fees. Alexandros Stratigos reports a relationship with Replimune Ltd that includes: lecture fees. Alexandros Stratigos reports a relationship with Merck & Co Inc that includes: funding grants. Alexandros Stratigos reports a relationship with Genesis Pharma that includes: funding grants. Alexandros Stratigos reports a relationship with L' Oreal that includes: funding grants.

Clio Dessinioti: None

Claus Garbe reports receipt of honoraria or consultation fees: personal fees from CeCaVa, from MSD, from NeraCare, and from Philogen.

Celeste Lebbe: reports research grants (Pierre Fabre, Novartis), participation at advisory board meetings (Pierre Fabre, Regeneron, MSD, BMS)

Teresa Amaral: reports personal fees for advisory board membership from Delcath and Philogen; personal fees as an invited speaker from Bristol Myers Squibb (BMS), Medscape, Neracare, Novartis and Pierre Fabre; personal fees for a writing engagement from CeCaVa and Medtrix; institutional fees as local principal investigator (PI) from Agenus Inc., AstraZeneca, BioNTech, BMS, HUYA Bioscience, Immunocore, IO Biotech, MSD, Pfizer, Philogen, Regeneron, Roche and University Hospital Essen; institutional fees as coordinating PI from Unicancer; institutional research grants from iFIT and Novartis; institutional funding from MNI - Naturwissenschaftliches und Medizinisches Institut, Neracare, Novartis, Pascoe, Sanofi and Skyline-Dx; non-remunerated membership of the American Society of Clinical Oncology (ASCO) and the Portuguese Society for Medical Oncology; a role as clinical expert in the area of medical oncology for Infarmed, and a role as an expert for SGA-Oncology at EMA outside the submitted work.

Veronique Bataille: None

Brigitte Dreno: None

Reinhard Dummer has intermittent, project focused consulting and/or advisory relationships with Novartis, Merck Sharp & Dhome (MSD), Bristol-Myers Squibb (BMS), Roche, Amgen, Takeda, Pierre Fabre, Sun Pharma, Sanofi, Catalym, Second Genome, Regeneron, T3 Pharma, MaxiVAX SA, Pfizer, Simcere and Iovance outside the submitted work. Senior medical advisor Oncobit. Participation on Derma2go.

Maria Concetta Fargnoli reports a relationship with MSD Italy that includes: consulting or advisory and speaking and lecture fees.

Ana Maria Forsea: None

Christoph Gebhardt: Research support by BMS, Delcath, Novartis, Pierre-Fabre, Regeneron and Sanofi, member of the advisory board of Almirall, Beiersdorf, BioNTech, BMS, Delcath, ImCheck, Immatics, Immunocore, Moderna, MSD, Novartis, Pierre-Fabre, Regeneron, Sanofi, SUN Pharma, SkylineDx, honoraria by Almirall, Bioderma, Biofrontera, BMS, Delcath, Immunocore, Medscape, MSD, Novartis, Onkowissen, Pierre-Fabre, Regeneron, Sanofi, SUN Pharma, SkylineDx, travel expenses by BMS, Pierre-Fabre, SUN Pharma, and Co-Founder of Dermagnostix and Dermagnostix R&D.

Catherine A. Harwood: None

Axel Hauschild: reports personal fees for advisory board membership from Agenus, BMS, Dermagnostix, Eisai, Highlight Therapeutics, Immunocore, Incyte, IO Biotech, Merck Pfizer, MSD, Neracare, Novartis, Philogen, Pierre Fabre, Regeneron, Replimune, Roche, Sanofi, Seagen, Xenthera; institutional funding as local or coordinating PI from Agenus, Amgen, BMS, MSD, Novartis, Philogen, Pierre Fabre and Regeneron.

Christoph Hoeller: none

Lidija Kandolf-Sekulovic none

Roland Kaufmann: Institutional research grants (clinical trials) from AbbVie, Almirall, Amgen, Astra Zeneca, Biontech, BMS, Fraunhofer Institute, Galderma, Incyte, Janssen, Leo, Lilly, Merck, MSD, Novartis, Pfizer, Regeneron, Roche, Advisory Board and Honoraria from Leo and Regeneron

Nicole WJ Kelleners-Smeets: None

Peter Koelblinger: reports a relationship with Bristol-Myers Squibb Company that includes: consulting or advisory, paid expert testimony, speaking and lecture fees, and travel reimbursement. Peter Koelblinger reports a relationship with MSD Merck Sharp & Dohme AG that includes: consulting or advisory and speaking and lecture fees. Peter Koelblinger reports a relationship with Pierre Fabre SA that includes: speaking and lecture fees and travel reimbursement. Peter Koelblinger reports a relationship with Immunocore Ireland Limited that includes: speaking and lecture fees.

Aimilios Lallas: Institutional research grants (clinical trials) from AbbVie, BMS, Incyte, Lilly, Merck, MSD, Regeneron, Advisory Board and Honoraria from Fotofinder, Lilly and Regeneron

Ulrike Leiter reports a relationship with Regeneron Pharmaceuticals Inc that includes: consulting or advisory, funding grants, and speaking and lecture fees. Ulrike Leiter reports a relationship with Sun Pharmaceutical Industries Ltd that includes: consulting or advisory, speaking and lecture fees, and travel reimbursement. Ulrike Leiter reports a relationship with Pierre Fabre Médicament SAS that includes: consulting or advisory, speaking and lecture fees, and travel reimbursement. Ulrike Leiter reports a relationship with Almirall Hermal GmbH that includes: consulting or advisory and speaking and lecture fees.

Konstantinos Liopyris: none

Veronique del Marmol: none

David Moreno-Ramirez: none

Giovanni Pellacani: none

Ketty Peris: reports research grants (Sanofi, Novartis, Abbvie, Almirall), participation at advisory board meetings (Almirall, Lilly, Novartis, Sun-Pharma, Leo-Pharma, Philogen, Pierre Fabre, Regeneron, Sanofi, Sun Pharma, UCB)

Philippe Saiag: reports a relationship with Merck Sharp & Dohme Corp that includes: board membership and travel reimbursement. Philippe Saiag reports a relationship with Regeneron Pharmaceuticals Inc that includes: board membership and travel reimbursement. Philippe Saiag reports a relationship with Bristol-Myers Squibb Company that includes:.

Luca Tagliaferri: reports a relationship with Elekta that includes: funding grants and speaking and lecture fees. Luca Tagliaferri reports a relationship with IGEA SpA that includes: funding grants and travel reimbursement. Luca Tagliaferri reports a relationship with Sun Pharmaceutical Industries Ltd that includes: consulting or advisory, non-financial support, speaking and lecture fees, and travel reimbursement. Luca Tagliaferri reports a relationship with Sanofi that includes: speaking and lecture fees and travel reimbursement. Luca Tagliaferri reports a relationship with Roche that includes: speaking and lecture fees. Luca Tagliaferri reports a relationship with Nanobiotix SA that includes: consulting or advisory. Luca Tagliaferri reports a relationship with Novartis that includes: consulting or advisory, funding grants, and travel reimbursement. Luca Tagliaferri reports a relationship with Eisai Inc that includes: consulting or advisory, speaking and lecture fees, and travel reimbursement. Luca Tagliaferri reports a relationship with Bayer Corporation that includes: consulting or advisory and funding grants. Luca Tagliaferri reports a relationship with Boston Scientific Corporation that includes: funding grants. Luca Tagliaferri reports a relationship with Ipsen Pharma SAS that includes: consulting or advisory and funding grants. Luca Tagliaferri reports a relationship with Pfizer that includes: consulting or advisory, funding grants, and speaking and lecture fees. Luca Tagliaferri reports a relationship with Regeneron Pharmaceuticals Inc that includes: consulting or advisory, speaking and lecture fees, and travel reimbursement. Luca Tagliaferri reports a relationship with MSD Italy that includes: consulting or advisory and funding grants. Luca Tagliaferri reports a relationship with AstraZeneca that includes: consulting or advisory and funding grants. Luca Tagliaferri reports a relationship with Johnson and Johnson that includes: funding grants, speaking and lecture fees, and travel reimbursement. Luca Tagliaferri reports a relationship with Astellas Pharma Inc that includes: funding grants, speaking and lecture fees, and travel reimbursement. Luca Tagliaferri has patent TIMER applicator licensed to 102017000067474.

Myrto Trakatelli: reports a relationship with Janssen, UCB, Abbvie, Genesis Pharma, Pierre Farbre Greece, EADV courses that includes: speaking and lecture fees and travel reimbursement.

Ricardo Vieira: none

Iris Zalaudek: none

Petr Arenberger: none

Alexander C.J. van Akkooi: reports a relationship with Adium Pharma SA that includes: speaking and lecture fees. Alexander C.J. van Akkooi reports a relationship with Bristol-Myers Squibb that includes: consulting or advisory and speaking and lecture fees. Alexander C.J. van Akkooi reports a relationship with Daiichi Sankyo Inc that includes: consulting or advisory. Alexander C.J. van Akkooi reports a relationship with Genmab BV that includes: consulting or advisory. Alexander C.J. van Akkooi reports a relationship with Menarini Silicon Biosystems Inc that includes: consulting or advisory. Alexander C.J. van Akkooi reports a relationship with MSD Merck Sharp & Dohme AG that includes: consulting or advisory and speaking and lecture fees. Alexander C.J. van Akkooi reports a relationship with NeraCare GmbH that includes: consulting or advisory. Alexander C.J. van Akkooi reports a relationship with Novartis that includes: speaking and lecture fees. Alexander C.J. van Akkooi reports a relationship with Pierre Fabre SA that includes: consulting or advisory and speaking and lecture fees. Alexander C.J. van Akkooi reports a relationship with Regeneron Pharmaceuticals Inc that includes: consulting or advisory and speaking and lecture fees. Alexander C.J. van Akkooi reports a relationship with Replimune Ltd that includes: consulting or advisory and speaking and lecture fees. Alexander C.J. van Akkooi reports a relationship with Sirius Medical Systems BV that includes: consulting or advisory and speaking and lecture fees. Alexander C.J. van Akkooi reports a relationship with SkylineDx BV that includes: consulting or advisory, funding grants, and speaking and lecture fees. NHMRC Clinical Trials and Cohort Studies Grant 2043780 for the MSLT-3 trial.

Alexander M. M Eggermont reports stock and other ownership interests - IO Biotech, Sairopa B.V., SkylineDx B.V.; Honoraria Consulting or Scientific Advisory Role - Agenus, Boehringer Ingelheim GmbH, BioInvent, BioNTech, Brenus, CatalYm GmbH, Cryptomedix, EBT-Phamaceuticals, Egle, ImmTech, Eurobio, IO Biotech, IQVIA, Merck KgA, Merck&Co, Moderna, MSD, Oncolytics, Pierre Fabre, QBiotics, Regeneron, Sairopa BV, Secarna GmbH, SkylineDx BV, Thermosome GmbH, Trained Immunity Therapeutics Discovery; Vector Sciences. Data safety monitoring board: BioNTech, IQVIA, Pfizer.

Paul Lorigan reports funding for research: Pierre Fabre and BMS, and personal fees for advisory board and speakers bureau: Regeneron, Pierre Fabre, BMS, MSD, Iovance, MLA Diagnostics.

Mario Mandala reports financial support was provided by University of Perugia Department of Medicine. Mario Mandala reports a relationship with University of Perugia Department of Medicine that includes: non-financial support. Mario Mandala has patent not applicable pending to not applicable. The Co-author is employed at the University of Perugia as Professor and there are no competing interest that have been used to complete the present project.

Josep Malvehy reports a relationship with Regeneron Pharmaceuticals Inc that includes: consulting or advisory and travel reimbursement. Josep Malvehy reports a relationship with Sunpharma that includes: consulting or advisory, speaking and lecture fees, and travel reimbursement.

Appendix A. Supporting information

Supplementary data associated with this article can be found in the online version at doi:10.1016/j.ejca.2026.116764.

References

[1] Keohane SG, Botting J, Budny PG, Dolan OM, Fife K, Harwood CA, et al. British Association of Dermatologists guidelines for the management of people with cutaneous squamous cell carcinoma 2020. Br J Dermatol 2021;184:401–14.

[2] Dessinioti C, Platsidaki E, Stratigos AJ. A Sensitivity Meta-Analysis of Disease-Specific Death in Localized Cutaneous Squamous Cell Carcinoma. Dermatology 2022;238:1026–35.

[3] Leus AJG, Frie M, Haisma MS, Terra JB, Plaat BEC, Steenbakkers R, et al. Treatment of keratinocyte carcinoma in elderly patients - a review of the current literature. J Eur Acad Dermatol Venereol 2020;34:1932–43.

[4] Baggi A, Quaglino P, Rubatto M, Depenni R, Guida M, Ascierto PA, et al. Real world data of cemiplimab in locally advanced and metastatic cutaneous squamous cell carcinoma. Eur J Cancer 2021;157:250–8.

[5] Strippoli S, Fanizzi A, Quaresmini D, Nardone A, Armenio A, Figliuolo F, et al. Cemiplimab in an Elderly Frail Population of Patients With Locally Advanced or Metastatic Cutaneous Squamous Cell Carcinoma: A Single-Center Real-Life Experience From Italy. Front Oncol 2021;11:686308.

[6] Samaran Q, Samaran R, Ferreira E, Haddad N, Fottorino A, Maillard H, et al. Anti-PD-1 for the treatment of advanced cutaneous squamous cell carcinoma in elderly patients: a French multicenter retrospective survey. J Cancer Res Clin Oncol 2023;149:3549–62.

[7] Breuninger H, Eigentler T, Hafner HM, Leiter U. Local surgical treatment of cutaneous squamous cell carcinoma: deficits and controversies in the literature. J der Dtsch Dermatol Ges = J Ger Soc Dermatol JDDG 2019;17:999–1004.

[8] van Delft LCJ, Nelemans PJ, van, Loo E, Abdul Hamid M, Kelleners-Smeets NWJ. The illusion of conventional histological resection margin control. Br J Dermatol 2019;180:1240–1.

[9] Alam M, Armstrong A, Baum C, Bordeaux J, Brown M, Busam K, et al. Guidelines of care for the management of cutaneous squamous cell carcinoma. J Am Acad Dermatol 2018;78:560–78.

[10] Munoz Couselo E, Canueto J, Jerviz Guia V, Lopez Lopez AM, Bermejo Segu JO, Garcia Castano A, et al. Recommendations for the management of cutaneous squamous cell carcinoma: a systematic multidisciplinary Delphi consensus approach. Clin Transl Oncol 2025;27:3058–72.

[11] Stewart TJ, Saunders A. Risk factors for positive margins after wide local excision of cutaneous squamous cell carcinoma. J Dermatol Treat 2018;29:706–8.

[12] Bordeaux J, Nghiem P, Aasi SZ, Alam M, Amini A, Bolotin D, et al. National Comprehensive Cancer Network (NCCN) Clinical Practice Guidelines Oncology. Squamous cell skin cancer 2026;Version 1. ⟨https://www.nccn.org/professionals/physician_gls/pdf/squamous.pdf⟩. Accessed on October 8, 2025. 2026.

[13] Leiter U, Heppt MV, Steeb T, Amaral T, Bauer A, Becker JC, et al. S3 guideline for actinic keratosis and cutaneous squamous cell carcinoma (cSCC) - short version, part 2: epidemiology, surgical and systemic treatment of cSCC, follow-up, prevention and occupational disease. J der Dtsch Dermatol Ges = J Ger Soc Dermatol JDDG 2020;18:400–13.

[14] Motaparthi K, Kapil JP, Velazquez EF. Cutaneous Squamous Cell Carcinoma: Review of the Eighth Edition of the American Joint Committee on Cancer Staging Guidelines, Prognostic Factors, and Histopathologic Variants. Adv Anat Pathol 2017;24:171–94.

[15] Brodland DG, Zitelli JA. Surgical margins for excision of primary cutaneous squamous cell carcinoma. J Am Acad Dermatol 1992;27:241–8.

[16] Thomas DJ, King AR, Peat BG. Excision margins for nonmelanotic skin cancer. Plast Reconstr Surg 2003;112:57–63.

[17] Ribero S, Osella Abate S, Di Capua C, Dika E, Balagna E, Senetta R, et al. Squamocellular Carcinoma of the Skin: Clinicopathological Features Predicting the Involvement of the Surgical Margins and Review of the Literature. Dermatology 2016;232:279–84.

[18] Bonerandi JJ, Beauvillain C, Caquant L, Chassagne JF, Chaussade V, Clavere P, et al. Guidelines for the diagnosis and treatment of cutaneous squamous cell carcinoma and precursor lesions. J Eur Acad Dermatol Venereol 2011;25(5):1–51.

[19] Sapijaszko M, Zloty D, Bourcier M, Poulin Y, Janiszewski P, Ashkenas J, et al. Non-melanoma Skin Cancer in Canada Chapter 5: Management of Squamous Cell Carcinoma. J Cutan Med Surg 2015;19:249–59.

[20] Ansai SI, Umebayashi Y, Katsumata N, Kato H, Kadono T, Takai T, et al. Japanese Dermatological Association Guidelines: Outlines of Guidelines for Cutaneous Squamous Cell Carcinoma 2020. J Dermatol 2021;48:e288–311.

[21] van Lee CB, Kouloubis N, Wakkee M, Kelleners-Smeets NWJ, Nellen RGL, van Rengen A, et al. Rate and Characteristics of Incompletely Excised Cutaneous Squamous Cell Carcinoma: A Dermatological Daily Practice Multicenter Prospective Cohort Study. Dermatol Surg 2022.

[22] Dessinioti C, Stratigos AJ. Overview of guideline recommendations for the management of high-risk and advanced cutaneous squamous cell carcinoma. J Eur Acad Dermatol Venereol 2022;36(1):11–8.

[23] Motley R, Kersey P, Lawrence C, British Association of D, British Association of Plastic S. Multiprofessional guidelines for the management of the patient with primary cutaneous squamous cell carcinoma. Br J Plast Surg 2003;56:85–91.

[24] Khan AA, Potter M, Cubitt JJ, Khoda BJ, Smith J, Wright EH, et al. Guidelines for the excision of cutaneous squamous cell cancers in the United Kingdom: the best cut is the deepest. J Plast Reconstr Aesthet Surg 2013;66:467–71.

[25] Newlands C, Currie R, Memon A, Whitaker S, Woolford T. Non-melanoma skin cancer: United Kingdom National Multidisciplinary Guidelines. J Laryngol Otol 2016;130:S125–32.

[26] Queirolo P, Cinquini M, Argenziano G, Bassetto F, Bossi P, Boutros A, et al. Guidelines for the diagnosis and treatment of cutaneous squamous cell carcinoma: a GRADE approach for evidence evaluation and recommendations by the Italian Association of Medical Oncology. ESMO Open 2024;9:103005.

[27] Stratigos AJ, Garbe C, Dessinioti C, Lebbe C, van Akkooi A, Bataille V, et al. European consensus-based interdisciplinary guideline for invasive cutaneous squamous cell carcinoma: Part 2. Treatment-Update 2023. Eur J Cancer 2023; 193:113252.

[28] Baba N, Kato H, Nakamura M, Matsushita S, Aoki M, Fujimoto N, et al. Narrower clinical margin in high or very high-risk squamous cell carcinoma: a retrospective, multicenter study of 1,000 patients. J der Dtsch Dermatol Ges = J Ger Soc Dermatol JDDG 2022;20:1088–99.

[29] Verdaguer-Faja J, Guerra-Amor A, Ferrandiz-Pulido C, Abril-Perez C, Botella Estrada R, Masferrer E, et al. Histological deep margins in cutaneous squamous cell carcinoma of the scalp and risk of recurrence. J Eur Acad Dermatol Venereol 2025;39:855–64.

[30] Brewer CF, Chawla R, Patel AJK. Galea vs periosteum: impact of excision depth on outcomes for cutaneous squamous cell carcinoma of the scalp. J Plast Surg Hand Surg 2023;57:253–6.

[31] Martin L, Cabalag M, Ramakrishnan A, Martin A. Management of close/positive margins in cutaneous squamous cell carcinoma of the head and neck: a systematised review. Head Neck 2024;7.

[32] van Lee CB, Roorda BM, Wakkee M, Voorham Q, Mooyaart AL, de, et al. Recurrence rates of cutaneous squamous cell carcinoma of the head and neck after Mohs micrographic surgery vs. standard excision: a retrospective cohort study. Br J Dermatol 2019;181:338–43.

[33] Rowe DE, Carroll RJ, Day CL, Jr. Prognostic factors for local recurrence, metastasis, and survival rates in squamous cell carcinoma of the skin, ear, and lip. Implications for treatment modality selection. J Am Acad Dermatol 1992;26: 976–90.

[34] Stevens JS, Murad F, Smile TD, O'Connor DM, Ilori E, Koyfman S, et al. Validation of the 2022 National Comprehensive Cancer Network Risk Stratification for Cutaneous Squamous Cell Carcinoma. JAMA Dermatol 2023;159:728–35.

[35] Wang DM, Ran NA, Granger EE, Koyfman S, Vidimos A, Wysong A, et al. A multicenter validation study of Mohs micrographic surgery versus wide local excision in primary high-stage cutaneous squamous cell carcinoma. J Am Acad Dermatol 2025;93:527–32.

[36] Hunt WTN, Earp E, Brown AC, Veitch D, Wernham AGH. A review of Mohs micrographic surgery for skin cancer. Part 3: Squamous cell carcinoma. Clin Exp Dermatol 2022;47:1765–73.

[37] Moehrle M, Breuninger H, Rocken M. A confusing world: what to call histology of three-dimensional tumour margins? J Eur Acad Dermatol Venereol 2007;21(5): 591.

[38] Loser CR, Rompel R, Mohrle M, Hafner HM, Kunte C, Hassel J, et al. S1 guideline: microscopically controlled surgery (MCS). J der Dtsch Dermatol Ges = J Ger Soc Dermatol JDDG 2015;13:942–51.

[39] Mohrle M, Breuninger H. The Muffin technique–an alternative to Mohs' micrographic surgery. J der Dtsch Dermatol Ges = J Ger Soc Dermatol JDDG 2006;4:1080–4.

[40] Longo C, Ragazzi M, Gardini S, Piana S, Moscarella E, Lallas A, et al. Ex vivo fluorescence confocal microscopy in conjunction with Mohs micrographic surgery for cutaneous squamous cell carcinoma. J Am Acad Dermatol 2015;73(2):321.

[41] Leibovitch I, Huilgol SC, Selva D, Hill D, Richards S, Paver R. Cutaneous squamous cell carcinoma treated with Mohs micrographic surgery in Australia I. Experience over 10 years. J Am Acad Dermatol 2005;53:253–60.

[42] Pugliano-Mauro M, Goldman G. Mohs surgery is effective for high-risk cutaneous squamous cell carcinoma. Dermatol Surg 2010;36:1544–53.

[43] Chren MM, Linos E, Torres JS, Stuart SE, Parvataneni R, Boscardin WJ. Tumor recurrence 5 years after treatment of cutaneous basal cell carcinoma and squamous cell carcinoma. J Invest Dermatol 2013;133:1188–96.

[44] Lansbury L, Bath-Hextall F, Perkins W, Stanton W, Leonardi-Bee J. Interventions for non-metastatic squamous cell carcinoma of the skin: systematic review and pooled analysis of observational studies. BMJ 2013;347:f6153.
[45] Marrazzo G, Zitelli JA, Brodland D. Clinical outcomes in high-risk squamous cell carcinoma patients treated with Mohs micrographic surgery alone. J Am Acad Dermatol 2019;80:633–8.
[46] Tschetter AJ, Campoli MR, Zitelli JA, Brodland DG. Long-term clinical outcomes of patients with invasive cutaneous squamous cell carcinoma treated with Mohs micrographic surgery: A 5-year, multicenter, prospective cohort study. J Am Acad Dermatol 2020;82:139–48.
[47] Xiong DD, Beal BT, Varra V, Rodriguez M, Cundall H, Woody NM, et al. Outcomes in intermediate-risk squamous cell carcinomas treated with Mohs micrographic surgery compared with wide local excision. J Am Acad Dermatol 2020;82:1195–204.
[48] Soleymani T, Brodland DG, Arzeno J, Sharon DJ, Zitelli JA. Clinical outcomes of high-risk cutaneous squamous cell carcinomas treated with Mohs surgery alone: An analysis of local recurrence, regional nodal metastases, progression-free survival, and disease-specific death. J Am Acad Dermatol 2023;88:109–17.
[49] Yung AE, Crouch G, Varey AHR, Lo S, Elliott MS, Lee J, et al. Benchmarking Survival Outcomes Following Surgical Management of pT3 and pT4 Cutaneous Squamous Cell Carcinoma of the Head and Neck. Ann Surg Oncol 2022;29:5124–38.
[50] Fraga SD, Besaw RJ, Murad F, Schmults CD, Waldman A. Complete Margin Assessment Versus Sectional Assessment in Surgically Excised High-Risk Keratinocyte Carcinomas: A Systematic Review and Meta-Analysis. Dermatol Surg 2022;48:704–10.
[51] Udkoff J, Beal BT, Brodland DG, Knackstedt T. Cost effectiveness of intermediate-risk squamous cell carcinoma treated with Mohs micrographic surgery compared with wide local excision. J Am Acad Dermatol 2022;86:303–11.
[52] Jambusaria-Pahlajani A, Miller CJ, Quon H, Smith N, Klein RQ, Schmults CD. Surgical monotherapy versus surgery plus adjuvant radiotherapy in high-risk cutaneous squamous cell carcinoma: a systematic review of outcomes. Dermatol Surg 2009;35:574–85.
[53] Veness MJ, Morgan GJ, Palme CE, Gebski V. Surgery and adjuvant radiotherapy in patients with cutaneous head and neck squamous cell carcinoma metastatic to lymph nodes: combined treatment should be considered best practice. Laryngoscope 2005;115:870–5.
[54] Sahovaler A, Krishnan RJ, Yeh DH, Zhou Q, Palma D, Fung K, et al. Outcomes of Cutaneous Squamous Cell Carcinoma in the Head and Neck Region With Regional Lymph Node Metastasis: A Systematic Review and Meta-analysis. JAMA Otolaryngol Head Neck Surg 2019;145:352–60.
[55] Audet N, Palme CE, Gullane PJ, Gilbert RW, Brown DH, Irish J, et al. Cutaneous metastatic squamous cell carcinoma to the parotid gland: analysis and outcome. Head Neck 2004;26:727–32.
[56] Ebrahimi A, Gupta R, McDowell L, Magarey MJR, Smith PN, Schulte KM, et al. Predictors of distant metastatic recurrence in head and neck cutaneous squamous cell carcinoma with lymph node metastases treated with curative intent: A multicenter study. Head Neck 2025;47:254–62.
[57] Huis In 't Veld, Boere T EA, Zuur CL, Wouters MW, van Akkooi ACJ, Haanen J, et al. Oncological Outcome After Lymph Node Dissection for Cutaneous Squamous Cell Carcinoma. Ann Surg Oncol 2023;30:5017–26.
[58] Yaniv D, Naara S, Netto FOG, Stafford H, Buell J, Chiang E, et al. Response-Adapted Oncologic Surgery in Cutaneous Squamous Cell Carcinoma: A Paradigm Shift Following Neoadjuvant Immunotherapy. Ann Surg Oncol 2025.
[59] Ladwa R, Lee JH, McGrath M, Cooper C, Liu H, Bowman J, et al. Response-Adapted Surgical and Radiotherapy De-Escalation in Resectable Cutaneous Squamous Cell Cancer Using Pembrolizumab: The De-Squamate Study. J Clin Oncol 2025;43:2888–96.
[60] Gurney B, Newlands C. Management of regional metastatic disease in head and neck cutaneous malignancy. 1. Cutaneous squamous cell carcinoma. Br J Oral Maxillofac Surg 2014;52:294–300.
[61] D'Souza J, Clark J. Management of the neck in metastatic cutaneous squamous cell carcinoma of the head and neck. Curr Opin Otolaryngol Head Neck Surg 2011;19:99–105.
[62] O'Brien CJ, McNeil EB, McMahon JD, Pathak I, Lauer CS, Jackson MA. Significance of clinical stage, extent of surgery, and pathologic findings in metastatic cutaneous squamous carcinoma of the parotid gland. Head Neck 2002;24:417–22.
[63] Vauterin TJ, Veness MJ, Morgan GJ, Poulsen MG, O'Brien CJ. Patterns of lymph node spread of cutaneous squamous cell carcinoma of the head and neck. Head Neck 2006;28:785–91.
[64] Givi B, Andersen PE, Diggs BS, Wax MK, Gross ND. Outcome of patients treated surgically for lymph node metastases from cutaneous squamous cell carcinoma of the head and neck. Head Neck 2011;33:999–1004.
[65] Ebrahimi A, Moncrieff MD, Clark JR, Shannon KF, Gao K, Milross CG, et al. Predicting the pattern of regional metastases from cutaneous squamous cell carcinoma of the head and neck based on location of the primary. Head Neck 2010;32:1288–94.
[66] Jol JA, van Velthuysen ML, Hilgers FJ, Keus RB, Neering H, Balm AJ. Treatment results of regional metastasis from cutaneous head and neck squamous cell carcinoma. Eur J Surg Oncol 2003;29:81–6.
[67] Wang JT, Palme CE, Wang AY, Morgan GJ, Gebski V, Veness MJ. patients with metastatic cutaneous head and neck squamous cell carcinoma to cervical lymph nodes, the extent of neck dissection does not influence outcome. J Laryngol Otol 2013;127(1):S2–7.
[68] Schmidt C, Martin JM, Khoo E, Plank A, Grigg R. Outcomes of nodal metastatic cutaneous squamous cell carcinoma of the head and neck treated in a regional center. Head Neck 2015;37:1808–15.
[69] Work G, Invited R, Kim JYS, Kozlow JH, Mittal B, Moyer J, et al. Guidelines of care for the management of cutaneous squamous cell carcinoma. J Am Acad Dermatol 2018;78:560–78.
[70] Kovacs G. Modern head and neck brachytherapy: from radium towards intensity modulated interventional brachytherapy. J Conte Brachytherapy 2015;6:404–16.
[71] Tran A, Moloney M, Kaczmarski P, Zheng S, Desai A, Desai T, et al. Analysis of image-guided superficial radiation therapy (IGSRT) on the treatment of early-stage non-melanoma skin cancer (NMSC) in the outpatient dermatology setting. J Cancer Res Clin Oncol 2023;149:6283–91.
[72] Dal Bello R, Psoroulas S, Fluckiger D, Krayenbuhl J, Moeckli R, Bailat C, et al. The prospective phase I "Flash-Skin I" trial: ultra-high dose rate radiotherapy implementation and quality assurance at a clinical linear accelerator. Radiother Oncol J Eur Soc Ther Radiol Oncol 2026;216:111372.
[73] Yang C, Luo H, Leijie M, Mao R, Lei H, Zhang Y, et al. A safety study of ultra-high dose rate FLASH radiotherapy in the treatment of superficial skin tumors: study protocol of a phase I trial (ChiCTR2400080935). Precis Radiat Oncol 2025;9:72–6.
[74] Kinj R, Gaide O, Jeanneret-Sozzi W, Dafni U, Viguet-Carrin S, Sagittario E, et al. Randomized phase II selection trial of FLASH and conventional radiotherapy for patients with localized cutaneous squamous cell carcinoma or basal cell carcinoma: A study protocol. Clin Transl Radiat Oncol 2024;45:100743.
[75] Bussu F, Tagliaferri L, Corbisiero MF, Lotto C, Pellini R, Guarino P, et al. Management of nasal vestibule carcinomas: recommendations by the Oncological Committee of the Italian Society of Otorhinolaryngology - Head and Neck Surgery. Acta Otorhinolaryngol Ital 2024;44:13–20.
[76] Gunaratne DA, Veness MJ. Efficacy of hypofractionated radiotherapy in patients with non-melanoma skin cancer: Results of a systematic review. J Med Imaging Radiat Oncol 2018;62:401–11.
[77] Mierzwa ML. Radiotherapy for Skin Cancers of the Face, Head, and Neck. Facial Plast Surg Clin North Am 2019;27:131–8.
[78] Garbutcheon-Singh KB, Veness MJ. The role of radiotherapy in the management of non-melanoma skin cancer. Austral J Dermatol 2019.
[79] Porceddu SV, Daniels C, Yom SS, Liu H, Waldron J, Gregoire V, et al. Head and Neck Cancer International Group (HNCIG) Consensus Guidelines for the Delivery of Postoperative Radiation Therapy in Complex Cutaneous Squamous Cell Carcinoma of the Head and Neck (cSCCHN). Int J Radiat Oncol Biol Phys 2020;107:641–51.
[80] Cuperus E, Leguit R, Albregts M, Toonstra J. Post radiation skin tumors: basal cell carcinomas, squamous cell carcinomas and angiosarcomas. A review of this late effect of radiotherapy. Eur J Dermatol 2013;23:749–57.
[81] Kim SK, Barker CA. Outcomes of radiation therapy for advanced T3/T4 nonmelanoma cutaneous squamous cell and basal cell carcinoma. Br J Dermatol 2018;178:e30–2.
[82] Terra JB, Gaster MB, Halmos GB, Roodenburg JL, van der Vegt B, Romeijn TR, et al. Local control of 151 head and neck cutaneous squamous cell carcinoma after radiotherapy: a retrospective study on efficacy and prognostic factors. Clin Otolaryngol 2017;42:851–5.
[83] Harris BN, Pipkorn P, Nguyen KNB, Jackson RS, Rao S, Moore MG, et al. Association of Adjuvant Radiation Therapy With Survival in Patients With Advanced Cutaneous Squamous Cell Carcinoma of the Head and Neck. JAMA Otolaryngol Head Neck Surg 2019;145:153–8.
[84] Rio E, Bardet E, Ferron C, Peuvrel P, Supiot S, Campion L, et al. Interstitial brachytherapy of periorificial skin carcinomas of the face: a retrospective study of 97 cases. Int J Radiat Oncol Biol Phys 2005;63:753–7.
[85] Canueto J, Jaka A, Corchete LA, Gonzalez-Perez AM, Garcia-Castro R, Fuente MJ, et al. Postoperative radiotherapy provides better local control and long-term outcome in selective cases of cutaneous squamous cell carcinoma with perineural invasion. J Eur Acad Dermatol Venereol 2020;34:1080–91.
[86] Kim Y, Lehrer EJ, Wirth PJ, Khesroh EA, Brewer JD, Billingsley EM, et al. Adjuvant radiotherapy may not significantly change outcomes in high-risk cutaneous squamous cell carcinomas with clear surgical margins: A systematic review and meta-analysis. J Am Acad Dermatol 2022;86:1246–57.
[87] Matsumoto A, Li JN, Matsumoto M, Pineider J, Nijhawan RI, Srivastava D. Factors predicting outcomes of patients with high-risk squamous cell carcinoma treated with Mohs micrographic surgery. J Am Acad Dermatol 2021;85:588–95.
[88] Ruiz ES, Koyfman SA, Que SKT, Kass J, Schmults CD. Evaluation of the utility of localized adjuvant radiation for node-negative primary cutaneous squamous cell carcinoma with clear histologic margins. J Am Acad Dermatol 2020;82:420–9.
[89] Loranger N, Karn E, Wang D, Schmults C, Ruiz E. Assessing outcomes of cutaneous squamous cell carcinoma with large-calibre nerve invasion as solitary high-risk factor: A single-institution cohort study. J Eur Acad Dermatol Venereol 2025;39:e333–5.
[90] Zhang J, Wang Y, Wijaya WA, Liang Z, Chen J. Efficacy and prognostic factors of adjuvant radiotherapy for cutaneous squamous cell carcinoma: A systematic review and meta-analysis. J Eur Acad Dermatol Venereol 2021;35:1777–87.
[91] Ruiz ES, Kus KJB, Smile TD, Murad F, Zhou G, Ilori EO, et al. Adjuvant radiation following clear margin resection of high T-stage cutaneous squamous cell carcinoma halves the risk of local and locoregional recurrence: A dual-center retrospective study. J Am Acad Dermatol 2022;87:87–94.
[92] Moscarella E, Di Brizzi EV, Alpi P, Arcelli A, Badellino S, Bossi P, et al. Indications for adjuvant radiotherapy in high-risk cutaneous squamous cell carcinoma with clear margins: a Delphi consensus. Br J Dermatol 2024;190:578–9.

[93] Likhacheva A, Awan M, Barker CA, Bhatnagar A, Bradfield L, Brady MS, et al. Definitive and Postoperative Radiation Therapy for Basal and Squamous Cell Cancers of the Skin: Executive Summary of an American Society for Radiation Oncology Clinical Practice Guideline. Pr Radiat Oncol 2020;10:8–20.
[94] Porceddu SV, Bressel M, Poulsen MG, Stoneley A, Veness MJ, Kenny LM, et al. Postoperative Concurrent Chemoradiotherapy Versus Postoperative Radiotherapy in High-Risk Cutaneous Squamous Cell Carcinoma of the Head and Neck: The Randomized Phase III TROG 05.01 Trial. J Clin Oncol 2018;36:1275–83.
[95] Wang JT, Palme CE, Morgan GJ, Gebski V, Wang AY, Veness MJ. Predictors of outcome in patients with metastatic cutaneous head and neck squamous cell carcinoma involving cervical lymph nodes: Improved survival with the addition of adjuvant radiotherapy. Head Neck 2012;34:1524–8.
[96] Revelles-Penas L, Revilla-Nebreda D, Becerril S, Corchete LA, Dominguez-Rullan I, Martins-Lopes M, et al. Outcome of cutaneous squamous cell carcinoma with microscopic residual disease after surgery and usefulness of postoperative radiotherapy: a retrospective cohort study. J Eur Acad Dermatol Venereol 2022; 36:846–54.
[97] Migden MR, Rischin D, Schmults CD, Guminski A, Hauschild A, Lewis KD, et al. PD-1 Blockade with Cemiplimab in Advanced Cutaneous Squamous-Cell Carcinoma. N Engl J Med 2018;379:341–51.
[98] Rischin D, Migden MR, Lim AM, Schmults CD, Khushalani NI, Hughes BGM, et al. Phase 2 study of cemiplimab in patients with metastatic cutaneous squamous cell carcinoma: primary analysis of fixed-dosing, long-term outcome of weight-based dosing. J Immunother Cancer 2020;8.
[99] Rischin D, Khushalani NI, Schmults CD, Guminski A, Chang ALS, Lewis KD, et al. Integrated analysis of a phase 2 study of cemiplimab in advanced cutaneous squamous cell carcinoma: extended follow-up of outcomes and quality of life analysis. J Immunother Cancer 2021;9.
[100] Migden MR, Khushalani NI, Chang ALS, Lewis KD, Schmults CD, Hernandez-Aya L, et al. Cemiplimab in locally advanced cutaneous squamous cell carcinoma: results from an open-label, phase 2, single-arm trial. Lancet Oncol 2020;21: 294–305.
[101] Migden M, Schmults C, Khushalani NI, Guminski A, Chang AL, Lewis K, et al. Phase II study of cemiplimab in patients with advanced cutaneous squamous cell carcinoma (CSCC): Final analysis from EMPOWER-CSCC-1 groups 1, 2 and 3. Abstr 814P Ann Oncol J Eur Soc Med Oncol 2022;33(ement 7):S918–9.
[102] Hughes BGM, Guminski A, Bowyer S, Migden MR, Schmults CD, Khushalani NI, et al. A phase 2 open-label study of cemiplimab in patients with advanced cutaneous squamous cell carcinoma (EMPOWER-CSCC-1): Final long-term analysis of groups 1, 2, and 3, and primary analysis of fixed-dose treatment group 6. J Am Acad Dermatol 2025;92:68–77.
[103] Grob JJ, Gonzalez R, Basset-Seguin N, Vornicova O, Schachter J, Joshi A, et al. Pembrolizumab Monotherapy for Recurrent or Metastatic Cutaneous Squamous Cell Carcinoma: A Single-Arm Phase II Trial (KEYNOTE-629). J Clin Oncol 2020; 38(25):2916.
[104] Hughes BGM, Munoz-Couselo E, Mortier L, Bratland A, Gutzmer R, Roshdy O, et al. Pembrolizumab for locally advanced and recurrent/metastatic cutaneous squamous cell carcinoma (KEYNOTE-629 study): an open-label, nonrandomized, multicenter, phase II trial. Ann Oncol J Eur Soc Med Oncol 2021;32:1276–85.
[105] Couselo EM, Hughes BGM, Mortier L, Grob J, Gutzner R, O R, et al. Meeting Abstract. Pembrolizumab (pembro) for locally advanced (LA) or recurrent/ metastatic (R/M) cutaneous squamous cell carcinoma (cSCC): Long-term results of the phase 2 KEYNOTE-629 study. Poster presented at 2024 ASCO Annual Meeting. J Clin Oncol 2024;42:9554.
[106] Clingan P, Ladwa R, Brungs D, Harris DL, McGrath M, Arnold S, et al. Efficacy and safety of cosibelimab, an anti-PD-L1 antibody, in metastatic cutaneous squamous cell carcinoma. J Immunother Cancer 2023;11.
[107] Ruiz ES, Munoz-Couselo E, Montaudie H, Berciano-Guerrero MA, de la Gala M, Charles J, et al. Efficacy and safety of cosibelimab in advanced cutaneous squamous cell carcinoma: Results from a Pivotal Open-label Study with a median follow-up of >/=2 years. J Am Acad Dermatol 2025.
[108] Lang R, Welponer T, Richtig E, Wolf I, Hoeller C, Hafner C, et al. Nivolumab for locally advanced and metastatic cutaneous squamous cell carcinoma (NIVOSQUACS study)-Phase II data covering impact of concomitant haematological malignancies. J Eur Acad Dermatol Venereol 2023;37:1799–810.
[109] Jarkowski A, 3rd, Hare R, Loud P, Skitzki JJ, Kane JM, 3rd, May KS, et al. Systemic Therapy in Advanced Cutaneous Squamous Cell Carcinoma (CSCC): The Roswell Park Experience and a Review of the Literature. Am J Clin Oncol 2016; 39:545–8.
[110] Keeping S, Xu Y, Chen CI, Cope S, Mojebi A, Kuznik A, et al. Comparative efficacy of cemiplimab versus other systemic treatments for advanced cutaneous squamous cell carcinoma. Future Oncol (Lond Engl) 2021;17:611–27.
[111] Petzold A, Steeb T, Wessely A, Schatton T, Berking C, Heppt MV. Comparative efficacy analysis identifies immune checkpoint blockade as a new survival benchmark in advanced cutaneous squamous cell carcinoma. Eur J Cancer 2022; 170:42–53.
[112] Maubec E, Boubaya M, Petrow P, Beylot-Barry M, Basset-Seguin N, Deschamps L, et al. Phase II Study of Pembrolizumab As First-Line, Single-Drug Therapy for Patients With Unresectable Cutaneous Squamous Cell Carcinomas. J Clin Oncol 2020;38:3051–61.
[113] Hughes BGM, Mendoza RG, Basset-Seguin N, Vornicova O, Schachter J, Joshi A, et al. Health-Related Quality of Life of Patients with Recurrent or Metastatic Cutaneous Squamous Cell Carcinoma Treated with Pembrolizumab in KEYNOTE-629. Dermatol Ther (Heide) 2021;11:1777–90.
[114] Nuzzolese I, Cavalieri S, Licitra LF, Alfieri S. The Role of Cetuximab in Non-Melanoma Skin Cancer: A Review of Clinical Evidence and Emerging Strategies. Curr Treat Options Oncol 2025;26:673–87.
[115] Maubec E, Petrow P, Scheer-Senyarich I, Duvillard P, Lacroix L, Gelly J, et al. Phase II study of cetuximab as first-line single-drug therapy in patients with unresectable squamous cell carcinoma of the skin. J Clin Oncol 2011;29:3419–26.
[116] Trodello C, Pepper JP, Wong M, Wysong A. Cisplatin and Cetuximab Treatment for Metastatic Cutaneous Squamous Cell Carcinoma: A Systematic Review. Dermatol Surg 2017;43:40–9.
[117] Conen KL, Fischer N, Hofbauer GF, Shafaeddin-Schreve B, Winterhalder R, Rochlitz C, et al. Cetuximab in metastatic squamous cell cancer of the skin: a Swiss case series. Dermatology 2014;229:97–101.
[118] Dereure O, Missan H, Girard C, Costes V, Guillot B. Efficacy and Tolerance of Cetuximab Alone or Combined with Chemotherapy in Locally Advanced or Metastatic Cutaneous Squamous Cell Carcinoma: An Open Study of 14 Patients. Dermatology 2016;232:721–30.
[119] Giacchero D, Barriere J, Benezery K, Guillot B, Dutriaux C, Mortier L, et al. Efficacy of cetuximab for unresectable or advanced cutaneous squamous cell carcinoma–a report of eight cases. Clin Oncol (R Coll Radio) 2011;23:716–8.
[120] Samstein RM, Ho AL, Lee NY, Barker CA. Locally advanced and unresectable cutaneous squamous cell carcinoma: outcomes of concurrent cetuximab and radiotherapy. J Ski Cancer 2014;2014:284582.
[121] Trodello C, Higgins S, Ahadiat O, Ragab O, In G, Hawkins M, et al. Cetuximab as a Component of Multimodality Treatment of High-Risk Cutaneous Squamous Cell Carcinoma: A Retrospective Analysis From a Single Tertiary Academic Medical Center. Dermatol Surg 2019;45:254–67.
[122] Berliner JG, Schulman JM, Lazarova Z, Olasz E, Arron ST. Response of Cutaneous Squamous Cell Carcinoma to Treatment With Cetuximab. Dermatol Surg 2019;45: 313–6.
[123] Joseph K, Alkaabi K, Warkentin H, Ghosh S, Jha N, Smylie M, et al. Cetuximab-radiotherapy combination in the management of locally advanced cutaneous squamous cell carcinoma. J Med Imaging Radiat Oncol 2019;63:257–63.
[124] Cowey CL, Robert NJ, Espirito JL, Davies K, Frytak J, Lowy I, et al. Clinical outcomes among unresectable, locally advanced, and metastatic cutaneous squamous cell carcinoma patients treated with systemic therapy. Cancer Med 2020;9:7381–7.
[125] Preneau S, Rio E, Brocard A, Peuvrel L, Nguyen JM, Quereux G, et al. Efficacy of cetuximab in the treatment of squamous cell carcinoma. J Dermatol Treat 2014; 25:424–7.
[126] Huynh J, Eigentler T, Moritz RKC, Poch G, Schlaak M, Dobos G. Cetuximab plus 5-fluorouracil in patients with advanced cutaneous squamous cell carcinoma: a retrospective cohort study. J der Dtsch Dermatol Ges = J Ger Soc Dermatol JDDG 2025;23(8):932.
[127] Pham JP, Rodrigues A, Goldinger SM, Sim HW, Liu J. Epidermal growth factor receptor inhibitors in advanced cutaneous squamous cell carcinoma: A systematic review and meta-analysis. Exp Dermatol 2024;33:e14978.
[128] Marin-Acevedo JA, Withycombe BM, Kim Y, Brohl AS, Eroglu Z, Markowitz J, et al. Cetuximab for Immunotherapy-Refractory/Ineligible Cutaneous Squamous Cell Carcinoma. Cancers (Basel) 2023;15.
[129] Bossi P, Alberti A, Bergamini C, Resteghini C, Locati LD, Alfieri S, et al. Immunotherapy followed by cetuximab in locally advanced/metastatic cutaneous squamous cell carcinomas: the I-TACKLE trial. Eur J Cancer 2025;220:115379.
[130] Becker JC, Gesierich AH, Leiter U, Zimmer L, Hassel JC, von Wasielewski I, et al. Avelumab plus cetuximab in patients with unresectable stage III or IV cutaneous squamous cell carcinoma: clinical activity and safety results from AliCe, a single-arm multicentre phase II DeCOG trial. Br J Dermatol 2025;193:865–75.
[131] Zandberg DP, Allred JB, Rosenberg AJ, Kaczmar JM, Swiecicki P, Julian RA, et al. Phase II (Alliance A091802) Randomized Trial of Avelumab Plus Cetuximab Versus Avelumab Alone in Advanced Cutaneous Squamous Cell Carcinoma. J Clin Oncol 2025;43:2398–408.
[132] Mecca C, Ponzetti A, Caliendo V, Ciuffreda L, Lista P. Complete response of metastatic cutaneous squamous cell carcinoma to cetuximab plus paclitaxel. Eur J Dermatol 2012;22:758–61.
[133] Kramb F, Doerfer C, Meiwes A, Ramakrishnan K, Eigentler T, Garbe C, et al. Real-world Treatment Patterns and Outcomes with Systemic Therapies in Unresectable Locally Advanced and Metastatic Cutaneous Squamous Cell Carcinoma in Germany. Acta Derm Venereol 2022;102:adv00637.
[134] Gehl J, Sersa G, Matthiessen LW, Muir T, Soden D, Occhini A, et al. Updated standard operating procedures for electrochemotherapy of cutaneous tumours and skin metastases. Acta Oncol 2018;57:874–82.
[135] De Giorgi V, Scarfi F, Saqer E, Gori A, Tomassini GM, Covarelli P. The use of cisplatin electrochemotherapy in nonmelanoma skin cancers: A single-center study. Dermatol Ther 2020;33:e13547.
[136] Clover AJP, de Terlizzi F, Bertino G, Curatolo P, Odili J, Campana LG, et al. Electrochemotherapy in the treatment of cutaneous malignancy: Outcomes and subgroup analysis from the cumulative results from the pan-European International Network for Sharing Practice in Electrochemotherapy database for 2482 lesions in 987 patients (2008-2019). Eur J Cancer 2020;138:30–40.
[137] Bertino G, Groselj A, Campana LG, Kunte C, Schepler H, Gehl J, et al. Electrochemotherapy for the treatment of cutaneous squamous cell carcinoma: The INSPECT experience (2008-2020). Front Oncol 2022;12:951662.
[138] Sersa G, Mascherini M, Di Prata C, Odili J, de Terlizzi F, McKenzie GAG, et al. Outcomes of older adults aged 90 and over with cutaneous malignancies after electrochemotherapy with bleomycin: A matched cohort analysis from the InspECT registry. Eur J Surg Oncol 2021;47:902–12.

[139] Claussen CS, Moir G, Bechara FG, Orlando A, Matteucci P, Mowatt D, et al. Prospective cohort study by InspECT on safety and efficacy of electrochemotherapy for cutaneous tumors and metastases depending on ulceration. J der Dtsch Dermatol Ges = J Ger Soc Dermatol JDDG 2022;20:470–81.
[140] Bonner JA, Harari PM, Giralt J, Azarnia N, Shin DM, Cohen RB, et al. Radiotherapy plus cetuximab for squamous-cell carcinoma of the head and neck. N Engl J Med 2006;354:567–78.
[141] Heath CH, Deep NL, Nabell L, Carroll WR, Desmond R, Clemons L, et al. Phase 1 study of erlotinib plus radiation therapy in patients with advanced cutaneous squamous cell carcinoma. Int J Radiat Oncol Biol Phys 2013;85:1275–81.
[142] Brewster AM, Lee JJ, Clayman GL, Clifford JL, Reyes MJ, Zhou X, et al. Randomized trial of adjuvant 13-cis-retinoic acid and interferon alfa for patients with aggressive skin squamous cell carcinoma. J Clin Oncol 2007;25:1974–8.
[143] Goyal U, Prabhakar NK, Davuluri R, Morrison CM, Yi SK. Role of Concurrent Systemic Therapy with Adjuvant Radiation Therapy for Locally Advanced Cutaneous Head and Neck Squamous Cell Carcinoma. Cureus 2017;9:e1784.
[144] Palmer JD, Schneider CJ, Hockstein N, Hanlon AL, Silberg J, Strasser J, et al. Combination of post-operative radiotherapy and cetuximab for high-risk cutaneous squamous cell cancer of the head and neck: A propensity score analysis. Oral Oncol 2018;78:102–7.
[145] Rischin D, Porceddu S, Day F, Brungs DP, Christie H, Jackson JE, et al. Adjuvant Cemiplimab or Placebo in High-Risk Cutaneous Squamous-Cell Carcinoma. N Engl J Med 2025;393:774–85.
[146] FDA approves cemiplimab-rwlc for adjuvant treatment of cutaneous squamous cell carcinoma. Available at: ⟨https://www.fda.gov/drugs/resources-information-approved-drugs/fda-approves-cemiplimab-rwlc-adjuvant-treatment-cutaneous-squamous-cell-carcinoma⟩, accessed on October 12, 2025.
[147] Libtayo® (cemiplimab) Approved in the European Union as First and Only Immunotherapy for Adjuvant Treatment of Cutaneous Squamous Cell Carcinoma (CSCC) with High Risk of Recurrence after Surgery and Radiation. Available at: ⟨https://investor.regeneron.com/news-releases/news-release-details/libtayor-cemiplimab-approved-european-union-first-and-only⟩. Acessed on December 5, 2025.
[148] Koyfman S, Lee J, Mortier L, Bratland A, Luna-Romero N, Chipman M, et al. Phase III randomized trial (KEYNOTE 630) of adjuvant pembrolizumab in high risk resected locally advanced cutaneous squamous cell carcinoma. J Clin Oncol 2025;43:6000.
[149] Kim EY, Ruiz ES, DeSimone MS, Shalhout SZ, Hanna GJ, Miller DM, et al. Neoadjuvant-Intent Immunotherapy in Advanced, Resectable Cutaneous Squamous Cell Carcinoma. JAMA Otolaryngol Head Neck Surg 2024;150:414–20.
[150] Lim AM, Baker B, Lion P, Angel CM, Simmons J, Jackson B, et al. Radiological, Pathological, and Surgical Outcomes with Neoadjuvant Cemiplimab for Stage II-IV Cutaneous Squamous Cell Carcinoma in the Deep Sequencing in Cutaneous Squamous Cell Carcinomas (DISCERN) Trial. Cancers (Basel) 2025;17.
[151] Gross ND, Miller DM, Khushalani NI, Divi V, Ruiz ES, Lipson EJ, et al. Neoadjuvant Cemiplimab for Stage II to IV Cutaneous Squamous-Cell Carcinoma. N Engl J Med 2022;387:1557–68.
[152] Gross ND, Miller DM, Khushalani NI, Divi V, Ruiz ES, Lipson EJ, et al. Neoadjuvant cemiplimab and surgery for stage II-IV cutaneous squamous-cell carcinoma: follow-up and survival outcomes of a single-arm, multicentre, phase 2 study. Lancet Oncol 2023;24:1196–205.
[153] Breukers SE, Traets JJH, van Dijk SW, Ostos MM, Fraterman I, Crommelin RD, et al. Neoadjuvant ipilimumab and nivolumab in resectable cutaneous squamous cell carcinoma: a randomized phase 2 trial. Nat Med 2025.
[154] Ferrarotto R, Amit M, Nagarajan P, Rubin ML, Yuan Y, Bell D, et al. Pilot Phase II Trial of Neoadjuvant Immunotherapy in Locoregionally Advanced, Resectable Cutaneous Squamous Cell Carcinoma of the Head and Neck. Clinical cancer research official journal American Association Cancer Research 2021;27:4557–65.
[155] Pahalyants V, Jairath NK, Maas DE, Cheraghlou S, Mandal S, Friedman S, et al. Satellitosis or in-transit metastasis in cutaneous squamous cell carcinoma: Risk factors and the prognostic significance. J Am Acad Dermatol 2025.
[156] Smile TD, Ruiz ES, Kus KJB, Murad F, Wei W, Xiong DD, et al. Implications of Satellitosis or In-transit Metastasis in Cutaneous Squamous Cell Carcinoma: A Prognostic Omission in Cancer Staging Systems. JAMA Dermatol 2022;158(4):390.
[157] Ma JH, Wu A, Veness M, Estall V, Hong A, Borg M, et al. In-Transit Metastasis From Squamous Cell Carcinoma. Dermatol Surg 2016;42:1285–92.
[158] Carucci JA, Martinez JC, Zeitouni NC, Christenson L, Coldiron B, Zweibel S, et al. In-transit metastasis from primary cutaneous squamous cell carcinoma in organ transplant recipients and nonimmunosuppressed patients: clinical characteristics, management, and outcome in a series of 21 patients. Dermatol Surg 2004;30:651–5.
[159] Solari N, Spagnolo F, Ponte E, Quaglia A, Lillini R, Battista M, et al. Electrochemotherapy for the management of cutaneous and subcutaneous metastasis: a series of 39 patients treated with palliative intent. J Surg Oncol 2014;109:270–4.
[160] Huis In 't Veld EA, Grunhagen DJ, Deroose JP, Nijsten TEC, Wouters M, Verhoef C, et al. Isolated limb perfusion for unresectable extremity cutaneous squamous cell carcinoma; an effective limb saving strategy. Br J Cancer 2018;119:429–34.
[161] Belgrano V, Ben-Shabat I, Bergh P, Olofsson Bagge R. Isolated limb perfusion as a treatment option for rare types of tumours. Int J Hyperth 2016;32:595–9.
[162] Yakish K, Graham J, Hossler EW. Efficacy of curettage alone for invasive cutaneous squamous cell carcinoma: A retrospective cohort study. J Am Acad Dermatol 2017;77:582–4.
[163] Stewart JR, Lang ME, Brewer JD. Efficacy of nonexcisional treatment modalities for superficially invasive and in situ squamous cell carcinoma: A systematic review and meta-analysis. J Am Acad Dermatol 2022;87:131–7.
[164] Alam M, Armstrong A, Baum C, Bordeaux J, Brown M, Busam K, et al. Guidelines of care for the management of basal cell carcinoma. J Am Acad Dermatol 2018;78:540–59.
[165] Morton CA, Szeimies RM, Basset-Seguin N, Calzavara-Pinton P, Gilaberte Y, Haedersdal M, et al. European Dermatology Forum guidelines on topical photodynamic therapy 2019 Part 1: treatment delivery and established indications - actinic keratoses, Bowen's disease and basal cell carcinomas. J Eur Acad Dermatol Venereol 2019;33:2225–38.
[166] Morton CA, Szeimies RM, Basset-Seguin N, Calzavara-Pinton PG, Gilaberte Y, Haedersdal M, et al. European Dermatology Forum guidelines on topical photodynamic therapy 2019 Part 2: emerging indications - field cancerization, photorejuvenation and inflammatory/infective dermatoses. J Eur Acad Dermatol Venereol 2020;34:17–29.
[167] Baeza-Hernandez G, Canueto J. Intralesional Treatments for Invasive Cutaneous Squamous Cell Carcinoma. Cancers (Basel) 2023;16.
[168] Bergon-Sendin M, Pulido-Perez A, Nieto-Benito LM, Barchino-Ortiz L, Diez-Sebastian J, Suarez-Fernandez R. Effectiveness of neoadjuvant intralesional methotrexate in cutaneous squamous cell carcinoma: A prospective cohorts study. Dermatol Ther 2022;35:e15233.
[169] Maxfield L, Shah M, Schwartz C, Tanner LS, Appel J. Intralesional 5-fluorouracil for the treatment of squamous cell carcinomas. J Am Acad Dermatol 2021;84:1696–7.
[170] Curiel-Lewandrowski C, Stratton D, Adams A, Cui H, Roe D, Sundararajan S. Abstract CT004: A single arm phase 2 study of TVEC in patients with invasive cutaneous SCC: A novel therapeutic approach for low risk tumors. Cancer Res 2024;84:CT004.
[171] Results from the CERPASS Trial in CSCC. Replimune Press Release December 5, 2023. Accessed at ⟨https://ir.replimune.com/news-releases/news-release-details/replimune-shares-initial-primary-analysis-results-cerpass/⟩ on Aug 29, 2025.
[172] Migden M, Chai-Ho W, Daniels GA, Medina T, Wise-Draper TM, Kheterpal M. Abstract CT003: Initial results from an open-label phase 1b/2 study of RP1 oncolytic immunotherapy in solid organ transplant recipients with advanced cutaneous malignancies (ARTACUS). Cancer Res 2024;84:CT003.
[173] Eggermont CJ, Hollatz A, Wakkee M, Louwman M, Dinmohamed AG, Posthuma EFM, et al. Skin cancer risk in more than 200 000 patients with haematological malignancies over 30 years: a nationwide population-based study in the Netherlands. Br J Dermatol 2025;192:1029–37.
[174] Collins L, Quinn A, Stasko T. Skin Cancer and Immunosuppression. Dermatol Clin 2019;37:83–94.
[175] James LJ, Saglimbene V, Wong G, Tong A, Luu LDW, Craig J, et al. Behavioural and pharmaceutical interventions for the prevention of skin cancers in solid organ transplant recipients: a systematic review of randomised controlled trials. BMJ Open 2020;10:e029265.
[176] Harwood CA, Arron ST, Proby CM, Asgari MM, Bouwes Bavinck JN, Green AC, et al. Organ transplantation and cutaneous squamous cell carcinoma: progress, pitfalls and priorities in immunosuppression-associated keratinocyte carcinoma. Br J Dermatol 2017;177:1150–1.
[177] Blomberg M, He SY, Harwood C, Arron ST, Demehri S, Green A, et al. Research gaps in the management and prevention of cutaneous squamous cell carcinoma in organ transplant recipients. Br J Dermatol 2017;177:1225–33.
[178] Bangash HK, Colegio OR. Management of non-melanoma skin cancer in immunocompromised solid organ transplant recipients. Curr Treat Options Oncol 2012;13:354–76.
[179] Jambusaria-Pahlajani A, Jeanselme V, Wang DM, Ran NA, Granger EE, Canueto J, et al. riSCC: A personalized risk model for the development of poor outcomes in cutaneous squamous cell carcinoma. J Am Acad Dermatol 2025;93:73–81.
[180] Rentroia-Pacheco B, Tokez S, Bramer EM, Venables ZC, van de Werken HJG, Bellomo D, et al. Personalised decision making to predict absolute metastatic risk in cutaneous squamous cell carcinoma: development and validation of a clinico-pathological model. EClinicalMedicine 2023;63:102150.
[181] Tremblay-Abel V, Poulin MA, Blouin MM, Parent F, Perron E. Sentinel Lymph Node Biopsy in High-Risk Cutaneous Squamous Cell Carcinoma: Analysis of a Large Size Retrospective Series. Dermatol Surg 2021;47:908–13.
[182] Tomaszewski JM, Lau E, Corry J. Utility of positron emission tomography/computed tomography for nodal staging of cutaneous squamous cell carcinoma in patients with chronic lymphocytic leukemia. Am J Otolaryngol 2014;35:66–9.
[183] Willenbrink TJ, Jambusaria-Pahlajani A, Arron S, Seckin D, Harwood CA, Proby CM. Treatment approaches in immunosuppressed patients with advanced cutaneous squamous cell carcinoma. J Eur Acad Dermatol Venereol 2019;33(8):57–60.
[184] Stasko T, Brown MD, Carucci JA, Euvrard S, Johnson TM, Sengelmann RD, et al. Guidelines for the management of squamous cell carcinoma in organ transplant recipients. Dermatol Surg 2004;30:642–50.
[185] Abril-Perez C, Mansilla-Polo M, Escutia-Munoz B, Sanmartin O, Garces JR, Rodriguez-Prieto MA, et al. Mohs micrographic surgery in immunosuppressed vs immunocompetent patients: Results of a prospective nationwide cohort study (REGESMOHS, Spanish registry of Mohs surgery). J Eur. Acad Dermatol Venereol 2025;39:426–34.
[186] Levin EC, Chow C, Makhzoumi Z, Jin C, Shiboski SC, Arron ST. Association of Postoperative Antibiotics With Surgical Site Infection in Mohs Micrographic Surgery. Dermatol Surg 2019;45:52–7.
[187] Krisl JC, Doan VP. Chemotherapy and Transplantation: The Role of Immunosuppression in Malignancy and a Review of Antineoplastic Agents in

Solid Organ Transplant Recipients. Am J Transpl J Am Soc Transpl Am Soc Transpl Surg 2017;17:1974–91.
[188] Saleem N, Wang J, Rejuso A, Teixeira-Pinto A, Stephens JH, Wilson A, et al. Outcomes of Solid Organ Transplant Recipients With Advanced Cancers Receiving Immune Checkpoint Inhibitors: A Systematic Review and Individual Participant Data Meta-Analysis. JAMA Oncol 2025;11:1150–9.
[189] Schenk KM, Deutsch JS, Chandra S, Davar D, Eroglu Z, Khushalani NI, et al. Nivolumab + Tacrolimus + Prednisone +/- Ipilimumab for Kidney Transplant Recipients With Advanced Cutaneous Cancers. J Clin Oncol 2024;42:1011–20.
[190] Carroll RP, Boyer M, Gebski V, Hockley B, Johnston JK, Kireta S, et al. Immune checkpoint inhibitors in kidney transplant recipients: a multicentre, single-arm, phase 1 study. Lancet Oncol 2022;23:1078–86.
[191] Hanna GJ, Dharanesswaran H, Giobbie-Hurder A, Harran JJ, Liao Z, Pai L, et al. Cemiplimab for Kidney Transplant Recipients With Advanced Cutaneous Squamous Cell Carcinoma. J Clin Oncol 2024;42:1021–30.
[192] Ferrandiz-Pulido C, Leiter U, Harwood C, Proby CM, Guthoff M, Scheel CH, et al. Immune Checkpoint Inhibitors in Solid Organ Transplant Recipients With Advanced Skin Cancers-Emerging Strategies for Clinical Management. Transplantation 2023;107:1452–62.
[193] De Bruyn P, Van Gestel D, Ost P, Kruse V, Brochez L, Van Vlierberghe H, et al. Immune checkpoint blockade for organ transplant patients with advanced cancer: how far can we go? Curr Opin Oncol 2019;31:54–64.
[194] Abdel-Wahab N, Safa H, Abudayyeh A, Johnson DH, Trinh VA, Zobniw CM, et al. Checkpoint inhibitor therapy for cancer in solid organ transplantation recipients: an institutional experience and a systematic review of the literature. J Immunother Cancer 2019;7:106.
[195] Fisher J, Zeitouni N, Fan W, Samie FH. Immune checkpoint inhibitor therapy in solid organ transplant recipients: A patient-centered systematic review. J Am Acad Dermatol 2020;82:1490–500.
[196] d'Izarny-Gargas T, Durrbach A, Zaidan M. Efficacy and tolerance of immune checkpoint inhibitors in transplant patients with cancer: A systematic review. Am J Transpl J Am Soc Transpl Am Soc Transpl Surg 2020;20:2457–65.
[197] Kumar V, Shinagare AB, Rennke HG, Ghai S, Lorch JH, Ott PA, et al. The Safety and Efficacy of Checkpoint Inhibitors in Transplant Recipients: A Case Series and Systematic Review of Literature. Oncologist 2020;25:505–14.
[198] O'Connell KA, Schmults CD. Treatment of metastatic cutaneous squamous cell carcinoma in a solid organ transplant recipient with programmed death-1 checkpoint inhibitor therapy. J Eur Acad Dermatol Venereol 2022;36(1):45–8.
[199] Tio M, Rai R, Ezeoke OM, McQuade JL, Zimmer L, Khoo C, et al. Anti-PD-1/PD-L1 immunotherapy in patients with solid organ transplant, HIV or hepatitis B/C infection. Eur J Cancer 2018;104:137–44.
[200] Leiter U, Loquai C, Reinhardt L, Rafei-Shamsabadi D, Gutzmer R, Kaehler K, et al. Immune checkpoint inhibition therapy for advanced skin cancer in patients with concomitant hematological malignancy: a retrospective multicenter DeCOG study of 84 patients. J Immunother Cancer 2020;8.
[201] Boyd K, Shea SM, Patterson J. Cetuximab for treatment of advanced squamous cell carcinoma in solid organ transplant recipients. Wien Med Woche 2013;163: 372–5.
[202] Lipson EJ, Bodell MA, Kraus ES, Sharfman WH. Successful administration of ipilimumab to two kidney transplantation patients with metastatic melanoma. J Clin Oncol 2014;32:e69–71.
[203] Hillen U, Leiter U, Haase S, Kaufmann R, Becker J, Gutzmer R, et al. Advanced cutaneous squamous cell carcinoma: A retrospective analysis of patient profiles and treatment patterns-Results of a non-interventional study of the DeCOG. Eur J Cancer 2018;96:34–43.
[204] Leard LE, Cho BK, Jones KD, Hays SR, Tope WD, Golden JA, et al. Fatal diffuse alveolar damage in two lung transplant patients treated with cetuximab. J Heart Lung Transpl 2007;26:1340–4.
[205] Zwald F, Leitenberger J, Zeitouni N, Soon S, Brewer J, Arron S, et al. Recommendations for Solid Organ Transplantation for Transplant Candidates With a Pretransplant Diagnosis of Cutaneous Squamous Cell Carcinoma, Merkel Cell Carcinoma and Melanoma: A Consensus Opinion From the International Transplant Skin Cancer Collaborative (ITSCC). Am J Transpl J Am Soc Transpl Am Soc Transpl Surg 2016;16:407–13.
[206] Lipson EJ, Naqvi FF, Loss MJ, Schollenberger MD, Pardoll DM, Moore Jr J, et al. Kidney retransplantation after anti-programmed cell death-1 (PD-1)-related allograft rejection. Am J Transpl J Am Soc Transpl Am Soc Transpl Surg 2020;20 (8):2264.
[207] Harwood CA, Mesher D, McGregor JM, Mitchell L, Leedham-Green M, Raftery M, et al. A surveillance model for skin cancer in organ transplant recipients: a 22-year prospective study in an ethnically diverse population. Am J Transpl J Am Soc Transpl Am Soc Transpl Surg 2013;13:119–29.
[208] Ducroux E, Martin C, Bouwes Bavinck JN, Decullier E, Brocard A, Westhuis-van Elsacker ME, et al. Risk of Aggressive Skin Cancers After Kidney Retransplantation in Patients With Previous Posttransplant Cutaneous Squamous Cell Carcinomas: A Retrospective Study of 53 Cases. Transplantation 2017;101: e133–41.
[209] Bertino G, Sersa G, De Terlizzi F, Occhini A, Plaschke CC, Groselj A, et al. European Research on Electrochemotherapy in Head and Neck Cancer (EURECA) project: Results of the treatment of skin cancer. Eur J Cancer 2016;63:41–52.
[210] Vuong W, Lin J, Wei RL. Palliative radiotherapy for skin malignancies. Ann Palliat Med 2017;6:165–72.
[211] McLaughlin C, Russell MA. Single-fraction high-dose palliative radiotherapy for facial cutaneous squamous cell carcinoma: a case report. Ann Palliat Med 2022; 11:3337–40.
[212] World Health Organization (WHO). Palliative care. Available at: ⟨https://www.who.int/health-topics/palliative-care⟩. Accessed on 10 October, 2022.
[213] Haumann J, Joosten EBA, Everdingen M. Pain prevalence in cancer patients: status quo or opportunities for improvement? Curr Opin Support Palliat Care 2017;11:99–104.
[214] Carlson CL. Effectiveness of the World Health Organization cancer pain relief guidelines: an integrative review. J Pain Res 2016;9:515–34.
[215] Cialkowska-Rysz A, Dzierzanowski T. Topical morphine for treatment of cancer-related painful mucosal and cutaneous lesions: a double-blind, placebo-controlled cross-over clinical trial. Arch Med Sci 2019;15:146–51.
[216] Herms F, Lambert J, Grob JJ, Haudebourg L, Bagot M, Dalac S, et al. Follow-Up of Patients With Complete Remission of Locally Advanced Basal Cell Carcinoma After Vismodegib Discontinuation: A Multicenter French Study of 116 Patients. J Clin Oncol 2019;37:3275–82.
[217] van Leeuwen BL, Houwerzijl M, Hoekstra HJ. Educational tips in the treatment of malignant ulcerating tumours of the skin. Eur J Surg Oncol 2000;26:506–8.
[218] Furka A, Simko C, Kostyal L, Szabo I, Valikovics A, Fekete G, et al. Treatment Algorithm for Cancerous Wounds: A Systematic Review. Cancers (Basel) 2022;14.
[219] Woo KY, Sibbald RG. Local wound care for malignant and palliative wounds. Adv Ski Wound Care 2010;23:417–28. quiz 29–30.
[220] Mao JJ, Ismaila N, Bao T, Barton D, Ben-Arye E, Garland EL, et al. Integrative Medicine for Pain Management in Oncology: Society for Integrative Oncology-ASCO Guideline. J Clin Oncol 2022;40:3998–4024.
[221] Oh Y, Zheng Z, Kim KY, Xu X, Pei M, Oh B, et al. A nomogram combining clinical factors and biomarkers for predicting the recurrence of high-risk cutaneous squamous cell carcinoma. BMC Cancer 2022;22:1126.
[222] Girardi FM, Wagner VP, Martins MD, Abentroth AL, Hauth LA. Impact of AJCC 8 pT staging in cutaneous head and neck squamous cell carcinoma in a nonselected real-world patient sample. Head Neck 2023;45:337–46.
[223] Mirali S, Tang E, Drucker AM, Turchin I, Gooderham M, Levell N, et al. Follow-up of Patients With Keratinocyte Carcinoma: A Systematic Review of Clinical Practice Guidelines. JAMA Dermatol 2023;159:87–94.
[224] Hasan ZU, Ahmed I, Matin RN, Homer V, Lear JT, Ismail F, et al. Topical treatment of actinic keratoses in organ transplant recipients: a feasibility study for SPOT (Squamous cell carcinoma Prevention in Organ transplant recipients using Topical treatments). Br J Dermatol 2022;187:324–37.
[225] Ahmady S, Jansen MHE, Nelemans PJ, Kessels J, Arits A, de Rooij MJM, et al. Risk of Invasive Cutaneous Squamous Cell Carcinoma After Different Treatments for Actinic Keratosis: A Secondary Analysis of a Randomized Clinical Trial. JAMA Dermatol 2022;158:634–40.
[226] Leus AJG, Haisma MS, Terra JB, Sidorenkov G, Festen S, Plaat BEC, et al. Influence of Frailty and Life Expectancy on Guideline Adherence and Outcomes in Cutaneous Squamous Cell Carcinoma of the Head and Neck: A Prospective Pilot Study. Dermatology 2023;239:148–57.
[227] Stefanovic N, Fitzmaurice CJ, Ormond P, Irvine AD, Barry RB. Risk factors for distant metastasis in cutaneous squamous cell carcinoma. Br J Dermatol 2022.
[228] Granger EE, Ran NA, Groover MK, Koyfman SA, Vidimos AT, Wysong A, et al. Most cutaneous squamous cell carcinoma recurrences occur in the first 3 years after diagnosis: A multicenter retrospective cohort study. J Am Acad Dermatol 2024;91:957–60.
[229] McLaughlin EJ, Miller L, Shin TM, Sobanko JF, Cannady SB, Miller CJ, et al. Rate of regional nodal metastases of cutaneous squamous cell carcinoma in the immunosuppressed patient. Am J Otolaryngol 2017;38:325–8.
[230] Levine DE, Karia PS, Schmults CD. Outcomes of Patients With Multiple Cutaneous Squamous Cell Carcinomas: A 10-Year Single-Institution Cohort Study. JAMA Dermatol 2015;151:1220–5.
[231] Cheng JY, Li FY, Ko CJ, Colegio OR. Cutaneous Squamous Cell Carcinomas in Solid Organ Transplant Recipients Compared With Immunocompetent Patients. JAMA Dermatol 2018;154:60–6.
[232] Venables ZC, Autier P, Nijsten T, Wong KF, Langan SM, Rous B, et al. Nationwide Incidence of Metastatic Cutaneous Squamous Cell Carcinoma in England. JAMA Dermatol 2019;155:298–306.
[233] Thompson AK, Kelley BF, Prokop LJ, Murad MH, Baum CL. Risk Factors for Cutaneous Squamous Cell Carcinoma Recurrence, Metastasis, and Disease-Specific Death: A Systematic Review and Meta-analysis. JAMA Dermatol 2016; 152:419–28.
[234] Zakhem GA, Pulavarty AN, Carucci J, Stevenson ML. Association of Patient Risk Factors, Tumor Characteristics, and Treatment Modality With Poor Outcomes in Primary Cutaneous Squamous Cell Carcinoma: A Systematic Review and Meta-analysis. JAMA Dermatol 2023;159:160–71.
[235] Karia PS, Jambusaria-Pahlajani A, Harrington DP, Murphy GF, Qureshi AA, Schmults CD. Evaluation of American Joint Committee on Cancer, International Union Against Cancer, and Brigham and Women's Hospital tumor staging for cutaneous squamous cell carcinoma. J Clin Oncol 2014;32:327–34.
[236] Ran NA, Granger EE, Brodland DG, Canueto J, Carr DR, Carter JB, et al. Risk Factor Number and Recurrence, Metastasis, and Disease-Related Death in Cutaneous Squamous Cell Carcinoma. JAMA Dermatol 2025;161:597–604.

[237] Ruiz ES, Karia PS, Morgan FC, Schmults CD. The positive impact of radiologic imaging on high-stage cutaneous squamous cell carcinoma management. J Am Acad Dermatol 2017;76:217–25.
[238] Maher JM, Schmults CD, Murad F, Karia PS, Benson CB, Ruiz ES. Detection of subclinical disease with baseline and surveillance imaging in high-risk cutaneous squamous cell carcinomas. J Am Acad Dermatol 2020;82:920–6.
[239] Fox M, Brown M, Golda N, Goldberg D, Miller C, Pugliano-Mauro M, et al. Nodal staging of high-risk cutaneous squamous cell carcinoma. J Am Acad Dermatol 2019;81:548–57.
[240] van Egmond S, Wakkee M, Droger M, Bastiaens MT, van Rengen A, de Roos KP, et al. Needs and preferences of patients regarding basal cell carcinoma and cutaneous squamous cell carcinoma care: a qualitative focus group study. Br J Dermatol 2019;180:122–9.