European Journal of Cancer 243 (2026) 116763

Contents lists available at ScienceDirect

European Journal of Cancer

journal homepage: www.ejcancer.com

Review

European consensus-based interdisciplinary guideline for invasive cutaneous squamous cell carcinoma. Part 1: Diagnostics and prevention – Update 2026

Alexander J. Stratigos [a,*,1], Clio Dessinioti [a,1], Claus Garbe [b], Celeste Lebbe [c], Teresa Amaral [d], Veronique Bataille [e], Brigitte Dreno [f], Reinhard Dummer [g], Maria Concetta Fargnoli [h], Ana Maria Forsea [i,j], Christoffer Gebhardt [k], Catherine A. Harwood [l], Axel Hauschild [m], Christoph Hoeller [n], Lidija Kandolf-Sekulovic [o], Roland Kaufmann [p], Nicole WJ Kelleners-Smeets [q,r], Peter Koelblinger [s], Aimilios Lallas [t], Ulrike Leiter [b], Konstantinos Liopyris [a], Veronique del Marmol [u], David Moreno-Ramirez [v], Giovanni Pellacani [w], Ketty Peris [x,y], Philippe Saiag [z], Luca Tagliaferri [aa,ab,2], Myrto Trakatelli [ac], Ricardo Vieira [ad], Iris Zalaudek [ae], Petr Arenberger [af,3], Alexander C.J. van Akkooi [ag,ah,ai,4], Alexander M.M. Eggermont [aj,ak,4], Paul Lorigan [al,4], Mario Mandala [am,4], Josep Malvehy [an], On behalf of EADO[5], EDF[6], ESTRO[7], UEMS-DV[8], EORTC[9]

[a] 1st Department of Dermatology-Venereology, Andreas Sygros Hospital, Medical School, National and Kapodistrian University of Athens, Athens, Greece
[b] Centre for Dermatooncology, Department of Dermatology, Eberhard Karls University, Tuebingen, Germany
[c] Université Paris Cite,AP-HP Dermato-oncology and CIC, Cancer institute APHP.nord Paris cité, INSERM U1342 - Equipe 1 - CNRS EMR8000, Saint Louis Hospital, Paris, France
[d] Institute Strauss, 3 Rue de la Prte de l'Hôpital, Strasbourg 67000, France
[e] Mount Vernon Cancer Centre, East and North NHS Trust, Northwood, UK
[f] Nantes Université, INSERM, CNRS, Immunology and New Concepts in ImmunoTherapy, INCIT, UMR 1302/EMR6001, Nantes F-44000, France
[g] Skin cancer Centre at University Hospital Zurich and University Zurich, Zurich, Switzerland and Kantonsspital Aarau, Switzerland
[h] San Gallicano Dermatological Institute, IRCCS, Rome, Italy
[i] Carol Davila University of Medicine and Pharmacy Bucharest, Department of Oncologic Dermatology, Elias University Hospital Bucharest, Romania
[j] Health and Medical University Potsdam, Potsdam, Germany
[k] Department of Dermatology, University Medical Center Hamburg-Eppendorf, Hamburg, Germany
[l] Centre for Cell Biology and Cutaneous Research, Blizard Institute, Barts and the London School of Medicine and Dentistry, Queen Mary University of London, UK
[m] Department of Dermatology, University Hospital (UKSH), Kiel, Germany
[n] Department of Dermatology, Medical University of Vienna, Austria
[o] Department of Dermatology, Medical Faculty, Military Medical Academy, Belgrade, Serbia
[p] Department of Dermatology, Mainz University Medicine, Mainz, Germany
[q] GROW-School for Oncology and Reproduction, Maastricht University, Maastricht, Netherlands
[r] Department of Dermatology, Maastricht University Medical Centre+, Maastricht, Netherlands, Maastricht University, Maastricht, Netherlands
[s] Department of Dermatology and Venerology, Paracelsus Medical University, Salzburg, Austria
[t] First Department of Dermatology, School of Medicine, Faculty of Health Sciences, Aristotle University, Thessaloniki, Greece
[u] Department of Dermatology, University Hospital Erasme, Université Libre de Bruxelles, Belgium
[v] Department of Medical-&-Surgical Dermatology Service. Hospital Universitario Virgen Macarena, Sevilla, Spain
[w] Dermatology Unit, University of Rome La Sapienza, Rome, Italy
[x] UOC di Dermatologia, Dipartimento di Scienze Mediche e Chirurgiche Addominali ed Endocrino Metaboliche, Fondazione Policlinico Universitario A. Gemelli - IRCCS, Rome, Italy
[y] Dermatologia, Università Cattolica del Sacro Cuore, Rome, Italy
[z] Department of General and Oncologic Dermatology, Ambroise-Paré hospital, APHP, & EA 4340 "Biomarkers in cancerology and hemato-oncology", UVSQ, Université Paris-Saclay, Boulogne-Billancourt, France
[aa] Dipartimento di Diagnostica per Immagini e Radioterapia Oncologica, Fondazione Policlinico Universitario A. Gemelli IRCCS, Rome, Italy
[ab] Dipartimento di Scienze Radiologiche ed Ematologiche, Università Cattolica del Sacro Cuore, Rome, Italy
[ac] Department of Dermatology, Papageorgiou Hospital, Aristotle University Department of Medicine, Thessaloniki, Greece

* Correspondence to: 1st Department of Dermatology-Venereology, National and Kapodistrian University of Athens, Andreas Sygros Hospital, Athens, Greece.
E-mail address: alstrat2@gmail.com (A.J. Stratigos).

https://doi.org/10.1016/j.ejca.2026.116763
Received 19 March 2026; Accepted 17 April 2026
Available online 7 May 2026
0959-8049/© 2026 The Author(s). Published by Elsevier Ltd. This is an open access article under the CC BY-NC license (http://creativecommons.org/licenses/by-nc/4.0/).

[ad] Coimbra Hospital and University Centre, Coimbra, Portugal
[ae] Department of Dermatology, University of Trieste, Italy
[af] Department of Dermatovenereology, Third Faculty of Medicine, Charles University, Prague, Czech Republic
[ag] Department of Melanoma and Surgical Oncology, Institute of Academic Surgery, Royal Prince Alfred Hospital, Sydney, New South Wales, Australia
[ah] Faculty of Medicine & Health, University of Sydney, Sydney, New South Wales, Australia
[ai] Melanoma Institute Australia, Sydney, New South Wales, Australia
[aj] University Medical Center Utrecht & Princess Máxima Center, Utrecht 3584 CS, the Netherlands
[ak] Comprehensive Cancer Center Munich, Technical University Munich & Ludwig Maximilian University, Munich, Germany
[al] Division of Cancer Sciences, University of Manchester; Department of Medical Oncology, Christie NHS Foundation Trust, Manchester, University of Manchester, United Kingdom
[am] University of Perugia, Perugia, Italy
[an] Dermatology Department of Hospital Clinic of Barcelona, University of Barcelona, IDIBAPS, CIBER de enfermedades raras, Instituto Carlos III, Spain

ARTICLE INFO

Key words:
Invasive cutaneous squamous cell carcinoma
Advanced
Low-risk
High-risk
Common primary CSCC
Locally advanced CSCC
Metastatic CSCC
Diagnosis
Prognosis
Staging
Imaging
Prevention
Chemoprevention
Immunosuppression

ABSTRACT

Invasive cutaneous squamous cell carcinoma (CSCC) is one of the most common cancers in white populations, accounting for 20% of all cutaneous malignancies. A collaboration of multidisciplinary experts from the European Association of Dermato-Oncology (EADO), the European Dermatology Forum (EDF), the European Society for Radiotherapy and Oncology (ESTRO), the European Union of Medical Specialists (UEMS)-Dermatology Venereology, and the European Organization of Research and Treatment of Cancer (EORTC), was formed to update guideline recommendations on CSCC (previous version 2023), based on current literature and expert consensus. Part 1 of the guidelines addresses diagnostics and prevention in immunocompetent as well as immunosuppressed patients. CSCC may be classified as easy-to-treat (vast majority) or difficult-to-treat, common primary CSCC, and is further defined as low risk or higher risk depending on the risk of recurrence or metastasis. A new classification of five groups of difficult-to-treat CSCC (DTT-CSCC) is proposed, published in 2025 by EADO experts and reflecting the commonly encountered clinical challenges. Difficult-to-treat (DTT) CSCC includes DTT-common CSCC groups 1 and 2 (which correspond to a subgroup of common CSCC that are complex to treat due to tumor and/or patient characteristics or multiplicity), DTT-CSCC group 3 corresponding to locally advanced CSCC, and DTT-CSCC groups 4 and 5 corresponding to CSCC with locoregional or distant metastases, respectively. The first step of diagnostics is based on clinical and dermatoscopic features, and is always confirmed by histopathology. The presence of risk factors characterizes higher risk CSCC, and the more risk factors, the higher the risk. After the histological diagnosis of CSCC has been established, the second step includes staging procedures, such as physical examination and, when indicated, imaging. In the third and final step, the clinical, histologic and radiologic findings are incorporated into staging systems. The more widely used staging systems are the American Joint Committee on Cancer 8th edition (AJCC8) and the Brigham and Women's Hospital (BWH) systems. Prevention strategies include oral nicotinamide and sun protection measures.

1. Information about the guidelines

1.1. Societies in charge

This guideline was developed on behalf of the European Association of Dermato-Oncology (EADO), the European Dermatology Forum (EDF), in collaboration with the European Society for Radiotherapy and Oncology (ESTRO) and the European Union of Medical Specialists (Union Européenne des Médecins Spécialistes, UEMS) -Dermatology Venereology. In order to guarantee the interdisciplinary character of these guidelines, they were developed in cooperation with the European Organization for Research and Treatment of Cancer (EORTC). Alexander J. Stratigos in collaboration with Clio Dessinioti, Claus Garbe and Josep Malvehy coordinated the authors' contributions as part of the EADO Guideline Program in Dermato-oncology. Collaboration on guideline development with EDF, ESTRO, UEMS-Dermatology Venereology, and EORTC guaranties the interdisciplinary quality of the guideline.

1.2. Disclaimer

Medicine is subject to a continuous development process. Therefore, all statements, including those on diagnostic and therapeutic procedures, can only reflect the state of scientific knowledge at the time this guideline went to press. The treating physician who refers to the recommendations of this guideline must consider scientific progress since the guideline was published.

1.3. Scope

This guideline has been written to assist clinicians in the diagnosis, follow-up and treatment of patients with invasive cutaneous squamous cell carcinoma (CSCC). This update was initiated mainly due to advances in diagnostics, new evidence on prognostic risk factors, and prevention. The use of these guidelines in clinical routine should improve patient care.

1.4. Target population

These two parts of the CSCC guideline contain recommendations for the diagnosis, prevention, treatment and follow-up of patients with invasive CSCC. The guideline is addressed to the attending physicians and the medical nursing staff. An attempt has been made to write the guideline in a way that is easy to understand, so that patients can also understand the recommendations.

1.5. Principles of methodology

We focus on invasive CSCC (hereafter CSCC), excluding actinic

[1] Contributed equally.
[2] ESTRO
[3] UEMS-DV
[4] EORTC
[5] European Association of Dermato-Oncology
[6] European Dermatology Forum
[7] European SocieTy for Radiotherapy and Oncology
[8] European Union of Medical Specialists (Union Européenne des Médecins Spécialistes) -Dermatology Venereology
[9] European Organization for Research and Treatment of Cancer

keratoses (AK), Bowen's disease (in situ), and mucosal SCCs such as those located in the genital area, or those in the labial-buccal-nasal area, which are often mixed with CSCC under the label of 'head and neck' tumors. Particular emphasis is given to the definitions of CSCC, the diagnosis, risk classification, updated staging systems and treatment modalities. Patient education and prevention issues are also addressed. Formulation of clear sections has been made to support clinicians in their practice.

The European Interdisciplinary Guidelines on invasive squamous cell carcinoma of the skin are written as a uniform text and then published in two separate but integral parts: Part 1 on definitions, epidemiology, etiopathogenesis, diagnosis, risk classification, staging and prevention and Part 2 on treatments, supportive care, patient education and follow-up (Stratigos et al. Part 2. 2026).

The guideline published here are an update of the existing European consensus-based interdisciplinary guidelines for the management of invasive CSCC version 2023 [1,2] and are additionally informed by other up-to-date guidelines, including the National Comprehensive Cancer Network (NCCN) Clinical Practice Guidelines in Oncology for squamous cell skin cancer (version 1.2026) [3], and the British Association of Dermatologists guidelines for the management of people with cutaneous squamous cell carcinoma (version 2020). [4] *De novo* literature search was conducted by the authors by Medline search in English language publications with last search date on October 13, 2025. The literature search begun from the last literature search performed for the guideline 2023 on 10 March 2023. Search terms included: 'cutaneous squamous cell carcinoma', 'squamous cell carcinoma', and 'advanced, locally advanced, low-risk, high-risk, common primary CSCC, locally advanced CSCC, metastatic CSCC'. These terms were combined with 'diagnosis, prognosis, staging, imaging, prevention, chemoprevention, guidelines, treatment, surgical excision, radiotherapy, adjuvant, systemic, anti-PD-1 antibody, cemiplimab, pembrolizumab, chemotherapy, cetuximab, EGFR-inhibitors, clinical trials, follow up, patient education'. The references cited in selected papers were also searched for further relevant publications. The guideline methodology was based on the standards of the Appraisal of Guidelines for Research and Evaluation (AGREE II) instrument [5].

Recommendations are based on the level of best quality available evidence and good clinical practice points (GPP). The levels of evidence were graded according to the Oxford classification (Supplementary Table 1) [6]. In brief, level 1 indicates strongest evidence based on systematic review of well-designed studies, level 2 based on randomized or well-designed cohort or cross-sectional studies, level 3 based on non-randomized adequately designed studies, and levels 4 and 5 indicate the weakest evidence based on small number of patients or poor quality. Level may be graded down based on study quality, imprecision, indirectness, because of inconsistency between studies, or because the absolute effect size is very small. Level may be graded up if there is a large or very large effect size. (Supplementary Table 1). The grades of recommendation were also classified as A, B, C, X. In this update we introduced color-coded recommendations: green for strong, light green for medium strength, yellow for weak recommendation, red for strong contraindication and white for a good clinical practice point. (Table 1).

Expert consensus was provided wherever adequate evidence is not available (described in Supplementary Appendix-guideline part 1). The changes in the guideline update 2026 compared with the guideline version 2023 are presented in Supplementary Appendix-guideline part 1. In view of the regulatory approval of adjuvant cemiplimab for CSCC at "high risk of recurrence", the classification of CSCC was revised to "low-risk" and "higher-risk" throughout the guideline. Also, the previously termed "high-risk" factors were revised to "risk factors" to avoid confusion with the tumors at high risk of recurrence eligible for adjuvant cemiplimab.

The guideline manuscripts were additionally externally reviewed by reviewers from each participating society, who were not included as authors of the guidelines.

1.6. Financing

The authors did this work on a voluntary basis and did not receive any honorarium. The authors paid their own travel expenses for participation in the consensus conferences. Accommodation costs were in part reimbursed by EADO.

1.7. Audience and period of validity

This set of guidelines will assist healthcare providers in managing their patients according to the current standards of care and evidence-based medicine. The guidelines published here reflect the best published data available at the time the report was prepared. Caution should be exercised in interpreting the data; the results of future studies may modify the conclusions or recommendations in this report. In addition, it may be necessary to deviate from these guidelines for individual patients or under special circumstances. Just as adherence to the guidelines may not constitute defense against a claim of negligence (malpractice), deviation from them should not necessarily be deemed negligent. These guidelines will require updating approximately every two years (expiration date: December 2028) but advances in medical sciences may demand an earlier update.

Table 1
Grades of recommendation.

Grade of recommendation	Description	Syntax	Color
A	Strong recommendation	Shall	Green
B	Medium strength recommendation	Should	Light green
C	Weak recommendation	May/can	Yellow
X	Contraindication	Shall not/should not	Red
GPP	Good clinical practice point	Based on consensus, when adequate evidence was not available	White

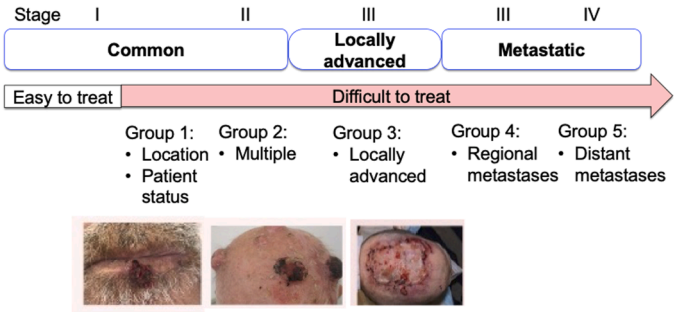

Fig. 1. Summary schematic showing the EADO difficult-to-treat CSCC classification corresponding to the traditional definitions and stage. [13].

2. Definitions

Cutaneous SCC (CSCC) is a common skin cancer characterized by the malignant proliferation of epidermal keratinocytes and it is classified as a keratinocyte carcinoma together with basal cell carcinoma. It is distinguished into *in situ* (Bowen's disease) and invasive form. These guidelines focus on invasive CSCC (CSCC).

Depending on the extent of the disease, CSCC is classified as common primary, by far the most frequent, and advanced CSCC. Common primary CSCCs are non-metastatic CSCC, usually easy-to-treat lesions, which can be further classified as low-risk or higher-risk, depending on the risk of recurrence. Higher-risk CSCC is defined as invasive CSCC without locoregional (in transit or regional nodal metastasis) or distant metastasis (staged as N0 and M0), that has features associated with a higher risk for local recurrence and metastasis (detailed in Section 6, box 4), and that is amenable to curative surgery or RT. [7,8] Advanced CSCC is classified as either locally advanced (laCSCC), or metastatic (mCSCC).

LaCSCC shall be defined as non-metastatic CSCC, not amenable to either surgery or radiotherapy with reasonable hope for cure, because of multiple recurrences, large size, bone erosion or invasion, or deep infiltration beyond subcutaneous tissue into muscle or along nerves, or tumors in which curative resection would result in unacceptable complications, morbidity or deformity. [9] This corresponds to unresectable T3/T4 (tumor invading deep structures) according to the 8th edition AJCC and 9th edition UICC staging classification. [10–12] MCSCC includes loco-regional metastatic CSCC with in-transit metastases or metastases of regional lymph nodes, or distant metastatic CSCC requiring systemic treatments. CSCC with regional nodal metastasis corresponds to stage III or IV according to the 8th edition AJCC or UICC staging classification. Metastatic CSCC with distant metastasis corresponds to stage IV. The presence of in-transit metastases is not included in the 8th edition AJCC/UICC staging systems.

In addition, an operational classification of five groups of difficult-to-treat CSCC (DTT-CSCC) based on independent clustering by EADO experts was published in 2025. Five groups of DTT-CSCC were defined spanning the common and advanced CSCC definitions. In particular, DTT-common CSCC group 1 includes common CSCC that is complex to treat due to tumor and/or patient characteristics (such as comorbidities or tumor location), and DTT-common CSCC group 2 includes multiple common CSCCs when the number is the main problem. DTT-CSCC group 3 corresponds to locally advanced CSCC, while DTT-CSCC groups 4 and 5 correspond to CSCC with regional metastases (nodal or cutaneous) or distant metastases, respectively. [13] (Figures 1, 2)

Recommendation 1. (updated from 2023)

Definitions and classifications of invasive CSCC	**Guideline 2026** **Evidence- based statement**
Grade of recommendation: A	Common primary CSCC shall be classified as low-risk or higher-risk. Higher-risk CSCC is defined as invasive CSCC without locoregional (in transit or regional nodal metastasis) or distant metastasis (staged as N0 and M0), that has features associated with a higher risk for local recurrence and metastasis (see Recommendation Box 4). Advanced CSCC shall be classified as locally advanced (LaCSCC), locoregional metastatic or distant metastatic CSCC (mCSCC). LaCSCC shall be defined as non-metastatic CSCC, not amenable to either surgery or radiotherapy with reasonable hope for cure, because of multiple recurrences, large size, bone erosion or invasion, or deep infiltration beyond subcutaneous tissue into muscle or along nerves, or else tumors in which curative resection would result in unacceptable complications, morbidity or deformity.
Level of evidence: 1	Meta-analysis[7, 8], phase 1 and phase 2 cohort studies[9]
	Strength of consensus: 100%

3. Epidemiology and etiology

3.1. Epidemiology

CSCC is the second most common form of skin cancer, accounting for 20% of keratinocyte carcinomas. Reliable population-based CSCC incidence data are limited, but indicate that rates are increasing in most white populations globally and are predicted to continue to increase. [14–17] International incidence data are presented in (Supplementary Table 2). [15,16,18–22] Rates increase with age, male sex (SIR, 2.1; 95%

	Stage	Characteristics		Illustrative pictures	Classification group
Common cSCC	I	**Easy to treat cSCC**	cSCC (TN0M0) easily manageable None of the other groups characteristics **Surgical excision recommended*		Not included in the experiment
Common cSCC	IIA	**Complex to treat**	cSCC (TN0M0) complex to treat due to tumor and/or patient characteristics* **Surgery is likely to be curative but functional or cosmetic consequences and/or other factors (general status, immunosuppression, comorbidities, tumor history..) may lead to therapeutic discussion including radiotherapy with curative intention and/or medical treatments*		**Group 1** *n* = 65
Common cSCC	IIB	**Multiple tumors**	Multiple cSCCs (TN0M0) when the number is the main problem for management, whatever the background (genetics, immunosuppression…) **Multimodal approach with either surgery/ radiotherapy/systemic therapy* ***when the characteristics of at least one cSCC, is the main problem and not the number itself, patients must be classified in other relevant groups according to the most problematic cSCC*		**Group 2** *n* = 24
Advanced cSCC	IIC	**Locally advanced without regional metastases**	Locally advanced cSCC (TN0M0) **surgery and/or radiotherapy are unlikely to be curative indication for systemic therapy / radiotherapy/ palliative care according to patient's performance status*		**Group 3** *n* = 69
Metastatic cSCC	III	**Regional metastases**	cSCC with regional metastases either nodal or cutaneous metastases distant from the primary (TN+M0) whatever the severity and number of cSCC **Multimodal approach with either surgery/ radiotherapy/systemic therapy*		**Group 4** *n* = 59
Metastatic cSCC	IV	**Distant metastases**	cSCC with distant metastases (TNM+), whatever the severity and number of cSCC **Multimodal approach with systemic therapy, radiotherapy or palliative care according to patient's performance status*		**Group 5** *n* = 31

Fig. 2. EADO classification for CSCC. Six-group classification derived from the interpretation of the five consensual clusters and the addition of the easy to treat group. Each definition is the best formulation found by the experts to describe the common points between cases in each given consensual cluster. The numbers indicate the number of cases initially included in each consensual cluster. (From: Gaudy-Marqueste C, Grob JJ, Garbe C, Ascierto PA, Arron S, Basset-Seguin N, et al. Operational classification of cutaneous squamous cell carcinomas based on unsupervised clustering of real cases by experts. J Eur Acad Dermatol Venereol. 2025;39:612–21. Creative Commons CC BY-NC-ND license, [13]).

CI, 2.06–2.14) and low latitude and multiplicity is strongly correlated with age. [22,23]. The associated public health burden of CSCC is substantially underestimated. [14,24] Markedly increased rates of CSCC have been reported in immunocompromised individuals, [25] and in particular patients with solid organ transplants [26–28], hematologic malignancy including chronic lymphocytic leukemia (CLL) [29–32] and human immunodeficiency virus (HIV) infection [33].

Common primary CSCC are typically indolent tumors, rarely giving rise to metastasis, when they are treated early and correctly. [14,34–37] Most CSCC tumors have a very good prognosis, with five-year cure rates of greater than 90%. [37–39] The rate of recurrence was reported to be 4.6% in a large single center study of more than 900 patients with CSCC followed for approximately 10 years, 3.7% for nodal disease and 2.1% for disease-specific death. [39,40] European data on metastatic risk from the UK National Cancer Registration and Analysis Service reported a cumulative incidence of loco-regional or distant metastasis after a median follow up of 15.2 months was 2.1% (1.1% in women, 2.4% in men) in 2013–2015: most mCSCC (85.2%) were diagnosed within 2

years from the primary CSCC and the usual site of metastasis was the head and neck or parotid lymph nodes (73.6%). [37] The risk of metastasis is higher for tumors with multiple risk factors. [41] Of note, disease-specific death has been reported to occur not only as a result from metastasis but also due to local complications and underlying tissue destruction in laCSCC. [42] In addition, several studies have shown worse outcomes for CSCC in immunosuppressed patients compared to immunocompetent patients. [34,43–46] In immunosuppressed patients, loco-regional recurrence was more common [43], the risk of metastatic CSCC at least doubled [37] and outcomes for advanced disease were significantly worse [47]. Patients with epidermolysis bullosa also have a high risk of early-onset, aggressive and often multiple CSCCs developing at sites of chronic skin blistering and scarring and a particularly high rate of disease-specific death. [48]

3.2. Etiology

Beside ultraviolet radiation (UVR) exposure (sun exposure and use of tanning beds), which is by far the most important causal factor for CSCC [49], other factors implicated [50,51] include immunosuppression and immunosuppressive drugs (e.g. azathioprine and ciclosporin) [52,53], non-immunosuppressive drugs such as BRAF inhibitors [54], voriconazole [55], and hydrochlorothiazide diuretics [53,56,57], chronic inflammation [51], toxins such as arsenic and polyaromatic hydrocarbons [51], human papillomaviruses, particularly β-HPV types [50,51, 58–60], smoking [61,62], alcohol [63], genodermatoses responsible for defects in DNA repair and genomic stability (e.g., xeroderma pigmentosum, recessive dystrophic epidermolysis bullosa (RDEB), epidermodysplasia verruciformis (EV), oculocutaneous albinism, Fanconi anemia and Lynch/Muir Torre syndrome and porokeratosis[50,51,58].

Genome-wide association studies have also highlighted germline single nucleotide polymorphisms associated with CSCC risk, including *MC1R, ASIP, TYR, SLC45A2, OCA2, IRF4*, *BNC2*, the metastasis suppressor gene *CADM1, AHR*, a transcription factor that regulates cell proliferation, *SEC16A* involved in secretion and cellular proliferation, and other loci involved in pigmentation phenotypes (*TYRP1, TRSP1*) in tumor immunosuppression (HLA variants, BACH2), invasion and metastasis (*SETDB1, ECM1*, and *CERS2*). [58,64–68].

While most CSCCs arise in the context of actinic keratoses (AKs) and in patients with chronic photoaging, the rate of transformation of clinically evident AKs into CSCC is very low (less than 1/1000 per year during a 5-year follow up) and the risk factors and molecular drivers for progression are uncertain. [50,51,69,70]

3.3. Molecular pathogenesis

CSCC are complex genetic tumors with a high tumor mutational burden (median 45.2 mutations per megabase of genomic DNA). [71–73] Most CSCC harbor a spectrum of aberrant genes dominated by UV-induced signatures with characteristic C>T or CC>TT dinucleotide mutations. [50,51] These genetic mutations drive progression, but tumor microenvironmental processes including stromal interactions and local immunomodulation also play key roles in tumor growth and advances in understanding of epigenetic alterations and skin microbiome factors have added further complexity to current concepts of CSCC pathogenesis. [50,51]

In UV-induced CSCC alterations occur in genes responsible for cell cycle control *TP53*, *CDKN2A, NOTCH1* and *NOTCH2*, epigenetic regulators *KMT2C, KMT2D, TET2*, members of the Hippo pathway and of the SWI/SNF chromatin remodeling complex, with inactivating mutations of TGFβ receptor genes [72–74]. Potentially targetable genetic alterations are infrequent but theoretically include PIK3CA, FGFR3, MEK, and EGFR [75,76]. Normal skin accumulates mutations in a linear fashion with cumulative UV exposure, increasing the mutation load and clone size, which correlates with keratinocyte cancer risk. Normal sun-exposed skin and AK have a lower mutation rate than SCC, but most of them already have driver mutations in NOTCH1 and TP53 [77–79]. Other genetic alterations have been identified in CSCCs which are in part or exclusively due to non-UV risk factors. For example, specific genetic signatures have been found in CSCC associated with chronic azathioprine exposure [72]. In RDEB-CSCC a clock-like mutational profile associated with APOBEC deaminase editing has been reported [80], defective DNA mismatch repair with microsatellite instability and accelerated ageing may also contribute and PLK-1 over-expression is a possible candidate for targeted therapy [81].

Data from humans and mouse models suggest that progression of premalignancy to CSCC can be considered a disease continuum from differentiated towards more progenitor-like cellular states. [82] This transition is driven by combinations of genetic mutations involving *TP53*, *NOTCH1, TGFβ*, and the RAS-MAPK signaling cascade, and corresponding transcriptomic analyses showing coordinated downregulation of genes involved in epidermal differentiation and reorganization of the epidermal differentiation complex and epigenetic changes such as in methylation and long non-coding RNAs[83–85]. As CSCC acquires more progenitor-like characteristics, the immune landscape shifts markedly, with an increased presence of innate immune cells (such as dendritic cells, neutrophils, monocytes, and macrophages) and expanded populations of immunoregulatory cells, including regulatory T cells and Th2 lymphocytes. [50,51,86] Notably, advanced progenitor-rich tumors display elevated expression of immune checkpoint molecules like PD-1, TIGIT, LAG3 and CTLA4 [51,86–89] and subpopulations of tumor specific keratinocytes are proposed to act as a hub for interactions with the tumor microenvironment [86]. Cancer-induced nerve injury in perineural invasion also appears to trigger chronic inflammatory signaling via ATF3, IFN-I, and IL-6 pathways in neurons, leading to recruitment of immunosuppressive immune cells in the perineural niche, dampening antitumor immunity. Blocking this pathway could restore immune response and improve anti-PD-1 therapy efficacy. [90]

The importance of the gut microbiome in immune modulation, cancer progression and therapeutic responses is now widely accepted and preliminary evidence suggests a possible association of the cutaneous bacterial microbiome and CSCC progression. [90,91] The skin virome, specifically HPV, has been more extensively investigated and whilst high-risk alpha-HPV E6 and E7 oncoproteins are important carcinogens in anogenital SCC, β-HPV oncoprotein also play a causal but different mechanistic role in cooperation with UV in inherited EV-associated CSCCs. [92] In contrast, a role is not confirmed in non-EV CSCC, and although meta-analyses show that AK/CSCCs harbor HPV DNA more frequently than normal skin with higher viral loads in AK in immunosuppressed versus immunocompetent individuals, they are not usually transcriptionally active [52,58]. A 'hit-and-run' mechanism may be one explanation, but more recent experimental studies show that immune selection by beta-HPV specific CD8 + T cells may control UV-induced, p53-mutated keratinocytes, thus suppressing tumorigenesis. Loss of this protective immunity in immunosuppressed patients may underlie the association with CSCC, independent of keratinocyte-intrinsic oncogenic mechanisms, with potential implications for future therapeutic and preventative approaches.

4. Diagnostic approach in primary CSCC

4.1. Clinical diagnosis

CSCC may have variable clinical presentations depending on tumor size, differentiation, pigmentation, location and skin type. It most commonly arises on sun-exposed sites (head, neck, forearms, dorsum of the hands). The presence of multiple AK represents an established predictor of CSCC development in previously unaffected individuals. [69, 70]

In its early minimally invasive phase, CSCC is usually a small flesh-colored papule or plaque, often with a scaly/hyperkeratotic surface,

not easily distinguishable from a hyperplastic/hyperkeratotic AK or *in situ* SCC (Bowen's disease). It enlarges over time at a variable rate, often with ulceration and crusting. There is usually some induration upon palpation. CSCC may be pigmented, displaying a light to dark brown color, especially in non-white skin populations. Well-differentiated CSCC usually manifests as a hyperkeratotic and verrucous tumor, sometimes with a crateriform appearance. Poorly differentiated CSCC may appear as red-colored non-keratotic tumor, is frequently ulcerated or bleeding and may be difficult to distinguish from other non-pigmented tumors like amelanotic melanoma, Merkel cell carcinoma, atypical fibroxanthoma and other less frequent neoplasms. CSCC may be tender on palpation or spontaneously painful, and this may be a sign of perineural involvement.

LaCSCC may result either from tumors with a particularly aggressive biological potential, from multiple relapses after inadequate initial management of primary CSCC or from neglected lesions. This results in large, indurated tumors that infiltrate the surrounding skin and may invade regional anatomic sites such as the orbits or sinuses with pain and other associated symptoms. The actual tumor extent, infiltration and depth of invasion are not easily predictable by simple clinical examination. In mCSCC, the tumor may present with in-transit, nodal or distant metastasis. Clinical examination of the draining basins and imaging in addition to clinical diagnosis of the primary tumor, has to be considered for staging in CSCC with a risk factor, when metastases need to be ruled out.

The clinical differential diagnosis includes in early cases inflamed seborrheic keratosis, high-grade AK, or keratotic basal cell carcinoma and melanocytic tumors in the case of pigmented CSCC. Less differentiated cases may be confused with amelanotic melanoma, or with rarer neoplasms such as atypical fibroxanthoma, Merkel cell carcinoma or adnexal tumors among others.

Adequate documentation of the cutaneous tumor with measurement of the maximum clinical diameter in the patient's medical file is necessary prior to biopsy and surgery. Recording symptoms and photographic documentation (clinical and, whenever possible, dermatoscopic) is recommended prior to biopsy. Recording the clinical diameter is important as this is a critical parameter in risk classification and staging of CSCC unlike the size recorded in the histological report, which is usually reduced due to the shrinkage during sample-processing techniques.

Keratoacanthoma has been re-classified in the new WHO classification of skin tumors, 5th edition. It is no longer classified as well-differentiated CSCC. It is classified as a clinically and pathologically distinctive, self-limiting squamous tumor of infundibular-trichilemmal origin characterized by rapid growth, stabilization and spontaneous regression often leaving a deep scar. Clinically, keratoacanthoma manifests as a solitary dome-shaped nodule capped with keratin in the center, usually arising on sun-exposed skin areas. [93]

4.2. Dermatoscopy and other non-invasive techniques

Dermatoscopy represents an integral part of clinical examination for the assessment of skin tumors. The dermatoscopic features of CSCC have been extensively investigated and shown to depend on the grade of histopathological differentiation (Figure 3). [94–96] Well-differentiated CSCC is dermatoscopically dominated by a white color that might be present in the form of keratin masses, white structureless areas, white perifollicular circles or white perivascular halos, the latter surrounding hairpin or coiled vessels (Figures 3A, 3C). [95] Each one of these features has a particular diagnostic significance, according to the clinical differential diagnosis. Keratin masses, although very frequent in CSCC, are not specific, since several other, benign and malignant, tumors may display signs of keratinization. [97] White structureless areas, possibly corresponding to extensive acanthosis, were shown to predict CSCC over AK. [98] White circles surrounding follicles which are frequently dilated and filled with keratin plugs, are considered as a specific sign of CSCC over several other nodular tumors, including BCC, seborrheic keratosis, nevi, warts and others. [94] White perivascular halos are seen in CSCC and other keratinizing tumors as well, such as seborrheic keratosis (mainly irritated subtype) or common warts. However, the distribution of the vessels (and the surrounding halos) differs, being irregular in CSCC as compared to the homogeneous arrangement in benign tumors. [99]

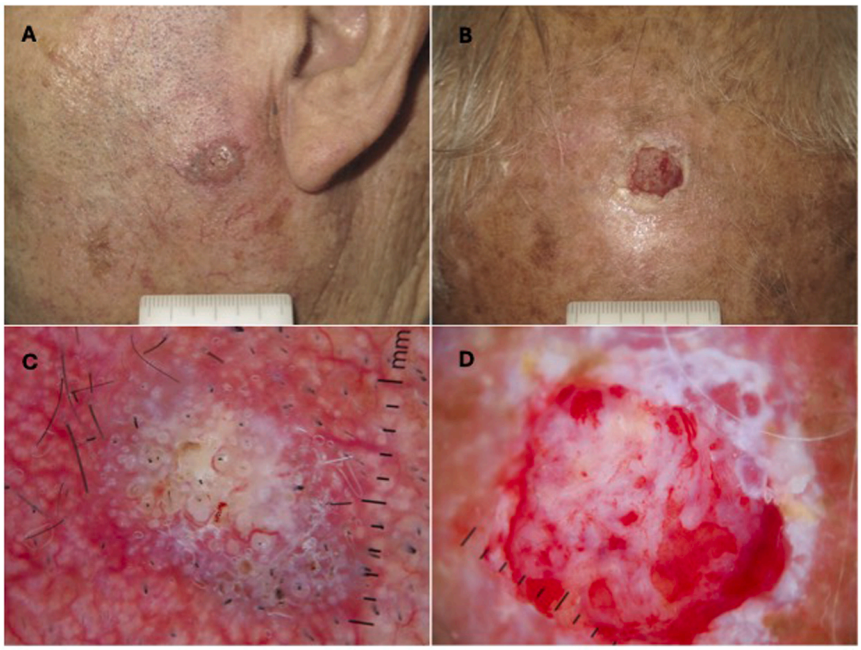

Fig. 3. Clinical (upper panel) and dermatoscopical (lower panel) characteristics of CSCC. **A, C**: A typical example of well-differentiated SCC, dermatoscopically typified by a white predominant color, white perifollicular circles, rosettes and hairpin and linear irregular vessels. **B, D**: A typical example of poor-differentiated SCC, dermatoscopically predominated by a red color and a polymorphous vascular pattern combining coiled, linear irregular and hairpin vessels. (Photos courtesy of Aimilios Lallas).

Table 2
Basic features included in the histopathological report of a CSCC diagnosis (modified from [1,279]).

HISTOPATHOLOGIC REPORT of CSCC		
Type of specimen	☐ punch ☐ shave	☐ excisional
Histologic subtype:	☐ Common ☐ Acantholytic ☐ Spindle cell SCC ☐ Verrucous	☐ Clear cell SCC ☐ Other:
Degree of differentiation	☐ Well differentiated ☐ Moderately differentiated ☐ Poorly differentiated	
Tumor histological thickness*	……. mm	
Invasion beyond subcutaneous fat	☐ No ☐ Yes	
Perineural invasion, in named nerve, nerve caliber ≥ 0.1 mm or beyond dermis, or extensive	☐ No ☐ Yes	
Desmoplasia	☐ No ☐ Yes	
Lymphatic/vascular invasion	☐ No ☐ Yes	
Complete excision -clear histological margins:		
Clear deep margins	☐ No ☐ Yes	
Clear lateral margins	☐ No ☐ Yes	

*Tumor thickness measured from the granular layer of adjacent normal epidermis to the base of the tumor (per 8th TNM classification for carcinomas of the skin)

Keratoacanthoma is typified by a peculiar dermatoscopic pattern consisting of a central mass of keratin surrounded by radially arranged hairpin or coiled vessels, usually surrounded by a white halo. [94]

Poorly differentiated CSCC is substantially different in terms of its dermatoscopic characteristics. It is predominated by a red color, resulting from a rich vascularity composed of dotted, coiled, hairpin, short linear and linear irregular vessels (polymorphous vascular pattern). Hemorrhage is also very frequent and signs of keratinization are absent (Figures 3B, 3D). [95]

Moderately differentiated CSCC displays mixed dermatoscopic criteria, including white-colored and vascular structures. [94–96]

Other non-invasive techniques such as in vivo Reflectance Confocal Microscopy (RCM), Line field confocal OCT (LC-OCT), and Optical Coherence Tomography (OCT) have been used in case series. A possible role for RCM and LC-OCT in clinical practice would be to differentiate CSCCs from BCCs or other skin tumors in clinically and dermoscopically equivocal lesions [100–103]. Although RCM and LC-OCT have good histopathologic correlations (i.e. parakeratosis, atypical keratinocytes, and vascular alterations), the limited laser penetration frequently hampers the full-thickness examination of the tumor. LC-OCT and OCT, in different modalities, provides deeper vertical sections of the tissue, and may thus help to distinguish *in situ* versus early invasive CSCC. [104–106]. However, there is currently insufficient evidence for routine diagnostic use of these non-invasive techniques in the diagnosis of CSCCs.

Recommendation 2. (updated from 2023)

4.3. Histopathological diagnosis

The gold standard for the diagnosis of CSCC is histology. A biopsy or excision and histological confirmation should be performed in all clinically suspected CSCCs. A lower threshold for biopsy of suspicious lesions has been proposed for solid organ transplant recipients. [107] Depending on the size of the tumor and treatment approach, an incisional biopsy, i.e., incision or punch biopsy or an excisional biopsy of the entire lesion can be performed initially. Preoperatively, the longest clinical diameter of the lesion (including the peripheral rim of erythema) should be recorded and noted on the surgery report as it is part of further prognostic staging. [108]

CSCCs consist of atypical epithelial tumor cell formations that extend beyond the epidermis into the underlying dermis. Like the cells of the stratum spinosum of the epidermis, the cells tend to cornify and horny pearls are formed. [109] [110] CSCC may be classified according to the WHO classification of skin tumors (4th edition, 2018) [111] as presented in (Supplementary Table 3). Not yet included in the WHO classification is desmoplastic CSCC with a high proportion of stroma and narrow cell strands, which grows markedly infiltrative, perineurally or perivascular. [112]

Clinical information to be noted on the biopsy as well as the excision request should include patient demographics, the location and the clinical diameter of the lesion as the latter is necessary for staging. The final histopathological report (after excision) should include histological risk factors that are relevant for the staging and prognosis of CSCC including the thickness, depth of invasion, the presence or absence of perineural invasion (PNI), the grade of differentiation, desmoplastic

Clinical and non-invasive diagnosis of the primary CSCC	**Guideline 2026** **Consensus-based statement**
GPP	Clinical diagnosis of the primary CSCC includes description of the lesion, recording of symptoms and location and measurement of the diameter. Photographic documentation is recommended. Dermatoscopy can help in the differential diagnosis of CSCC pre-operatively.
	Strength of consensus: 100%

Table 3
Similarity of risk factors in current guidelines for CSCC with higher risk for poorer prognosis.

Present European Guideline 2026 - Risk for local recurrence or metastasis	NCCN 1.2026 [3] – Very high-risk for local recurrence, metastasis, or disease-specific death	BAD Guideline 2020 [4] - Very high-risk for local recurrence, nodal metastasis, or disease-specific death
Diameter > 20 mm	Diameter > 40 mm	Diameter > 40 mm
Localization on lip/ear/temple	-	-
Thickness > 6 mm	Thickness > 6 mm	Thickness > 6 mm
Invasion beyond subcutaneous fat	Invasion beyond subcutaneous fat	Invasion beyond subcutaneous fat
Bone erosion	-	Bone invasion
Histology: desmoplasia or lymph vascular invasion	Adenosquamous or sarcomatoid in any portion of the tumorLymphatic or vascular involvement	Histological subtype: desmoplastic, adenosquamous, spindle/sarcomatoid/metaplastic
Poor differentiation	Poor differentiation	In-transit metastasis
Immunosuppression	-	Immunosuppression
PNI (histological (in named nerve, nerve ≥ 0.1 mm or beyond dermis, or extensive), symptomatic or radiological)	Histological PNI of a nerve deeper than the dermis or ≥ 0.1 mm	Histological PNI in named nerve, nerve ≥ 0.1 mm or beyond dermis
Positive histological margins	-	One or more involved or close (<1 mm) histological margin in a high-risk tumor

NCCN: National Comprehensive Cancer Network, BAD: British Association of Dermatologists

Table 4
5-year cumulative incidence depending on the number of risk factors included in the Brigham and Women's Hospital (BWH) T staging system (from Ran et al., 2025) [41].

	Local recurrence	Nodal metastasis	Distant metastasis	Disease-specific death
BWH risk factors*	**5-y incidence (95% CI)**	**5-y incidence (95% CI)**	**5-y incidence (95% CI)**	**5-y incidence(95% CI)**
4	33.0% (19.0–47.0)	28.0% (15.0–42.0)	8.4% (2.6–19.0)	25.0% (12.0–39.0)
3	16% (11.0–22.0)	20% (15.0–26.0)	7.9% (4.6–12.0)	11% (6.7–16.0)
2	8.8% (7.0–11.0)	11% (9.2–13)	2.35% (1.4–3.4)	5.4% (4.0–7.0)
1	5.0% (4.1–5.9)	3.6% (2.9–4.4)	1.1% (0.7–1.6)	1.9% (1.4–2.7)
0	1.7% (1.5–2.0)	0.6% (0.4–0.7)	0.2% (0.1–0.3)	0.3% (0.2–0.4)

* Risk factors: diameter of 2 cm or larger, poorly differentiated histology, tumor extension beyond subcutaneous fat, and invasion of a nerve of large caliber.

type and margins status. Additional useful histologic features may be recorded including the histological subtype, lymph vascular invasion and caliber of nerves affected by PNI if ≥ 0.1 mm (Table 2). According to the AJCC 8th edition cancer staging manual, for CSCC, the maximum vertical tumor thickness is measured in mm, from the granular layer of the adjacent normal epidermis, or 'shoulder' of the tumor, to the deepest part (base) of the tumor. [113] The depth of invasion reports the invasion or not into the subcutaneous fat (Clark level V), or even below for more aggressive tumors. For PNI, there is need for standardization in reporting. [114] The histopathological subtypes that have been associated with higher risk for local recurrence or metastases include desmoplastic-type, adenosquamous or sarcomatoid subtypes, and their presence is a NCCN high-risk criterion. The guideline author group proposes the use of a standardized definition for desmoplasia, based on the criteria by Breuninger et al. [112], also used in subsequent studies [42,115,116]. Desmoplastic-type CSCC is diagnosed when at least one third of the tumor specimen shows infiltrating nests of atypical squamous epithelial cells, often featuring single cell strands, surrounded by a distinct sclerotic stromal reaction. The degree of differentiation may classify CSCC into well-differentiated subtypes with low metastatic potential and into poorly differentiated, more aggressive subtypes. [109].

Recommendation 3. (same with recommendation 2023)

Pathology report	Guideline 2026 Consensus-based statement
GPP	If invasive SCC is suspected, a histopathological diagnosis shall be made. The following histological characteristics shall be included in the pathology report: type of specimen (e.g. shave, punch, excisional), histological thickness or depth of invasion, grade of differentiation, presence of perineural invasion, desmoplastic type and margins status. It may also include histologic subtype, lymph vascular invasion and caliber of affected nerves with PNI if ≥0.1 mm.
	Strength of consensus: 100%

5. Risk factors for local recurrence, nodal metastasis, disease-specific death

Higher-risk CSCC is defined as invasive CSCC without locoregional (in transit or nodal) or distant metastasis (staged as N0 and M0), that has features associated with a higher risk for local recurrence and metastasis (Box 4). [117] The assessment of the prognostic risk is particularly relevant for common CSCC to identify the few with a higher risk of local recurrence, metastasis, or death, among all the other low-risk tumors. The ascertainment of risk prognostic factors defining higher risk CSCC

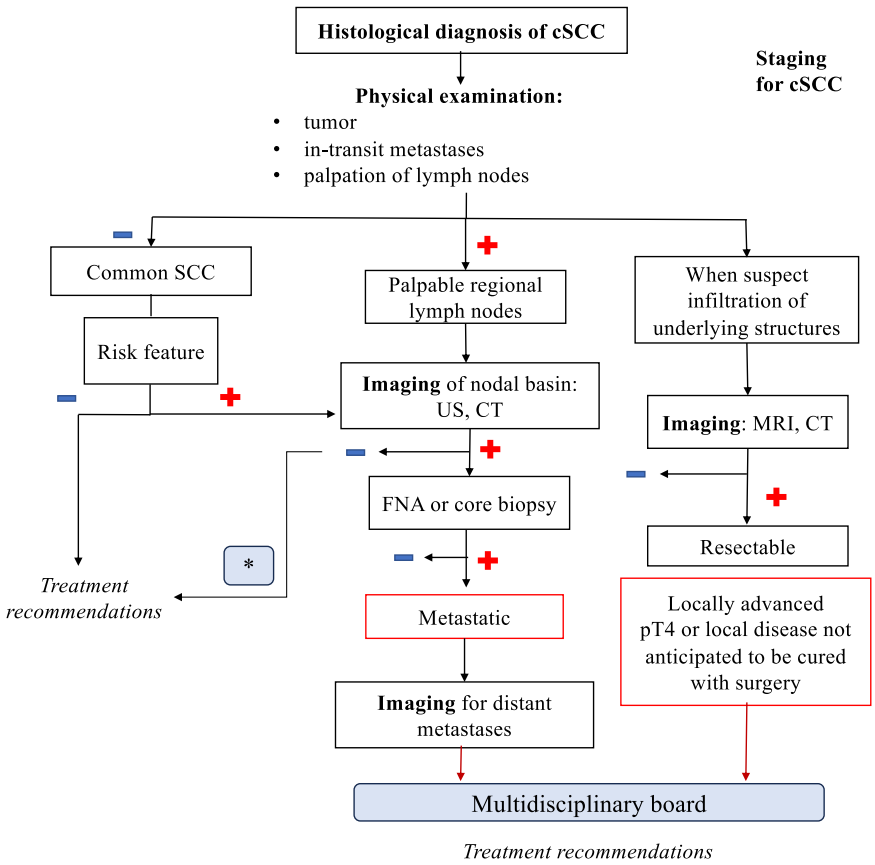

Fig. 4. Algorithm for the diagnostic approach and staging in patients with CSCC (updated from 2023). Strength of consensus: 100%. * Multidisciplinary board is recommended for: 1) recurrent CSCC with non-nodal criteria at high risk of recurrence, as defined in the CPOST trial (clinical and /or radiologic involvement of named nerves, or T4 lesions with invasion of cortical bone or skull base, or recurrent cSCC plus ≥1 additional feature of ≥T3, or poorly differentiated histology and ≥ 20 mm diameter); 2) CSCC BWH T2b/T3, to consider adjuvant RT. BWH T2b: 2–3 risk factors, T3: 4 risk factors or bone invasion. BWH risk factors: diameter ≥ 20 mm, poor differentiation, histological PNI ≥ 0.1 mm, tumor invasion beyond fat. Refer to Guideline 2026 part 2 for detailed treatment recommendations.

has an impact on further management, with more aggressive surgical treatment and more frequent follow up recommendations. The variability of risk factors proposed in current guidelines is due to the variability of reported evidence. [3,4,39,43,112,115,116,118–132] Nevertheless, similar risk factors are proposed in the BAD guidelines, the NCCN guidelines and the European guidelines, regarding the risk associated with local recurrence and nodal metastasis (Table 3).

A list of nine risk factors with evidence-based data portending a greater individual risk of local recurrence or nodal metastasis was proposed in the previous European guidelines 2023 and updated in Box 4. The risk factors may be classified as intrinsic (tumor-related) or extrinsic (patient- and treatment- related). These proposed risk factors include clinical features (tumor diameter, location, symptomatic PNI), histological features (thickness or deep invasion, poor differentiation, desmoplasia, lymph vascular invasion, PNI), radiologic features (radiological perineural spread, bone erosion), immunosuppression, and positive histological margins. Recurrence has not been included as a risk factor for subsequent recurrence, considering that local recurrence is a prognostic outcome and not a risk factor *per se*. In the current update, histological PNI is defined in more detail as PNI in named nerve, nerve ≥ 0.1 mm or beyond dermis, or extensive PNI. [126,133]

Each risk factor may differentially affect the risk of subsequent local recurrence, or nodal metastasis or disease-specific death. [8,42,45,134] (Supplementary Tables 4–7) The 5-year cumulative incidences for these poor prognostic outcomes were practically below 1% for CSCC with one "high-risk" NCCN feature, as shown in a retrospective study in 8727 CSCC patients. There was a higher 5-year cumulative incidence of 9.4% for local recurrence, 7.3% for nodal metastasis, 3.9% for distant metastasis and 10.5% for disease-specific death for CSCC with a "very high-risk" feature according to the NCCN guideline risk groups. (Supplementary Table 8) [135] In the systematic review and meta-analysis by Zakhem et al., a greater than 10% prevalence of local recurrence, nodal metastasis, or disease-specific death was shown only for higher stages, and in particular for AJCC8 T3 or T4, and for BWH T2b or T3 [136] (Supplementary Table 9)

In addition, the number of risk factors should be considered. As shown in the BWH staging system, the presence of 3 or more risk factors (among poor differentiation, large caliber PNI, clinical diameter of 2 cm or larger and invasion beyond subcutaneous tissue) had 2–4 times the risk of a poor outcome compared with tumors with 2 risk factors, even though they would be classified in the same BWH stage T2b. Importantly, a 5-year incidence greater than 10% for a poor prognostic outcome was shown only for CSCCs having 3 or 4 BWH risk factors [41] (Table 4)

A prognostic model (riSCC) developed by Jambusaria Pahlajani et al., provides a personalized estimate of risk of LR, in-transit metastases, nodal metastases, distant metastases, and disease-specific death (DSD) for CSCC, after incorporating patient- and tumor-related risk factors, including age, sex, tumor location, diameter, invasion into fat, differentiation, perineural invasion, lymph vascular invasion, immunosuppression, recurrence and prior surgery type (available as a web-based application at: https://riscc.scoutconsortium.org). [137] Another prediction model by Rentroia-Pacheco et al., includes eight variables (age, sex, number of prior CSCCs, tumor location, diameter, invasion into fat, differentiation, and perineural or lymph vascular invasion) to predict metastatic risk (available as a web-based application at:. https://emc-

dermatology.shinyapps.io/CSCC-abs-met-risk/). [138]

Artificial intelligence analysis is an emerging approach studied to identify CSCC associated with metastasis in whole slide images. [139, 140] In addition, the use of a 40-gene expression profile (GEP) test combined with clinicopathological risk factors has been studied to predict the metastatic risk of CSCC. [141,142] (See Section 6)

Recommendation 4. (updated from 2023)

These data are encouraging but non-randomized. [147] A systematic review/meta-analysis of three studies supports added prognostic value of 40-GEP [141,142,148,149], while critical commentaries highlight limitations (industry sponsorship, retrospective designs, generalizability), underscoring the need for prospective, outcome-driven European studies. [150]

	Guideline 2026 **A list of intrinsic (tumor-related) and extrinsic and patient- and treatment-related) risk factors for local recurrence or nodal metastasis of CSCC**
Grade of recommendation: B	1. tumor diameter (>20 mm) 2. localization on lip/ear/temple 3. thickness >6mm or invasion beyond subcutaneous fat 4. poor differentiation in histology 5. desmoplasia[a] or lymph vascular invasion 6. PNI: histological (in named nerve, nerve ≥ 0.1 mm or beyond dermis, or extensive[b]), symptomatic, or radiological PNI 7. bone erosion 8. immunosuppression[c] 9. positive histological margins Note: The presence of multiple risk factors confers significantly higher risk
Level of evidence: 2	Systematic review and meta-analysis Quality of evidence low to moderate.[7, 8] Retrospective study in patients treated with microscopically controlled surgery[116, 128] Retrospective studies[43, 112, 116, 119-127, 131] Prospective studies[39, 115, 132] Systematic review showing worse prognosis with clinical PNI compared to histological PNI[129] Systematic review on CSCC with bone invasion[130] Scoping review[133]
	Strength of consensus: 100%

[a]Other histologic types have been reported to portend a higher recurrence risk, such as acantholytic or adenosquamous type, but with less supportive evidence.[b]Extensive PNI defined as 5 or more distinct involved nerves per histological section [126][c]Immunosuppression defined as: organ transplantation, HIV, chronic lymphatic leukemia or another hematologic malignancy [42,131]; Immunosuppression not specifically defined in the meta-analyses [7,8]. Zakhem et al., reported organ transplantation and HIV predilecting for a higher risk of local recurrence and organ transplantation for nodal metastases. (Supplementary Tables 4–7)

6. Gene expression profiles (GEP)

The 40-GEP was validated to predict risk of nodal/distant metastasis in high-risk, localized CSCC. [141] Subsequent work shows that integrating 40-GEP with established systems (AJCC-8, BWH, NCCN risk groups) improves discriminatory performance and supports risk-aligned management and risk classification when combined with clinicopathologic factors. [142,143] Multi-center analyses suggest 40-GEP classes correlate with metastasis-free and local-recurrence-free survival and may help specify who benefits from adjuvant radiotherapy (ART) (signal for benefit in Class 2B, potential de-escalation in Class 1). [144–146] Economic modeling indicates possible cost savings when guiding ART.

6.1. How-to-use practice points

Order on primary-tumor tissue after complete histopathologic work-up and conventional risk scoring (e.g., AJCC-8, BWH, NCCN risk groups). Use results in multidisciplinary discussion to refine risk-aligned surveillance and, in carefully selected cases, ART decisions.

Do not base SLNB, margin management, or systemic therapy decisions solely on a GEP result. Evidence in immunosuppressed patients and for predicting outcomes beyond metastasis risk is insufficient. Consider local availability/reimbursement and communicate test limitations (most data from U.S. cohorts; prospective outcome data limited).

Table 5
AJCC 8th edition/UICC pTNM classification 9th edition – for CSCC of head and neck (excluding eyelid for UICC). [10,11].

AJCC 8th/UICC pTNM classification 9th edition – for CSCC of head and neck			
pT – Primary Tumor		**pN – Regional Lymph Nodes**	
TX	Primary tumor cannot be identified	NX	Regional lymph nodes cannot be assessed
T0	No evidence of primary tumor	N0	No regional lymph node metastasis
T1	Tumor ≤ 2 cm in greatest dimension	N1	Metastasis in a single ipsilateral lymph node ≤3 cm in greatest dimension without ENE
T2	Tumor >2 cm and ≤ 4 cm in greatest dimension	N2a	Metastasis in single, ipsilateral lymph node ≤3 cm with ENE or, >3 cm and ≤6 cm in greatest dimension without ENE
T3	Tumor >4 cm in greatest dimension or minor bone erosion or PNI or deep invasion[a,b]	N2b	Metastasis in multiple ipsilateral lymph nodes, all ≤6 cm in greatest dimension without ENE
T4a	Tumor with gross cortical bone/marrow invasion	N2c	Metastasis in bilateral or contralateral lymph node(s), all ≤6 cm in greatest dimension without ENE
T4b	Tumor with axial skeleton invasion including foraminal involvement and vertebral foramen involvement to the epidural space	N3a	Metastasis in a lymph node >6 cm in greatest dimension without ENE
		N3b	Metastasis in a lymph node >3cm in greatest dimension with ENE or multiple ipsilateral, or any contralateral or bilateral node(s) with ENE
		M – Distant Metastasis	
		M0	No distant metastasis
		M1	Distant metastasis

ENE: extranodal extension
[a]In AJCC staging, perineural invasion for T3 classification is defined as tumor cells within the nerve sheath of a nerve lying deeper than the dermis or measuring 0.1 mm or larger in caliber, or presenting with clinical or radiographic involvement of named nerves without skull base invasion or transgression
In UICC 9th edition staging, perineural invasion for T3 classification is defined as tumor cells within the nerve sheath of a nerve lying deeper than the dermis or measuring 0.1 mm or larger in or involvement of five or more nerves per section, without foramen or skull base invasion or transgression.
[b]Deep invasion defined as invasion beyond the subcutaneous fat or > 6 mm (as measured from the granular layer of adjacent normal epidermis to the base of the tumor)
In the case of multiple simultaneous CSCC, the tumor with the highest T category is classified and the number of separate tumors is indicated in parentheses, e.g., T2(5).
N classifications shown in pink include the nodal criteria eligible for adjuvant cemiplimab treatment included in the C-POST trial [280]

Table 6
Staging based on UICC TNM classification 9th edition (2025) for all locations of CSCC excluding eyelid, perianal, vulva and penis, and based on AJCC TNM classification 8th edition (2017) for CSCC of the head and neck [11,12]. (Used with permission of the American College of Surgeons, Chicago, Illinois. The original source for this information is the AJCC Cancer Staging Manual. Copyright © 2025 American College of Surgeons. All rights reserved. May not be reproduced or distributed without the express written permission of ACS. The Content does not reflect the views or interpretations of the Americal College of Surgeons).

Stage 0	Tis	N0	M0
Stage I	T1	N0	M0
Stage II	T2	N0	M0
Stage III	T3	N0	M0
	T1, T2, T3	N1	M0
Stage IVA	T1,T2,T3	N2, N3	M0
	T4	Any N	M0
Stage IVB	Any T	Any N	M1

Table 7
BWH **classification system**[180].

BWH risk factors	
Tumor diameter ≥ 2 cm	
Poorly differentiated histology	
Perineural invasion of nerve(s) ≥ 0.1 mm in caliber	
Invasion beyond subcutaneous fat (excluding bone invasion, which upgrades tumor to BWH stage T3).	
T1	0 risk factors
T2a	1 risk factor
T2b	2–3 risk factors
T3	4 risk factors or bone invasion

6.2. Summary

A validated 40-gene expression profile (40-GEP; commercially: DecisionDx-SCC) can be considered as an adjunct to established clinicopathological risk stratification in selected patients with localized, high-risk CSCC, where the result is likely to change management (e.g., intensity of follow-up imaging, consideration of adjuvant radiation therapy [ART]). GEP must not replace histopathologic assessment or clinical staging and should not be used in low-risk disease. Evidence remains largely retrospective/observational, with growing—but still limited—data on decision impact; therefore, routine use in all patients is not recommended.

7. Staging work-up

Recommendations for the staging work-up of CSCC are shown in Figure 4. Staging for recurrent CSCC is the same as for primary CSCC.

7.1. Physical examination

The diagnosis of CSCC should prompt a complete and careful physical examination including primary tumor, total-body skin examination for the presence of other skin disorders as dermatoheliosis, AK, other skin cancers, chronic inflammatory diseases or signs of diseases with increased risk of CSCC (albinism, xeroderma pigmentosum, etc.) and evaluation of the skin surface of the primary site to rule out in-transit metastasis. [151]

Although the overall risk of lymph node involvement in invasive CSCC is relatively low (up to 5%) [40], all patients should undergo a careful physical examination and palpation of the regional lymphatic basins. [39,152] This approach is sufficient in most low-risk CSCC. In case of a clinically or radiologically detected regional node, a fine needle aspiration cytology (FNAC) is recommended. [153] As an alternative to FNAC, ultrasound-guided core biopsy can be done. [153] (Figure 4).

7.2. Nodal imaging

The need for staging procedures is not well established due to limited data for CSCC from the literature. In patients with common primary CSCC but without palpable lymph nodes imaging for staging is recommended only in patients with CSCC with an EADO risk factor (Box 4) (Figure 4). Imaging methods such as ultrasonography (US), computed tomography scan (CT) or positron emission tomography computed scan (PET-CT) are more sensitive than clinical examination. [152–154] There are limited data on the use of US for nodal metastasis for CSCC. There is some evidence in patients with vulvar CSCC or head/neck SCC. A study of 44 patients with vulvar CSCC and suspected inguinal lymph node metastases reported that US had a higher sensitivity and negative predictive value than CT, but lower specificity and positive predictive value. [155] A meta-analysis (17 studies) in patients with HNSCC (not CSCC) evaluated radiological imaging modalities including US, US-guided FNAC (USgFNAC), CT, and MRI for the detection of lymph node metastases. USgFNAC showed the highest diagnostic odds ratios. US performed significantly better than MRI. Mean sensitivity of 87% was highest for US and specificity of 98% was highest for USgFNAC. However, there were only 2 studies addressing the evaluation of clinically N0 necks. [154] In a retrospective study of baseline and surveillance imaging in 87 high-risk CSCC, disease was detected in 26 (30%) cases of which 18 were subclinical. [156] In a larger retrospective study in 246 high-risk HNCSCC, who underwent baseline ultrasonographic imaging of their lymph nodes (cervical and parotid), this was more sensitive (sensitivity 91%, specificity 78%) than clinical examination alone (sensitivity 50%, specificity 96%) for the detection of lymph node metastasis. The authors concluded that the high sensitivity of US for surveillance detection of nodal metastases should be evaluated against the high rate of false-positive findings, as explored with FNAC biopsy. [157]

As lymph node metastases from CSCC may be more superficial and easier to detect on US than those from mucosal SCC, US performed by experienced physicians may be a cost-effective minimally invasive staging modality for lymph nodes. [152]

7.3. Imaging for laCSCC and distant metastasis

For staging of advanced CSCC, consultation in a multidisciplinary tumor board including a radiologist is mandatory to optimize the use of imaging modalities. In large CSCC or those with possible involvement of underlying structures (orbital invasion, PNI), additional imaging tests, such as CT or MRI may be required to accurately assess the extent of the tumor and the presence of metastatic spread. [129,158–160] MRI is indicated for subtle intracranial disease, perineural spread[119], and imaging of tumor invasion in surrounding soft tissue,. [158,160] CT scan and PET-CT are excellent techniques for the detection of metastatic involvement in distant organs [160] (Figure 4).

One critical question is how these radiological investigations help the therapeutic choice with an impact on the course of the disease. A retrospective study of radiologic imaging for high-stage BWH T2b and T3 CSCC in 45 patients reported mainly CT (79%), PET/CT or MRI, while there was no patient in this cohort that underwent imaging with ultrasound. Imaging changed management in 16 (33%) patients. [161] Another study in 394 CSCCs reported imaging in 35% of tumors due to

staging or treatment planning, and more common imaging modalities were CT (59%), PET/CT (42%), and MRI (37%), while US was used only in one CSCC. Imaging changed management in 47.2% of tumors. [162]

Recommendation 5. (updated from recommendation 2023) [163-166]

Imaging for staging	Guideline 2026 Evidence-based recommendation
Grade of recommendation: B	Patients with low risk CSCC should undergo physical examination only with no need for imaging studies unless indicated by physical examination Patients with primary common CSCC with risk factors* should be staged for non-palpable lymph node involvement, preferably by US or by CT scan. For suspected underlying tissue involvement (bone or soft tissue), CT or MRI should be done to determine extent of local infiltration. LaCSCC should undergo imaging to rule out metastasis. CSCC with nodal involvement should undergo a full skin examination and imaging studies to rule out distant metastatic disease.
Level of evidence: 3	There are no precise clinical guidelines for radiologic evaluation for CSCC [158] Meta-analysis of studies for the detection of lymph nodes metastases in HNSCC (only 2 studies addressing the evaluation of clinically N0 necks)[154] Retrospective studies [155, 157, 161-166] Review of studies on nodal staging of higher-risk CSCC[152]
	Strength of consensus: 100%

* Specification of risk factors for imaging for non-palpable regional nodal metastasis cannot be given, as the independent effect of risk factors has not been consistently reported. CSCC at higher risk for nodal metastasis include (but are not restricted to) AJCC8 T3/T4, BWH T2b/T3 stages.

7.4. Sentinel lymph node biopsy (SLNB)

SLNB for patients with CSCC aims at the detection of occult nodal metastasis with the hope that their early management may improve prognosis [2]. Published systematic reviews report rates of positive SLNB ranging from 0% to 12.3% and up to 29.8%, depending on high-risk criteria. [167–170] In the meta-analysis of Schmitt et al., (19 studies, 130 patients with non-anogenital CSCC) the risk of having a positive sentinel lymph node increased with the number of risk factors, varying from 0% in AJCC T1 tumors to 60% in AJCC T4 tumors, and reached 7.1% (6/85) in BWH T2a, 29.4% (5/17) in BWH T2b and 50% (3/6) in BWH T3 stages. [169]

Regarding CSCC, in the systematic review of Tejera-Vaquerizo et al., in 2018 (23 studies), there were no studies reporting on predictors of SLN involvement or on the prognostic utility of SLN following adjustment for confounders. [168] Two more recent studies revealed a survival benefit of SLNB versus observation. [171,172] In a multicenter study, SLNB was independently associated with a reduced risk of nodal recurrence, disease-specific mortality and all-cause mortality in immunocompetent patients. [171] A retrospective SEER registry study reported a benefit in disease-specific survival of SLNB versus observation for CSCC of the head and neck specifically in patients with multiple risk factors. [172] Nevertheless, clear evidence about the prognostic impact of this recommendation in terms of overall survival is lacking.

Whether a completion lymph node dissection (CLND) after a positive SLN is needed in CSCC, is also a matter of debate due to the absence of good level of evidence. Kesmodel et al., looked at a cohort of 2730 patients identified from the U.S. National Cancer Database (NCDB) with CSCC, of whom 42.3% underwent SLNB (15.4% positive). Patients who underwent CLND demonstrated a non-significant trend towards an improved survival (HR: 0.63, 95% CI: 0.30–1.33, $p = 0.221$). [173]

Huis In 't Veld et al., reported a 5-year disease-specific survival of 52% in patients with CSCC with nodal involvement treated with therapeutic lymph node dissection (of whom 65% also received adjuvant radiotherapy), indicating that lymph node dissection + /- adjuvant radiotherapy can achieve durable survival in approximately half of regionally metastatic CSCC cases. None of these patients, however, had a positive SLNB. [174] It is obvious that despite curative intent surgery + adjuvant radiotherapy, these patients are at high risk of recurrence/metastases, and would potentially benefit from additional effective systemic therapy.

Recommendation 6. (same with recommendation 2023) [175-178]

Sentinel lymph node biopsy (SLNB) for CSCC	Guideline 2026 Evidence-based recommendation
Grade of recommendation: X	SLNB is currently not recommended in the management of CSCC as a standard of care.
Level of evidence: 3	No evidence of prognostic advantage in the detection of occult metastatic disease by SLNB [167, 168, 175] Meta-analysis[168, 176] Systematic review [170, 177, 178]
	Strength of consensus: 100%

8. Staging systems for CSCC

After risk factors have been identified, and the tumor spread has been assessed by physical examination or imaging as appropriate (Figure 4), in the last step, the clinical, histologic and radiologic findings are incorporated into staging systems. [179] The more widely used staging systems include the UICC 9th edition (Union for International Cancer Control) [12] (pathological classification of head/neck CSCC shown in Table 5, clinical and pathological classification of non-head/neck CSCC shown in Supplementary Table 10), the AJCC 8th edition (American Joint Committee on Cancer) (pathological classification and staging shown in Tables 5, 6) [11], and the Brigham and Women's Hospital (BWH) classification system (Table 7) [180]. Notably, the recently released UICC TNM classification and staging 9th edition for CSCC, taking effect as of January 2026, is the same with the previous 8th edition, with two differences: 1) including the lip vermillion border and commissure, and 2) re-defining perineural invasion for T3 as tumor cells within the nerve sheath of a nerve lying deeper than the dermis or measuring 0.1 mm or larger in or involvement of five or more nerves per section, without foramen or skull base invasion or transgression. [10,12] Furthermore, there are two additional staging systems for nodal disease of the head and neck (N1S3 [181] and ITEM [182]) (Supplementary Table 11).

The T stage of the UICC and the AJCC staging system are traditionally based upon the diameter of the tumor, including tumor thickness and perineural invasion as additional risk factors. The BWH system is built up of similar risk factors of tumor diameter ≥ 2 cm, poorly differentiated histology, perineural invasion of nerve(s) ≥ 0.1 mm in caliber, or tumor invasion beyond subcutaneous fat, however the risk category increases with the number of risk factors (Table 7). Unlike the staging systems for Merkel Cell Carcinoma and melanoma, the current staging systems for CSCC do not include satellitosis or in-transit metastases (S-ITM), even though S-ITM has been identified as an independent factor of poorer prognosis. [183,184]

The past years many groups have studied the validity of the various systems for predicting the risk of recurrence or metastasis. Ruiz et.al. compared AJCC and BWH in a population of 680 head and neck CSCC. [185] Higher risk CSCC (AJCC8 (T3/T4) and BWH (T2b/T3) accounted for 121 (18%) vs 63 (9%) of total cases, 17 (71%) vs 16 (70%) of metastases, and 11 (85%) vs 12 (92%) of deaths. The AJCC8 T2 and T3 comprised 23% of cases and had statistically indistinguishable outcomes. The authors report a higher specificity (93%) and positive predictive value (30%) for identifying cases at risk for metastasis or death by BWH. There was no difference for local recurrence (LR) and overall survival (OS). [185] The validation study of Venables et al., investigated the performance of AJCC8, BWH, Tubingen staging systems and Salamanca T3 refinement in predicting metastasis on 887 metastatic CSCC and 887 nonmetastatic CSCC. The BWH system showed the highest specificity (92.8%, 95% confidence interval (CI) 90.8–94.3%) and c-index (0.84, 95% CI 0.82–0.86). [186] They concluded that although BWH showed the highest overall discriminative ability, positive predictive value was low for all staging systems. However, the study does have some limitations like the fact that the authors assume that the diameter criterion of ≥ 0.1 mm must have been met if PNI was reported, so a currently included T3 tumor might be a T1 tumor if PNI is in a nerve < 0.1 mm. In another study Roscher et.al. compared AJCC 7, AJCC 8, BWH and Breuninger's staging system. [187] They found that in the systems used by Breuninger et. al. and the BWH system gave the best result in predicting the risk of metastasis. Using the system by Breuninger et. al., the risk of metastasis was 3-fold for the high co-risk factors (OR: 3.27; 95%CI:1.54–6.96). The BWH staging system gave ORs for metastasis at 6.58 (95%CI: 2.90–14.90) for the T2a category and 35.34 (95%CI: 9.76–128.06) for the T2b category. They also state that current staging systems for CSCC are unsatisfactory in identifying non-selected patients with CSCC at higher risk for metastasis. [187] Other studies reported similar performance for BWH and AJCC8 staging systems for predicting poor outcomes for head/neck and non-head/neck CSCCs, however sensitivity and positive predictive value were low. [188,189]

9. Primary and secondary prevention

Increased UV exposure, both chronic or intermittent, professional or recreational, from natural or artificial sources, in childhood and adulthood is associated with an increased risk for CSCC. As up to 95% of keratinocyte carcinoma can be attributed to UV exposure, photoprotection is the mainstay of the cSCC primary prevention. [17,190,191] Multi-component strategies are considered as most effective for inducing changes in sun exposure behaviors of the population, such as mass media campaigns, environments offering shaded areas, family-oriented behavioral counselling for the early childhood interventions and increasingly, digitally delivered interventions. [192–196] Messages of UV protection, avoidance of sunbathing and tanning are useful but these interventions are struggling with strong social trends valuing pleasure associated with sunbathing and seaside vacations, the perception of suntan considered as aesthetic as well as the false concept that tan is marker of good health. Fair-skinned individuals and persons at high-risk for skin cancer should be advised to avoid sunbathing and the use of tanning beds and to use photo-protection measures starting from an outdoor UV index of 3 or higher. These

measures include seeking shade and avoiding direct sun exposure at solar noon, wearing protective clothing like long-sleeved tops, longer skirts or trousers, wide-brimmed hats and sunglasses and using broad spectrum, UVA and UVB sunscreens with SPF> 30 on the skin areas that cannot be covered by clothes. [191]

Regular use of sunscreen, in addition to other photoprotective measures, has been reported to be effective in reducing the incidence of AK and CSCC in four randomized controlled trials and several non-randomized experimental prospective studies, in the general population and organ transplant recipients. [197–200] However, in two meta-analyses there was no significant effectiveness of sunscreen for preventing either melanoma or nonmelanoma skin cancers, but these included also retrospective studies and studies that analyzed use of only UVB filters. [201,202] Thus, recommendation for regular sunscreen use remains as a third measure for effective sun protection if sun exposure cannot be avoided, on skin areas that cannot be otherwise protected, along with seeking shade and the wearing of clothing to cover the skin. A clear message of strict photoprotection measures should be given to all patients who have already developed CSCC.

Specific situations may require specific preventive and screening measures: In 2010, the International Commission on non-ionizing radiation published a statement on necessary protection of workers against ultraviolet radiation, and in several countries keratinocyte cancer is officially recognized as an occupational disease in outdoor workers. [203,204] Risk-tailored screening procedures were developed for organ transplant recipients in Australia and the UK and similar efforts are under way in the USA. [26,205,206]

Recommendation 7. (updated from 2023) [207-210]

CSCC, compared with placebo-controls in higher risk patients and SOTRs (rate ratio 0.48 (95% CI, 0.26–0.88). [213] There is only one randomized controlled trial in 386 immunocompetent patients with a history of at least two nonmelanoma skin cancers. At 12 months, there was a lower rate of new CSCCs with nicotinamide 500 mg twice daily (reduction by 30% compared to placebo, $p = 0.05$) The positive effect was limited to the active treatment period. [214] This benefit appears to be supported by a large retrospective cohort study in 33822 veterans which found a reduction in the incidence rates of subsequent skin cancers (including CSCC) in patients who received at least 30 days of nicotinamide 2x500mg/day. [215] Nicotinamide is reported safe and generally well tolerated. [213,214]

Oral retinoids studied include acitretin and isotretinoin[211, 216–218], which were shown to be effective in reducing the incidence of new CSCC at least during the duration of treatment in higher risk patients. They are, however, not routinely recommended, due to risk of teratogenicity and the dose-related toxicities that are not well tolerated by patients.[219,220] NSAID use was associated with a reduced risk of CSCC in a meta-analysis (2015), with significant study heterogeneity [221]. In a UK population-based case-control analysis in patients with incident CSCC, there was a slightly decreased risk of CSCC in regular users of any NSAID (OR: 0.89, 95% CI: 0.82–0.97). [222] An Australian cohort study reported inconsistent patterns of association of NSAID use that did not provide convincing evidence that NSAID may reduce subsequent CSCC risk. [223] For anti-oxidants, phytochemicals and selenium, the current evidence is inconclusive. Vitamin D3 plus calcium had no statistically significant effect in reducing new self-reported NMSC in a RCT in 36,282 postmenopausal women. [224] Vitamin D supplementation alone had no significant effect on reduction of CSCC in a RCT of 2259 individuals [225].

Prevention	**Guideline 2026** **Evidence-based recommendation**
GPP	All individuals at high risk for CSCC shall be educated about sun protection measures including avoidance of sun bathing and tanning, the use of shade, protective clothing, regular use of sunscreens and avoidance of artificial UVR tanning.
Level of evidence 1	Measures of photoprotection should be recommended when outdoors UV index is 3 or higher, including seeking shade, the use of protective clothing, regular use of sunscreens on uncovered skin areas. Systematic review of randomized controlled trials, RCT [192-196, 207-210]
Level of evidence 2	Regular use of sunscreens shall be recommended RCT confirmed reduction in CSCC rate. Guidelines. [191, 197-200]
	Strength of consensus: 100%

10. Chemoprevention

Chemoprevention aims to reduce the risk of the development of new CSCC, especially for patients at risk of developing numerous and/or aggressive CSCC. [211] Systemic agents studied for the chemoprevention of CSCC include nicotinamide, retinoids, and non-steroidal anti--inflammatory drugs (NSAIDs). Nicotinamide is a water-soluble form of vitamin B_3 (niacin). It may enhance repair of photodamaged DNA and prevent the immune-inhibitory effects of UVR. [212]. A metanalysis of nicotinamide in skin cancer (552 patients, 5 trials) in 2022, reported that nicotinamide for 6–12 months significantly reduced the rate of new

Topical treatments for chemoprevention include 5% 5-fluorouracil (5-FU) [226] that was shown to be effective in reducing the risk of CSCC requiring surgery by 75% in one RCT. A 2–4 weeks course appeared to have a protective effect for one year, with non-significant effect thereafter. 92% of participants in the fluorouracil group reported erythema and 61% had mild-to-moderate crusting [226] Addition of calcipotriol to 5-FU has been shown to increase the benefit. [227] Topical tretinoin has no significant effect in preventing CSCC. [228]

Recommendation 8. (updated from 2023)

Nicotinamide chemoprevention in immunocompetent patients	Guideline 2026 Evidence-based recommendation
Grade of recommendation C	Nicotinamide 500 mg twice daily may be offered to immunocompetent patients with a history of multiple keratinocyte skin cancers considering the favorable safety profile.
Level of evidence 3	A phase 3, double-blind randomized controlled trial showed significantly lower risk (by 30%) of new CSCC with nicotinamide at 12 months, p=0.05)[214] A large retrospective cohort study showed 21% risk reduction of new CSCC. The risk reduction rose to 53%, when nicotinamide was initiated after the first keratinocyte skin cancer.[215] Systematic review[213]
	Strength of consensus: 96% (25 agree, 1 abstential)

11. Prevention in immunocompromised patients

Current evidence for CSCC prevention in immunocompromised individuals has mainly focused on organ transplant recipients (OTRs), but potential strategies are also relevant to other immunocompromised patient groups. [229–231]

11.1. Primary prevention

Strict photoprotection is usually recommended in immunocompromised individuals. [231] Evidence that sunscreen is effective in CSCC prevention is limited to a non-randomized, open-label trial in Germany which showed that sunscreen was associated with a significant reduction in CSCC at 24 months, although vitamin D levels were lower [200, 232]. As azathioprine is associated with UVA-photosensitivity and mutagenicity, patient should be advised on sunscreen use and sun avoidance year-round. [233] There is evidence that photoprotection advice is better recalled and implemented if provided in a specialist clinical setting. [234,235] Although behavioral interventions (e.g. written material, mobile apps and videos) can improve photoprotective behavior, whether this translates into CSCC prevention has not been confirmed. [230]

11.2. Secondary prevention

This has mainly focused on treatment of premalignancy, systemic chemoprevention, modification of immunosuppression and skin cancer surveillance. Evidence for guiding treatment selection, thresholds for initiation and optimal sequencing of these strategies in immunocompromised individuals is mainly based on expert consensus. [231,236]

11.2.1. Topical chemoprevention

Most RCTs of lesion and field-directed AK treatments have excluded immunocompromised individuals and current guidance is largely based on expert consensus. [231,236] In a Delphi study which considered interventions for actinic damage, consensus was reached for use of cryotherapy for scattered AK; field therapy (no consensus on type) for grouped AK; and combination lesion-directed and 5-fluorouracil-based field therapy for field cancerized skin. [231] However, the effectiveness of these recommendations in CSCC prevention requires validation in future prospective studies.

11.2.2. Systemic chemoprevention

Retinoids

Three RCTs confirm that systemic retinoids confer a significant chemopreventive effect in OTRs [237–239], with an estimated 54% overall reduction in CSCC [240] and case series also signal a chemopreventive effect in other immunocompromised patients. [241] The risk of teratogenicity and mandatory pregnancy prevention with double reliable contraception (during treatment and for 3 years after acitretin discontinuation) is an important consideration for females with pregnancy potential. Dose limiting adverse effects include cheilitis, xerosis, alopecia, headache, arthralgia and hyperlipidemia [240,242–244] and a rebound in CSCCs 3–4 months after discontinuation is common and retinoid chemoprevention should therefore be viewed as long term strategy and requires laboratory monitoring [219,242]. However, there is no clear consensus regarding when to initiate retinoid chemoprevention. [231] Optimal dosing regimens are also uncertain although acitretin is usually started at low dose (e.g., 10 mg/day) and escalated as tolerated to an effective maintenance dose (e.g., 25–30 mg/day) [231]

Nicotinamide

Nicotinamide is a vitamin B3 derivative and has few adverse effects, does not require laboratory monitoring and is low-cost. The 2015 ONTRAC phase 3 RCT in immunocompetent individuals with at least 2 KCs in the preceding 5 years in Australia demonstrated a 30% reduction in the incidence of new CSCC with nicotinamide 500 mg twice daily over 12-months compared with placebo, but evidence in immunocompromised individuals is inconsistent to date. [214] Two small prospective RCTs in OTRs provided a signal of chemopreventive efficacy but were underpowered [245,246]. The 2023 ONTRANS phase 3 RCT in 158 OTRs in Australia failed to confirm a statistically significant reduction in CSCC compared with placebo although a trend towards reduced CSCC incidence was seen and it has been argued that possible benefit was underpowered due to low recruitment. [247,248] Although a subsequent small, retrospective, single center OTR observational cohort study showed benefit [249], a larger multicenter observational retrospective study in a Veterans Affairs OTR cohort failed to confirm an overall chemopreventive effect, although there was a reduction in CSCC incidence if initiated after the first 1–2 KCs. [215] Given the conflicting data, prospective RCT evidence from the ongoing SPRINTR trial in Canada are now awaited (NCT05955924).

Capecitabine

Limited observational data for this 5-fluorouracil prodrug suggest it has a CSCC chemopreventive effect in OTRs: [250–253]. However, dose-limiting side effects (fatigue, hand-foot syndrome, diarrhea, nausea/vomiting, mucositis, anemia, hyperuricemia/gout) resulted in up to 43% of patients discontinuing treatment and further clinical trials are required to establish optimal patient selection, dosing, safety and long-term efficacy [253,254].

Modification of immunosuppression (MOI)

This is a potential approach to secondary CSCC prevention and is relevant in the context of pre- and post-transplant CSCC, and re-transplantation. [231,255] It remains uncertain when and how MOI should be undertaken and it requires a multidisciplinary approach, with consideration of factors including type of allograft, risk and implications of rejection, prognosis of individual tumors, and patient preferences [231].

There is no robust measure for overall immunosuppressive intensity to guide decision-making and relatively limited evidence on relative risk of specific drug classes. [231] Of the anti-proliferative agents, azathioprine confers an increased CSCC risk compared to mycophenolate but there is less evidence for significant differences between calcineurin inhibitor (CNIs) [256,257] and uncertain whether the selective T-cell costimulatory blockade agent, belatacept, is associated with a lower risk of CSCC [258] However, several RCTs have demonstrated that conversion from CNIs to mTOR inhibitors after the first post-transplant CSCC reduces risk of subsequent CSCC, with a non-significant reduction if undertaken after more than one CSCC, but do not have a primary protective effect [259,260]. A reduction of 56% in keratinocyte cancers with mTORi use was confirmed in a meta-analysis of 5876 OTR from 21 RCTs; an overall increase in mortality was also reported [261], although this may reflect the higher doses of mTORi used in early trials [262]. Adverse effects of mTORi including delayed wound healing, diarrhoea, mucositis, proteinuria and peripheral oedema, lead to high rates of discontinuation [263].

Sequencing of CSCC secondary prevention approaches

At what stage, in whom and in what order possible preventive interventions should be introduced remains an area of considerable clinical uncertainty. [231,236,264] In Delphi expert consensus study, for OTR CSCC prevention, consensus was reached on use of photoprotection and topical treatment in OTRs with photodamage, AK and field change, but no consensus was reached on prevention strategies after the first invasive CSCC, with concerns regarding adverse effects of mTORi conversion despite RCT evidence supporting this. [231] In OTRs with multiple CSCC accruing at a low rate, MOI was recommended together with introduction of systemic chemoprevention, although no agreement was reached as to how MOI should be undertaken and which systemic chemopreventive agent should be started: With higher rates of CSCC accrual (>10/year), acitretin was recommended and was similarly first choice in the event of a high-risk CSCC developing. [231]

11.3. Surveillance

Expert consensus recommends that patients should be counselled on self-monitoring and provided with access to rapid evaluation of suspicious skin lesions. [231,265] Many post-transplant clinical guidelines advise that all OTRs should be offered skin cancer surveillance at least annually [266], but its evidence supporting effectiveness on CSCC prevention is sparse [267,268] and the cost-effectiveness of pre-transplantation screening strategies has similarly yet to be validated. [230] More risk-stratified approaches for timing of baseline surveillance using the SUNTRAC tool [268–271] and subsequent surveillance pre- and post-CSCC [206,265] have been proposed. Most evidence on risk stratification, screening and surveillance in immunocompromised patient cohorts has focused on OTR, but other immunocompromised groups may also potentially benefit, and this has been particularly promoted in patients with CLL and inflammatory bowel disease. [30,272–274]

Recommendation 9. (updated from 2023) [275-278]

Prevention of CSCC in solid organ transplant recipients	**Guideline 2026** **Evidence-based recommendation**
GPP	Education about routine skin surveillance, sun protection measures and use of sunscreen should be recommended. Oral retinoids should be considered in OTRs with one or more CSCC Conversion to mTOR inhibitors in OTRs with one or more CSCC should be discussed with transplant physicians. Modification of immunosuppression in OTRs with one or more CSCC can be discussed with transplant physicians.
Level of evidence: 4	Sunscreen: one non-randomized case-control study of sunscreen in OTRs showed a reduction of CSCC [200].
Level of evidence: 3	Oral retinoids: RCTs and systematic reviews confirm CSCC prevention in small numbers of OTRs [237-240].
Level of evidence: 2	Conversion to mTOR inhibitors: CSCC prevention shown in RCTs and systematic reviews [259-263, 275-278].
Level of evidence: 3	Modification of immunosuppression: non-randomized evidence that CSCC may be reduced in OTRs by modification of immunosuppression [231, 256-258].
	Strength of consensus: 100%

Summarizing box of recommendations

Practice points	Recommendation	GOR
1. Definitions and classifications of invasive CSCC	Common primary CSCC shall be classified as low-risk or higher-risk. Higher-risk CSCC is defined as invasive CSCC without locoregional (in transit or regional nodal metastasis) or distant metastasis (staged as N0 and M0), that has features associated with a higher risk for local recurrence and metastasis (Box 4). Advanced CSCC shall be classified as locally advanced (LaCSCC), locoregional metastatic or distant metastatic CSCC (mCSCC). LaCSCC shall be defined as non-metastatic CSCC, not amenable to either surgery or radiotherapy with reasonable hope for cure, because of multiple recurrences, large size, bone erosion or invasion, or deep infiltration beyond subcutaneous tissue into muscle or along nerves, or else tumors in which curative resection would result in unacceptable complications, morbidity or deformity.	A
2. Clinical and non-invasive diagnosis of the primary CSCC	Clinical diagnosis of the primary CSCC includes description of the lesion, recording of symptoms and location and measurement of the diameter. Photographic documentation is recommended. Dermatoscopy can help in the differential diagnosis of CSCC pre-operatively.	GPP
3. Pathology report	If invasive SCC is suspected, a histopathological diagnosis shall be made. The following histological characteristics shall be included in the pathology report: type of specimen (e.g. shave, punch, excisional), histological thickness or depth of invasion, grade of differentiation, presence of perineural invasion, desmoplastic type and margins status. It may also include histologic subtype, lymph vascular invasion and caliber of affected nerves with PNI if ≥0.1 mm.	GPP
4. Risk factors for local recurrence or nodal metastasis	1. tumor diameter (>20 mm) 2. localization on lip/ear/temple 3. thickness >6mm or invasion beyond subcutaneous fat 4. poor differentiation in histology 5. desmoplasia[a] or lymph vascular invasion 6. PNI: histological (in named nerve, nerve ≥ 0.1 mm or beyond dermis, or extensive[b]), symptomatic, or radiological PNI 7. bone erosion 8. immunosuppression[c] 9. positive histological margins Note: The presence of multiple risk factors confers significantly higher risk	B

(continued on next page)

(*continued*)

5. Imaging for staging	Patients with low risk CSCC should undergo physical examination only with no need for imaging studies unless indicated by physical examination Patients with primary common CSCC with risk factors* should be staged for non-palpable lymph node involvement, preferably by US or by CT scan. For suspected underlying tissue involvement (bone or soft tissue), CT or MRI should be done to determine extent of local infiltration. LaCSCC should undergo imaging to rule out metastasis. CSCC with nodal involvement should undergo a full skin examination and imaging studies to rule out distant metastatic disease.	B
6. SLNB	SLNB is currently not recommended in the management of CSCC as a standard of care.	X
7. Prevention	All individuals at high risk for CSCC shall be educated about sun protection measures including avoidance of sun bathing and tanning, the use of shade, protective clothing, regular use of sunscreens and avoidance of artificial UVR tanning.	GPP
8. Nicotinamide chemoprevention in immunocompetent patients	Nicotinamide 500 mg twice daily may be offered to immunocompetent patients with a history of multiple keratinocyte skin cancers considering the favorable safety profile.	A
9. Prevention of CSCC in solid organ transplant recipients	Education about routine skin surveillance, sun protection measures and use of sunscreen should be recommended. Oral retinoids should be considered in OTRs with one or more CSCC. Conversion to mTOR inhibitors in OTRs with one or more CSCC should be discussed with transplant physicians. Modification of immunosuppression in OTRs with one or more CSCC can be discussed with transplant physicians.	GPP

GOR: grade of recommendation, GPP: good clinical practice point, SLNB: sentinel lymph node biopsy* Specification of risk factors for imaging for non-palpable regional nodal metastasis cannot be given, as the independent effect of risk factors has not been consistently reported. CSCC at higher risk for nodal metastasis include (but are not restricted to) AJCC8 T3/T4, BWH T2b/T3 stages.

Funding Sources

The development of the current set of guidelines was supported solely by funds of the EADO which were used to mainly support the consensus meeting without honoraria and without reimbursement of travel costs.

CRediT authorship contribution statement

Peter Koelblinger: Writing – original draft, Writing – review & editing, Visualization. **Kelleners Smeets Nicole:** Writing – original draft, Writing – review & editing, Visualization. **Roland Kaufmann:** Writing – original draft, Writing – review & editing, Visualization. **Josep Malvehy:** Writing – original draft, Writing – review & editing, Visualization, Conceptualization. **Lidija Kandolf-Sekulovic:** Writing – original draft, Writing – review & editing, Visualization. **Mario Mandala:** Writing – original draft, Writing – review & editing, Visualization. **Christoph Hoeller:** Writing – original draft, Writing – review & editing, Visualization. **Paul Lorigan:** Writing – original draft, Writing – review & editing, Visualization. **Axel Hauschild:** Writing – original draft, Writing – review & editing, Visualization. **Eggermont Alexander:** Writing – original draft, Writing – review & editing, Visualization. **Harwood Catherine:** Writing – original draft, Writing – review & editing, Visualization. **Veronique del Marmol:** Writing – original draft, Writing – review & editing, Visualization. **Konstantinos Liopyris:** Writing – original draft, Writing – review & editing, Visualization. **Ulrike Leiter:** Writing – original draft, Writing – review & editing, Visualization. **Aimilios Lallas:** Writing – original draft, Writing – review & editing, Visualization. **Reinhard Dummer:** Writing – original draft, Writing – review & editing, Visualization. **Brigitte Dreno:** Writing – original draft, Writing – review & editing, Visualization. **Myrto Trakatelli:** Writing – original draft, Writing – review & editing, Visualization. **Veronique Bataille:** Writing – original draft, Writing – review & editing, Visualization. **Luca Tagliaferri:** Writing – original draft, Writing – review & editing, Visualization. **Teresa Amaral:** Writing – original draft, Writing – review & editing, Visualization. **Philippe Saiag:** Writing – original

draft, Writing – review & editing, Visualization. **Celeste Lebbe:** Writing – original draft, Writing – review & editing, Visualization. **Ketty Peris:** Writing – original draft, Writing – review & editing, Visualization. **Claus Garbe:** Conceptualization, Writing – original draft, Writing – review & editing, Visualization. **Giovanni Pellacani:** Writing – original draft, Writing – review & editing, Visualization. **Clio Dessinioti:** Writing – original draft, Writing – review & editing, Visualization, Conceptualization, Supervision. **Stratigos Alexander:** Conceptualization, Supervision, Writing – original draft, Writing – review & editing, Visualization. **Moreno Ramirez David:** Writing – original draft, Writing – review & editing, Visualization. **Alexander C.J. van Akkooi:** Writing – original draft, Writing – review & editing, Visualization. **Christoffer Gebhardt:** Writing – original draft, Writing – review & editing, Visualization. **Ana Maria Forsea:** Writing – original draft, Writing – review & editing, Visualization. **Petr Arenberger:** Writing – original draft, Writing – review & editing, Visualization. **Maria Concetta Fargnoli:** Writing – original draft, Writing – review & editing, Visualization. **Iris Zalaudek:** Writing – original draft, Writing – review & editing, Visualization. **Ricardo Vieira:** Writing – original draft, Writing – review & editing, Visualization.

Declaration of Competing Interest

The author Alexander Eggermont is an Editor of the EJC and was not involved in the editorial review or the decision to publish this article.

The authors declare the following financial interests/personal relationships which may be considered as potential competing interests: 1. Alexander J. Stratigos: reports a relationship with Regeneron Pharmaceuticals Inc that includes: consulting or advisory, and lecture fees. Alexandros Stratigos reports a relationship with Replimune Ltd that includes: lecture fees. Alexandros Stratigos reports a relationship with Merck & Co Inc that includes: funding grants. Alexandros Stratigos reports a relationship with Genesis Pharma that includes: funding grants. Alexandros Stratigos reports a relationship with L' Oreal that includes: funding grants. 2. Clio Dessinioti: None. 3. Claus Garbe reports receipt of honoraria or consultation fees: personal fees from CeCaVa, from MSD, from NeraCare, and from Philogen. 4. Celeste Lebbe: reports research grants (Pierre Fabre, Novartis), participation at advisory board meetings (Pierre Fabre, Regeneron, MSD, BMS). 5. Teresa Amaral: reports personal fees for advisory board membership from Delcath and Philogen; personal fees as an invited speaker from Bristol Myers Squibb (BMS), Medscape, Neracare, Novartis and Pierre Fabre; personal fees for a writing engagement from CeCaVa and Medtrix; institutional fees as local principal investigator (PI) from Agenus Inc., AstraZeneca, BioNTech, BMS, HUYA Bioscience, Immunocore, IO Biotech, MSD, Pfizer, Philogen, Regeneron, Roche and University Hospital Essen; institutional fees as coordinating PI from Unicancer; institutional research grants from iFIT and Novartis; institutional funding from MNI - Naturwissenschaftliches und Medizinisches Institut, Neracare, Novartis, Pascoe, Sanofi and Skyline-Dx; non-remunerated membership of the American Society of Clinical Oncology (ASCO) and the Portuguese Society for Medical Oncology; a role as clinical expert in the area of medical oncology for Infarmed, and a role as an expert for SGA-Oncology at EMA outside the submitted work. 6. Veronique Bataille: None. 7. Brigitte Dreno: None 8. Reinhard Dummer has intermittent, project focused consulting and/or advisory relationships with Novartis, Merck Sharp & Dhome (MSD), Bristol-Myers Squibb (BMS), Roche, Amgen, Takeda, Pierre Fabre, Sun Pharma, Sanofi, Catalym, Second Genome, Regeneron, T3 Pharma, MaxiVAX SA, Pfizer, Simcere and Iovance outside the submitted work. Senior medical advisor Oncobit. Participation on Derma2go. 9. Maria Concetta Fargnoli reports a relationship with MSD Italy that includes: consulting or advisory and speaking and lecture fees. 10. Ana Maria Forsea: None. 11. Christoph Gebhardt: reports research support by BMS, Delcath, Novartis, Pierre-Fabre, Regeneron and Sanofi, member of the advisory board of Almirall, Beiersdorf, BioNTech, BMS, Delcath, ImCheck, Immatics, Immunocore, Moderna, MSD, Novartis, Pierre-Fabre, Regeneron, Sanofi, SUN Pharma, SkylineDx, honoraria by Almirall, Bioderma, Biofrontera, BMS, Delcath, Immunocore, Medscape, MSD, Novartis, Onkowissen, Pierre-Fabre, Regeneron, Sanofi, SUN Pharma, SkylineDx, travel expenses by BMS, Pierre-Fabre, SUN Pharma, and Co-Founder of Dermagnostix and Dermagnostix R&D.12. Catherine A. Harwood: None. 13. Axel Hauschild: reports personal fees for advisory board membership from Agenus, BMS, Dermagnostix, Eisai, Highlight Therapeutics, Immunocore, Incyte, IO Biotech, Merck Pfizer, MSD, Neracare, Novartis, Philogen, Pierre Fabre, Regeneron, Replimune, Roche, Sanofi, Seagen, Xenthera; institutional funding as local or coordinating PI from Agenus, Amgen, BMS, MSD, Novartis, Philogen, Pierre Fabre and Regeneron. 14. Christoph Hoeller: none. 15. Lidija Kandolf-Sekulovic none. 16. Roland Kaufmann: Institutional research grants (clinical trials) from AbbVie, Almirall, Amgen, Astra Zeneca, Biontech, BMS, Fraunhofer Institute, Galderma, Incyte, Janssen, Leo, Lilly, Merck, MSD, Novartis, Pfizer, Regeneron, Roche, Advisory Board and Honoraria from Leo and Regeneron. 17. Nicole WJ Kelleners-Smeets: None. 18. Peter Koelblinger: reports a relationship with Bristol-Myers Squibb Company that includes: consulting or advisory, paid expert testimony, speaking and lecture fees, and travel reimbursement. Peter Koelblinger reports a relationship with MSD Merck Sharp & Dohme AG that includes: consulting or advisory and speaking and lecture fees. Peter Koelblinger reports a relationship with Pierre Fabre SA that includes: speaking and lecture fees and travel reimbursement. Peter Koelblinger reports a relationship with Immunocore Ireland Limited that includes: speaking and lecture fees. 19. Aimilios Lallas: Institutional research grants (clinical trials) from AbbVie, BMS, Incyte, Lilly, Merck, MSD, Regeneron, Advisory Board and Honoraria from Fotofinder, Lilly and Regeneron. 20. Ulrike Leiter reports a relationship with Regeneron Pharmaceuticals Inc that includes: consulting or advisory, funding grants, and speaking and lecture fees. Ulrike Leiter reports a relationship with Sun Pharmaceutical Industries Ltd that includes: consulting or advisory, speaking and lecture fees, and travel reimbursement. Ulrike Leiter reports a relationship with Pierre Fabre Médicament SAS that includes: consulting or advisory, speaking and lecture fees, and travel reimbursement. Ulrike Leiter reports a relationship with Almirall Hermal GmbH that includes: consulting or advisory and speaking and lecture fees. 21. Konstantinos Liopyris : none. 22. Veronique del Marmol : none. 23. David Moreno-Ramirez : none. 24. Giovanni Pellacani: none. 25. Ketty Peris: reports research grants (Sanofi, Novartis, Abbvie, Almirall), participation at advisory board meetings (Almirall, Lilly, Novartis, Sun-Pharma, Leo-Pharma, Philogen, Pierre Fabre, Regeneron, Sanofi, Sun Pharma, UCB). 26. Philippe Saiag: reports a relationship with Merck Sharp & Dohme Corp that includes: board membership and travel reimbursement. Philippe Saiag reports a relationship with Regeneron Pharmaceuticals Inc that includes: board membership and travel reimbursement. Philippe Saiag reports a relationship with Bristol-Myers Squibb Company that includes:. 27. Luca Tagliaferri: reports a relationship with Elekta that includes: funding grants and speaking and lecture fees. Luca Tagliaferri reports a relationship with IGEA SpA that includes: funding grants and travel reimbursement. Luca Tagliaferri reports a relationship with Sun Pharmaceutical Industries Ltd that includes: consulting or advisory, non-financial support, speaking and lecture fees, and travel reimbursement. Luca Tagliaferri reports a relationship with Sanofi that includes: speaking and lecture fees and travel reimbursement. Luca Tagliaferri reports a relationship with Roche that includes: speaking and lecture fees. Luca Tagliaferri reports a relationship with Nanobiotix SA that includes: consulting or advisory. Luca Tagliaferri reports a relationship with Novartis that includes: consulting or advisory, funding grants, and travel reimbursement. Luca Tagliaferri reports a relationship with Eisai Inc that includes: consulting or advisory, speaking and lecture fees, and travel reimbursement. Luca Tagliaferri reports a relationship with Bayer Corporation that includes: consulting or advisory and funding grants. Luca Tagliaferri reports a relationship with Boston Scientific Corporation that includes: funding grants. Luca Tagliaferri reports a relationship with Ipsen Pharma SAS that includes: consulting or advisory and

funding grants. Luca Tagliaferri reports a relationship with Pfizer that includes: consulting or advisory, funding grants, and speaking and lecture fees. Luca Tagliaferri reports a relationship with Regeneron Pharmaceuticals Inc that includes: consulting or advisory, speaking and lecture fees, and travel reimbursement. Luca Tagliaferri reports a relationship with MSD Italy that includes: consulting or advisory and funding grants. Luca Tagliaferri reports a relationship with AstraZeneca that includes: consulting or advisory and funding grants. Luca Tagliaferri reports a relationship with Johnson and Johnson that includes: funding grants, speaking and lecture fees, and travel reimbursement. Luca Tagliaferri reports a relationship with Astellas Pharma Inc that includes: funding grants, speaking and lecture fees, and travel reimbursement. Luca Tagliaferri has patent TIMER applicator licensed to 102017000067474. 28. Myrto Trakatelli: reports a relationship with Janssen, UCB, Abbvie, Genesis Pharma, Pierre Farbre Greece, EADV courses that includes: speaking and lecture fees and travel reimbursement. 29. Ricardo Vieira: none. 30. Iris Zalaudek: none. 31. Petr Arenberger: none. 32. Alexander C.J. van Akkooi: reports a relationship with Adium Pharma SA that includes: speaking and lecture fees. Alexander C.J. van Akkooi reports a relationship with Bristol-Myers Squibb that includes: consulting or advisory and speaking and lecture fees. Alexander C.J. van Akkooi reports a relationship with Daiichi Sankyo Inc that includes: consulting or advisory. Alexander C.J. van Akkooi reports a relationship with Genmab BV that includes: consulting or advisory. Alexander C.J. van Akkooi reports a relationship with Menarini Silicon Biosystems Inc that includes: consulting or advisory. Alexander C.J. van Akkooi reports a relationship with MSD Merck Sharp & Dohme AG that includes: consulting or advisory and speaking and lecture fees. Alexander C.J. van Akkooi reports a relationship with NeraCare GmbH that includes: consulting or advisory. Alexander C.J. van Akkooi reports a relationship with Novartis that includes: speaking and lecture fees. Alexander C.J. van Akkooi reports a relationship with Pierre Fabre SA that includes: consulting or advisory and speaking and lecture fees. Alexander C.J. van Akkooi reports a relationship with Regeneron Pharmaceuticals Inc that includes: consulting or advisory and speaking and lecture fees. Alexander C.J. van Akkooi reports a relationship with Replimune Ltd that includes: consulting or advisory and speaking and lecture fees. Alexander C.J. van Akkooi reports a relationship with Sirius Medical Systems BV that includes: consulting or advisory and speaking and lecture fees. Alexander C.J. van Akkooi reports a relationship with SkylineDx BV that includes: consulting or advisory, funding grants, and speaking and lecture fees. NHMRC Clinical Trials and Cohort Studies Grant 2043780 for the MSLT-3 trial. 33. Alexander M. M Eggermont reports stock and other ownership interests - IO Biotech, Sairopa B.V., SkylineDx B.V.; Honoraria Consulting or Scientific Advisory Role - Agenus, Boehringer Ingelheim GmbH, BioInvent, BioNTech, Brenus, CatalYm GmbH, Cryptomedix, EBT-Phamaceuticals, Egle, ImmTech, Eurobio, IO Biotech, IQVIA, Merck KgA, Merck&Co, Moderna, MSD, Oncolytics, Pierre Fabre, QBiotics, Regeneron, Sairopa BV, Secarna GmbH, SkylineDx BV, Thermosome GmbH, Trained Immunity Therapeutics Discovery; Vector Sciences. Data safety monitoring board: BioNTech, IQVIA, Pfizer. 34. Paul Lorigan reports funding for research: Pierre Fabre and BMS, and personal fees for advisory board and speakers bureau: Regeneron, Pierre Fabre, BMS, MSD, Iovance, MLA Diagnostics. 35. Mario Mandala reports financial support was provided by University of Perugia Department of Medicine. Mario Mandala reports a relationship with University of Perugia Department of Medicine that includes: non-financial support. Mario Mandala has patent not applicable pending to not applicable. The Co-author is employed at the University of Perugia as Professor and there are no competing interest that have been used to complete the present project. 36. Josep Malvehy reports a relationship with Regeneron Pharmaceuticals Inc that includes: consulting or advisory and travel reimbursement. Josep Malvehy reports a relationship with Sunpharma that includes: consulting or advisory, speaking and lecture fees, and travel reimbursement.

Appendix A. Supporting information

Supplementary data associated with this article can be found in the online version at doi:10.1016/j.ejca.2026.116763.

References

[1] Stratigos AJ, Garbe C, Dessinioti C, Lebbe C, van Akkooi A, Bataille V, et al. European consensus-based interdisciplinary guideline for invasive cutaneous squamous cell carcinoma. Part 1: Diagnostics and prevention-Update 2023. Eur J Cancer 2023;193:113251.

[2] Stratigos AJ, Garbe C, Dessinioti C, Lebbe C, van Akkooi A, Bataille V, et al. European consensus-based interdisciplinary guideline for invasive cutaneous squamous cell carcinoma: Part 2. Treatment-Update 2023. Eur J Cancer 2023; 193:113252.

[3] Bordeaux J., Nghiem P., Aasi S.Z., Alam M., Amini A., Bolotin D., et al. National Comprehensive Cancer Network (NCCN) Clinical Practice Guidelines in Oncology. Squamous cell skin cancer. Version 1.2026. Available at: ⟨https://www.nccn.org/professionals/physician_gls/pdf/squamous.pdf⟩. Accessed on October 8, 2025. 2026.

[4] Keohane SG, Botting J, Budny PG, Dolan OM, Fife K, Harwood CA, et al. British Association of Dermatologists guidelines for the management of people with cutaneous squamous cell carcinoma 2020. Br J Dermatol 2021;184:401–14.

[5] Brouwers MC, Kho ME, Browman GP, Burgers JS, Cluzeau F, Feder G, et al. AGREE II: advancing guideline development, reporting and evaluation in health care. CMAJ 2010;182:E839–42.

[6] Howick J., Chalmers I., Glasziou P., Greenhalgh T., Heneghan C., Liberati A., et al. The Oxford Levels of Evidence 2 Available at: ⟨https://wwwcebmoxacuk/resources/levels-of-evidence/ocebm-levels-of-evidence⟩ Accessed on July 17, 2022: Oxford Center for Evifdence-Based Medicine.

[7] Thompson AK, Kelley BF, Prokop LJ, Murad MH, Baum CL. Risk Factors for Cutaneous Squamous Cell Carcinoma Recurrence, Metastasis, and Disease-Specific Death: A Systematic Review and Meta-analysis. JAMA Dermatol 2016; 152:419–28.

[8] Zakhem GA, Pulavarty AN, Carucci J, Stevenson ML. Association of Patient Risk Factors, Tumor Characteristics, and Treatment Modality With Poor Outcomes in Primary Cutaneous Squamous Cell Carcinoma: A Systematic Review and Meta-analysis. JAMA Dermatol 2023;159:160–71.

[9] Migden MR, Rischin D, Schmults CD, Guminski A, Hauschild A, Lewis KD, et al. PD-1 Blockade with Cemiplimab in Advanced Cutaneous Squamous-Cell Carcinoma. N Engl J Med 2018;379:341–51.

[10] Union for International Cancer Control. TNM Classification of malignant tumours. Eighth edition. Oxford, UK: John Wiley and Sons; 2017.

[11] AJCC Cancer Staging Manual. In: Amin MB, Edge S, Greene F, Byrd DR, Brookland RK, Washington MK, Gershenwald JE, Compton CC, Hess KR, Sullivan DC, Jessup JM, Brierley JD, Gaspar LE, Schilsky RL, Balch CM, Winchester DP, Asare EA, Madera M, Gress DM, Meyer LR, editors. Eighth Edition. Chicago, USA: Springer Nature, Springer International Publishing AG; 2017.

[12] Skin Tumours. In: Brierley JD, Giuliani M, O'Sullivan B, Rous B, Van Eycken E, editors. Union for International Cancer Control (UICC) TNM Classification of Malignant Tumours. 9th Edition. John Wiley & Sons Ltd; 2025.

[13] Gaudy-Marqueste C, Grob JJ, Garbe C, Ascierto PA, Arron S, Basset-Seguin N, et al. Operational classification of cutaneous squamous cell carcinomas based on unsupervised clustering of real cases by experts. J Eur Acad Dermatol Venereol 2025;39:612–21.

[14] Green AC, Olsen CM. Cutaneous squamous cell carcinoma: an epidemiological review. Br J Dermatol 2017;177:373–81.

[15] Keim U, Katalinic A, Holleczek B, Wakkee M, Garbe C, Leiter U. Incidence, mortality and trends of cutaneous squamous cell carcinoma in Germany, the Netherlands, and Scotland. Eur J Cancer 2023;183:60–8.

[16] Leiter U, Keim U, Eigentler T, Katalinic A, Holleczek B, Martus P, et al. Incidence, Mortality, and Trends of Nonmelanoma Skin Cancer in Germany. J Invest Dermatol 2017;137:1860–7.

[17] Nanz L, Keim U, Katalinic A, Meyer T, Garbe C, Leiter U. Epidemiology of Keratinocyte Skin Cancer with a Focus on Cutaneous Squamous Cell Carcinoma. Cancers (Basel) 2024;16.

[18] Adalsteinsson JA, Olafsdottir E, Ratner D, Waldman R, Feng H, Ungar J, et al. Invasive and in situ squamous cell carcinoma of the skin: a nationwide study in Iceland. Br J Dermatol 2021;185:537–47.

[19] Deady S, Sharp L, Comber H. Increasing skin cancer incidence in young, affluent, urban populations: a challenge for prevention. Br J Dermatol 2014;171:324–31.

[20] Venables ZC, Nijsten T, Wong KF, Autier P, Broggio J, Deas A, et al. Epidemiology of basal and cutaneous squamous cell carcinoma in the U.K. 2013-15: a cohort study. Br J Dermatol 2019;181:474–82.

[21] Robsahm TE, Helsing P, Veierod MB. Cutaneous squamous cell carcinoma in Norway 1963-2011: increasing incidence and stable mortality. Cancer Med 2015; 4:472–80.

[22] Pandeya N, Olsen CM, Whiteman DC. The incidence and multiplicity rates of keratinocyte cancers in Australia. Med J Aust 2017;207:339–43.

[23] Wang R, Chen Y, Shao X, Chen T, Zhong J, Ou Y, et al. Burden of Skin Cancer in Older Adults From 1990 to 2021 and Modelled Projection to 2050. JAMA Dermatol 2025;161:715–22.

[24] Goon PKC, Greenberg DC, Igali L, Levell NJ. Predicted cases of U.K. skin squamous cell carcinoma and basal cell carcinoma in 2020 and 2025: horizon planning for National Health Service dermatology and dermatopathology. Br J Dermatol 2017;176:1351–3.
[25] Kleinstern G, Rishi A, Achenbach SJ, Rabe KG, Kay NE, Shanafelt TD, et al. Delineation of clinical and biological factors associated with cutaneous squamous cell carcinoma among patients with chronic lymphocytic leukemia. J Am Acad Dermatol 2020;83:1581–9.
[26] Garrett GL, Blanc PD, Boscardin J, Lloyd AA, Ahmed RL, Anthony T, et al. Incidence of and Risk Factors for Skin Cancer in Organ Transplant Recipients in the United States. JAMA Dermatol 2017;153:296–303.
[27] Plasmeijer EI, Sachse MM, Gebhardt C, Geusau A, Bouwes Bavinck JN. Cutaneous squamous cell carcinoma (cSCC) and immunosurveillance - the impact of immunosuppression on frequency of cSCC. J Eur Acad Dermatol Venereol 2019; 33(8):33–7.
[28] de Jong E, Genders R, Harwood CA, Green AC, Plasmeijer EI, Proby C, et al. Cumulative incidence and risk factors for cutaneous squamous cell carcinoma metastases in organ transplant recipients: The Skin Care in Organ Transplant Patients in Europe-International Transplant Skin Cancer Collaborative metastases study, a prospective multicenter study. J Am Acad Dermatol 2024;90:1200–9.
[29] Brewer JD, Shanafelt TD, Khezri F, Sosa Seda IM, Zubair AS, Baum CL, et al. Increased incidence and recurrence rates of nonmelanoma skin cancer in patients with non-Hodgkin lymphoma: a Rochester Epidemiology Project population-based study in Minnesota. J Am Acad Dermatol 2015;72:302–9.
[30] Eggermont CJ, Hollatz A, Wakkee M, Louwman M, Dinmohamed AG, Posthuma EFM, et al. Skin cancer risk in more than 200 000 patients with haematological malignancies over 30 years: a nationwide population-based study in the Netherlands. Br J Dermatol 2025;192:1029–37.
[31] Cardoso Borges F, Ramos A, Lourenco A, Gomes da Silva M, Miranda A. network RO-S. Detailing the epidemiological and clinical characteristics of chronic lymphocytic leukaemia in Portugal-Results from a population-based cancer registry cohort study. PloS One 2021;16:e0258423.
[32] Lai M, Pampena R, Cornacchia L, Odorici G, Piccerillo A, Pellacani G, et al. Cutaneous squamous cell carcinoma in patients with chronic lymphocytic leukemia: a systematic review of the literature. Int J Dermatol 2022;61:548–57.
[33] Omland SH, Ahlstrom MG, Gerstoft J, Pedersen G, Mohey R, Pedersen C, et al. Risk of skin cancer in patients with HIV: A Danish nationwide cohort study. J Am Acad Dermatol 2018;79:689–95.
[34] Dessinioti C, Pitoulias M, Stratigos AJ. Epidemiology of advanced cutaneous squamous cell carcinoma. J Eur Acad Dermatol Venereol 2022;36:39–50.
[35] Eisemann N, Jansen L, Castro FA, Chen T, Eberle A, Nennecke A, et al. Survival with nonmelanoma skin cancer in Germany. Br J Dermatol 2016;174:778–85.
[36] Tokez S, Wakkee M, Kan W, Venables ZC, Mooyaart AL, Louwman M, et al. Cumulative incidence and disease-specific survival of metastatic cutaneous squamous cell carcinoma: A nationwide cancer registry study. J Am Acad Dermatol 2022;86:331–8.
[37] Venables ZC, Autier P, Nijsten T, Wong KF, Langan SM, Rous B, et al. Nationwide Incidence of Metastatic Cutaneous Squamous Cell Carcinoma in England. JAMA Dermatol 2019;155:298–306.
[38] Brougham ND, Dennett ER, Cameron R, Tan ST. The incidence of metastasis from cutaneous squamous cell carcinoma and the impact of its risk factors. J Surg Oncol 2012;106:811–5.
[39] Brantsch KD, Meisner C, Schonfisch B, Trilling B, Wehner-Caroli J, Rocken M, et al. Analysis of risk factors determining prognosis of cutaneous squamous-cell carcinoma: a prospective study. Lancet Oncol 2008;9:713–20.
[40] Schmults CD, Karia PS, Carter JB, Han J, Qureshi AA. Factors predictive of recurrence and death from cutaneous squamous cell carcinoma: a 10-year, single-institution cohort study. JAMA Dermatol 2013;149:541–7.
[41] Ran NA, Granger EE, Brodland DG, Canueto J, Carr DR, Carter JB, et al. Risk Factor Number and Recurrence, Metastasis, and Disease-Related Death in Cutaneous Squamous Cell Carcinoma. JAMA Dermatol 2025;161:597–604.
[42] Eigentler TK, Leiter U, Hafner HM, Garbe C, Rocken M, Breuninger H. Survival of Patients with Cutaneous Squamous Cell Carcinoma: Results of a Prospective Cohort Study. J Invest Dermatol 2017;137:2309–15.
[43] Manyam BV, Garsa AA, Chin RI, Reddy CA, Gastman B, Thorstad W, et al. A multi-institutional comparison of outcomes of immunosuppressed and immunocompetent patients treated with surgery and radiation therapy for cutaneous squamous cell carcinoma of the head and neck. Cancer 2017;123: 2054–60.
[44] Rabinovics N, Mizrachi A, Hadar T, Ad-El D, Feinmesser R, Guttman D, et al. Cancer of the head and neck region in solid organ transplant recipients. Head Neck 2014;36:181–6.
[45] Dessinioti C, Platsidaki E, Stratigos AJ. A Sensitivity Meta-Analysis of Disease-Specific Death in Localized Cutaneous Squamous Cell Carcinoma. Dermatology 2022;238:1026–35.
[46] Sahovaler A, Krishnan RJ, Yeh DH, Zhou Q, Palma D, Fung K, et al. Outcomes of Cutaneous Squamous Cell Carcinoma in the Head and Neck Region With Regional Lymph Node Metastasis: A Systematic Review and Meta-analysis. JAMA Otolaryngol Head Neck Surg 2019;145:352–60.
[47] Lam JKS, Sundaresan P, Gebski V, Veness MJ. Immunocompromised patients with metastatic cutaneous nodal squamous cell carcinoma of the head and neck: Poor outcome unrelated to the index lesion. Head Neck 2018;40:985–92.
[48] Robertson SJ, Orrin E, Lakhan MK, O'Sullivan G, Felton J, Robson A, et al. Cutaneous Squamous Cell Carcinoma in Epidermolysis Bullosa: a 28-year Retrospective Study. Acta Derm Venereol 2021;101:adv00523.
[49] Morris KL, Luke MC, Perna FM. Prevalence of Skin Cancer Examination Among Users of Indoor Tanning Beds. JAMA Dermatol 2018;154:840–2.
[50] Anderson R, Mkhize NM, Kgokolo MMC, Steel HC, Rossouw TM, Anderson L, et al. Current and Emerging Insights into the Causes, Immunopathogenesis, and Treatment of Cutaneous Squamous Cell Carcinoma. Cancers (Basel) 2025;17.
[51] Winge MCG, Kellman LN, Guo K, Tang JY, Swetter SM, Aasi SZ, et al. Advances in cutaneous squamous cell carcinoma. Nat Rev Cancer 2023;23:430–49.
[52] Harwood CA, Arron ST, Proby CM, Asgari MM, Bouwes Bavinck JN, Green AC, et al. Organ transplantation and cutaneous squamous cell carcinoma: progress, pitfalls and priorities in immunosuppression-associated keratinocyte carcinoma. Br J Dermatol 2017;177:1150–1.
[53] Jean-Pierre P, Nouri K. A retrospective analysis of drugs associated with the development of cutaneous squamous cell carcinoma reported by patients on the FDA's adverse events reporting system. Arch Dermatol Res 2024;316:250.
[54] Peng L, Wang Y, Hong Y, Ye X, Shi P, Zhang J, et al. Incidence and relative risk of cutaneous squamous cell carcinoma with single-agent BRAF inhibitor and dual BRAF/MEK inhibitors in cancer patients: a meta-analysis. Oncotarget 2017;8: 83280–91.
[55] Ikeya S, Sakabe JI, Yamada T, Naito T, Tokura Y. Voriconazole-induced photocarcinogenesis is promoted by aryl hydrocarbon receptor-dependent COX-2 upregulation. Sci Rep 2018;8:5050.
[56] de Macedo Andrade AC, Felix FA, Franca GM, Ribeiro ILA, Barboza CAG, de Castro RD, et al. Hydrochlorothiazide use is associated with the risk of cutaneous and lip squamous cell carcinoma: A systematic review and meta-analysis. Eur J Clin Pharm 2022;78:919–30.
[57] Schneider R, Reinau D, Stoffel S, Jick SS, Meier CR, Spoendlin J. Risk of skin cancer in new users of thiazides and thiazide-like diuretics: a cohort study using an active comparator group. Br J Dermatol 2021;185:343–52.
[58] Nagarajan P, Asgari MM, Green AC, Guhan SM, Arron ST, Proby CM, et al. Keratinocyte Carcinomas: Current Concepts and Future Research Priorities. Clinical cancer research official journal American Association Cancer Research 2019;25:2379–91.
[59] Viarisio D, Muller-Decker K, Accardi R, Robitaille A, Durst M, Beer K, et al. Beta HPV38 oncoproteins act with a hit-and-run mechanism in ultraviolet radiation-induced skin carcinogenesis in mice. PLoS Pathog 2018;14:e1006783.
[60] Strickley JD, Messerschmidt JL, Awad ME, Li T, Hasegawa T, Ha DT, et al. Immunity to commensal papillomaviruses protects against skin cancer. Nature 2019;575:519–22.
[61] Pirie K, Beral V, Heath AK, Green J, Reeves GK, Peto R, et al. Heterogeneous relationships of squamous and basal cell carcinomas of the skin with smoking: the UK Million Women Study and meta-analysis of prospective studies. Br J Cancer 2018;119:114–20.
[62] Dusingize JC, Olsen CM, Pandeya NP, Subramaniam P, Thompson BS, Neale RE, et al. Cigarette Smoking and the Risks of Basal Cell Carcinoma and Squamous Cell Carcinoma. J Invest Dermatol 2017;137(8):1700.
[63] Mahamat-Saleh Y, Al-Rahmoun M, Severi G, Ghiasvand R, Veierod MB, Caini S, et al. Baseline and lifetime alcohol consumption and risk of skin cancer in the European Prospective Investigation into Cancer and Nutrition cohort (EPIC). Int J Cancer 2022.
[64] Chahal HS, Lin Y, Ransohoff KJ, Hinds DA, Wu W, Dai HJ, et al. Genome-wide association study identifies novel susceptibility loci for cutaneous squamous cell carcinoma. Nat Commun 2016;7:12048.
[65] Wang W, Jorgenson E, Whittemore AS, Asgari MM. Susceptibility Loci-Associated Cutaneous Squamous Cell Carcinoma Invasiveness. J Invest Dermatol 2018;138: 557–61.
[66] Ioannidis NM, Wang W, Furlotte NA, Hinds DA, Me Research T, Bustamante CD, et al. Gene expression imputation identifies candidate genes and susceptibility loci associated with cutaneous squamous cell carcinoma. Nat Commun 2018;9: 4264.
[67] Sordillo JE, Kraft P, Wu AC, Asgari MM. Quantifying the Polygenic Contribution to Cutaneous Squamous Cell Carcinoma Risk. J Invest Dermatol 2018;138: 1507–10.
[68] Sarin KY, Lin Y, Daneshjou R, Ziyatdinov A, Thorleifsson G, Rubin A, et al. Genome-wide meta-analysis identifies eight new susceptibility loci for cutaneous squamous cell carcinoma. Nat Commun 2020;11:820.
[69] Marks R, Rennie G, Selwood TS. Malignant transformation of solar keratoses to squamous cell carcinoma. Lancet (Lond Engl) 1988;1:795–7.
[70] Werner RN, Sammain A, Erdmann R, Hartmann V, Stockfleth E, Nast A. The natural history of actinic keratosis: a systematic review. Br J Dermatol 2013;169: 502–18.
[71] South AP, Purdie KJ, Watt SA, Haldenby S, den Breems N, Dimon M, et al. NOTCH1 mutations occur early during cutaneous squamous cell carcinogenesis. J Invest Dermatol 2014;134:2630–8.
[72] Inman GJ, Wang J, Nagano A, Alexandrov LB, Purdie KJ, Taylor RG, et al. The genomic landscape of cutaneous SCC reveals drivers and a novel azathioprine associated mutational signature. Nat Commun 2018;9:3667.
[73] Chitsazzadeh V, Coarfa C, Drummond JA, Nguyen T, Joseph A, Chilukuri S, et al. Cross-species identification of genomic drivers of squamous cell carcinoma development across preneoplastic intermediates. Nat Commun 2016;7:12601.
[74] Cammareri P, Rose AM, Vincent DF, Wang J, Nagano A, Libertini S, et al. Inactivation of TGFbeta receptors in stem cells drives cutaneous squamous cell carcinoma. Nat Commun 2016;7:12493.
[75] Al-Rohil RN, Tarasen AJ, Carlson JA, Wang K, Johnson A, Yelensky R, et al. Evaluation of 122 advanced-stage cutaneous squamous cell carcinomas by comprehensive genomic profiling opens the door for new routes to targeted therapies. Cancer 2016;122:249–57.

[76] Chang D, Shain AH. The landscape of driver mutations in cutaneous squamous cell carcinoma. NPJ Genom Med 2021;6:61.
[77] Kim YS, Shin S, Jung SH, Park YM, Park GS, Lee SH, et al. Genomic Progression of Precancerous Actinic Keratosis to Squamous Cell Carcinoma. J Invest Dermatol 2022;142:528–38. e8.
[78] Thomson J, Bewicke-Copley F, Anene CA, Gulati A, Nagano A, Purdie K, et al. The Genomic Landscape of Actinic Keratosis. J Invest Dermatol 2021;141:1664–74. e7.
[79] Zheng Q, Capell BC, Parekh V, O'Day C, Atillasoy C, Bashir HM, et al. Whole-Exome and Transcriptome Analysis of UV-Exposed Epidermis and Carcinoma In Situ Reveals Early Drivers of Carcinogenesis. J Invest Dermatol 2021;141: 295–307. e13.
[80] Cho RJ, Alexandrov LB, den Breems NY, Atanasova VS, Farshchian M, Purdom E, et al. APOBEC mutation drives early-onset squamous cell carcinomas in recessive dystrophic epidermolysis bullosa. Sci Transl Med 2018:10.
[81] Lee CAA, Wu S, Chow YT, Kofman E, Williams V, Riddle M, et al. Accelerated Aging and Microsatellite Instability in Recessive Dystrophic Epidermolysis Bullosa-Associated Cutaneous Squamous Cell Carcinoma. J Invest Dermatol 2024; 144:1534–43. e2.
[82] Bailey P, Ridgway RA, Cammareri P, Treanor-Taylor M, Bailey UM, Schoenherr C, et al. Driver gene combinations dictate cutaneous squamous cell carcinoma disease continuum progression. Nat Commun 2023;14:5211.
[83] Bone M, Schreyer D, Treanor-Taylor M, Proby CM, Harwood CA, Leigh IM, et al. The landscape of long noncoding RNA during cutaneous squamous cell carcinoma progression. Br J Dermatol 2025;193:490–501.
[84] Hervas-Marin D, Higgins F, Sanmartin O, Lopez-Guerrero JA, Bano MC, Igual JC, et al. Genome wide DNA methylation profiling identifies specific epigenetic features in high-risk cutaneous squamous cell carcinoma. PloS One 2019;14: e0223341.
[85] Rodriguez-Paredes M, Bormann F, Raddatz G, Gutekunst J, Lucena-Porcel C, Kohler F, et al. Methylation profiling identifies two subclasses of squamous cell carcinoma related to distinct cells of origin. Nat Commun 2018;9:577.
[86] Ji AL, Rubin AJ, Thrane K, Jiang S, Reynolds DL, Meyers RM, et al. Multimodal Analysis of Composition and Spatial Architecture in Human Squamous Cell Carcinoma. Cell 2020;182:497–514. e22.
[87] Garcia-Diez I, Hernandez-Ruiz E, Andrades E, Gimeno J, Ferrandiz-Pulido C, Yebenes M, et al. PD-L1 Expression is Increased in Metastasizing Squamous Cell Carcinomas and Their Metastases. Am J Derm 2018;40:647–54.
[88] Schaper K, Kother B, Hesse K, Satzger I, Gutzmer R. The pattern and clinicopathological correlates of programmed death-ligand 1 expression in cutaneous squamous cell carcinoma. Br J Dermatol 2017;176:1354–6.
[89] Ferguson AL, Sharman AR, Allen RO, Ye T, Lee JH, Low TH, et al. High-Dimensional and Spatial Analysis Reveals Immune Landscape-Dependent Progression in Cutaneous Squamous Cell Carcinoma. Clinical cancer research official journal American Association Cancer Research 2022;28:4677–88.
[90] Baruch EN, Gleber-Netto FO, Nagarajan P, Rao X, Akhter S, Eichwald T, et al. Cancer-induced nerve injury promotes resistance to anti-PD-1 therapy. Nature 2025;646:462–73.
[91] Voigt AY, Emiola A, Johnson JS, Fleming ES, Nguyen H, Zhou W, et al. Skin Microbiome Variation with Cancer Progression in Human Cutaneous Squamous Cell Carcinoma. J Invest Dermatol 2022.
[92] Bromfield JI, Hugenholtz P, Frazer IH, Khosrotehrani K, Chandra J. Targeting Staphylococcus aureus dominated skin dysbiosis in actinic keratosis to prevent the onset of cutaneous squamous cell carcinoma: Outlook for future therapies? Front Oncol 2023;13:1091379.
[93] Carr RA, Craig PJ. Zalaudek I. Keratoacanthoma. In: Calonje E, Messina J, Scolyer R, editors. WHO Classification of Tumours, Skin Tumours WHO Classification of Tumours Editorial. 5th ed. Lyon (France): International Agency for Research on Cancer (IARC); 2025. p. 78–81.
[94] Rosendahl C, Cameron A, Argenziano G, Zalaudek I, Tschandl P, Kittler H. Dermoscopy of squamous cell carcinoma and keratoacanthoma. Arch Dermatol 2012;148:1386–92.
[95] Lallas A, Pyne J, Kyrgidis A, Andreani S, Argenziano G, Cavaller A, et al. The clinical and dermoscopic features of invasive cutaneous squamous cell carcinoma depend on the histopathological grade of differentiation. Br J Dermatol 2015;172: 1308–15.
[96] Zalaudek I, Giacomel J, Schmid K, Bondino S, Rosendahl C, Cavicchini S, et al. Dermatoscopy of facial actinic keratosis, intraepidermal carcinoma, and invasive squamous cell carcinoma: a progression model. J Am Acad Dermatol 2012;66: 589–97.
[97] Korecka K, Pietkiewicz P, Akay BN, Badiu I, Errichetti E, Liopyris K, et al. How do we recognize a difficult squamous cell carcinoma? A retrospective analysis of clinically and dermoscopically misdiagnosed tumours. Clin Exp Dermatol 2025; 50:2016–21.
[98] Papageorgiou C, Lallas A, Manoli SM, Longo C, Lai M, Liopyris K, et al. Evaluation of dermatoscopic criteria for early detection of squamous cell carcinoma arising on an actinic keratosis. J Am Acad Dermatol 2022;86:791–6.
[99] Papageorgiou C, Spyridis I, Manoli SM, Busila I, Nasturica IE, Lallas K, et al. Accuracy of dermoscopic criteria for the differential diagnosis between irritated seborrheic keratosis and squamous cell carcinoma. J Am Acad Dermatol 2021;85: 1143–50.
[100] Rishpon A, Kim N, Scope A, Porges L, Oliviero MC, Braun RP, et al. Reflectance confocal microscopy criteria for squamous cell carcinomas and actinic keratoses. Arch Dermatol 2009;145:766–72.
[101] Manfredini M, Longo C, Ferrari B, Piana S, Benati E, Casari A, et al. Dermoscopic and reflectance confocal microscopy features of cutaneous squamous cell carcinoma. J Eur Acad Dermatol Venereol 2017;31:1828–33.
[102] Dinnes J, Deeks JJ, Chuchu N, Saleh D, Bayliss SE, Takwoingi Y, et al. Reflectance confocal microscopy for diagnosing keratinocyte skin cancers in adults. Cochrane Database Syst Rev 2018;12:CD013191.
[103] Ruini C, Schuh S, Gust C, Kendziora B, Frommherz L, French LE, et al. Line-field confocal optical coherence tomography for the in vivo real-time diagnosis of different stages of keratinocyte skin cancer: a preliminary study. J Eur. Acad Dermatol Venereol 2021;35:2388–97.
[104] Boone MA, Marneffe A, Suppa M, Miyamoto M, Alarcon I, Hofmann-Wellenhof R, et al. High-definition optical coherence tomography algorithm for the discrimination of actinic keratosis from normal skin and from squamous cell carcinoma. J Eur Acad Dermatol Venereol 2015;29:1606–15.
[105] Themstrup L, Pellacani G, Welzel J, Holmes J, Jemec GBE, Ulrich M. vivo microvascular imaging of cutaneous actinic keratosis, Bowen's disease and squamous cell carcinoma using dynamic optical coherence tomography. J Eur Acad Dermatol Venereol 2017;31:1655–62.
[106] Ferrante di Ruffano L, Dinnes J, Deeks JJ, Chuchu N, Bayliss SE, Davenport C, et al. Optical coherence tomography for diagnosing skin cancer in adults. Cochrane Database Syst Rev 2018;(12):CD013189.
[107] Cheng JY, Li FY, Ko CJ, Colegio OR. Cutaneous Squamous Cell Carcinomas in Solid Organ Transplant Recipients Compared With Immunocompetent Patients. JAMA Dermatol 2018;154:60–6.
[108] Kallini JR, Hamed N, Khachemoune A. Squamous cell carcinoma of the skin: epidemiology, classification, management, and novel trends. Int J Dermatol 2015; 54:130–40.
[109] Que SKT, Zwald FO, Schmults CD. Cutaneous squamous cell carcinoma: Incidence, risk factors, diagnosis, and staging. J Am Acad Dermatol 2018;78: 237–47.
[110] Beer TW, Shepherd P, Theaker JM. Ber EP4 and epithelial membrane antigen aid distinction of basal cell, squamous cell and basosquamous carcinomas of the skin. Histopathology 2000;37:218–23.
[111] Murphy GF, Beer TW, Cerio R, Kao GF, Nagore E, Pulitzer MP. Squamous cell carcinoma. In: Elder DM D, Scolyer RA, Willemze R, editors. WHO Classification of Skin Tumours. 4th ed. France: International Agency ofr Research on Cancer (IARC); 2018. p. 35–44.
[112] Breuninger H, Schaumburg-Lever G, Holzschuh J, Horny HP. Desmoplastic squamous cell carcinoma of skin and vermilion surface: a highly malignant subtype of skin cancer. Cancer 1997;79:915–9.
[113] Califano JA, Lydiatt WM, Nehal K, O'Sullivan B, Schmults C, Seethala RR, et al. Cutaneous Carcinoma of the Head and Neck. In: Amin MB, Edge S, Byrd DR, Brookland RK, Washington MK, Gershenwald JE, et al., editors. AJCC Cancer Staging Manual. Eighth Edition. Springer; 2017. p. 171–81.
[114] Carter JB, Johnson MM, Chua TL, Karia PS, Schmults CD. Outcomes of primary cutaneous squamous cell carcinoma with perineural invasion: an 11-year cohort study. JAMA Dermatol 2013;149:35–41.
[115] Haug K, Breuninger H, Metzler G, Eigentler T, Eichner M, Hafner HM, et al. Prognostic Impact of Perineural Invasion in Cutaneous Squamous Cell Carcinoma: Results of a Prospective Study of 1,399 Tumors. J Invest Dermatol 2020;140: 1968–75.
[116] Kofler K, Breuninger H, Eigentler T, Kofler L, Schaefer V, Blumenstock G, et al. Local Tumor Infiltration and Locoregional Recurrence in Desmoplastic Cutaneous Squamous Cell Carcinoma. Dermatol Surg 2022;48:283–9.
[117] Dessinioti C, Stratigos AJ. Recent Advances in the Diagnosis and Management of High-Risk Cutaneous Squamous Cell Carcinoma. Cancers (Basel) 2022;14.
[118] Dessinioti C, Stratigos AJ. Overview of guideline recommendations for the management of high-risk and advanced cutaneous squamous cell carcinoma. J Eur Acad Dermatol Venereol 2022;36(1):11–8.
[119] Cherpelis BS, Marcusen C, Lang PG. Prognostic factors for metastasis in squamous cell carcinoma of the skin. Dermatol Surg 2002;28:268–73.
[120] Petter G, Haustein UF. Squamous cell carcinoma of the skin–histopathological features and their significance for the clinical outcome. J Eur Acad Dermatol Venereol 1998;11:37–44.
[121] Saito Y, Fujikawa H, Takatsuka S, Abe R, Takenouchi T. Risk factors for lymph node metastasis in cutaneous squamous cell carcinoma: a long-term retrospective study of Japanese patients. Int J Clin Oncol 2021;26:606–12.
[122] Tokez S, Venables ZC, Hollestein LM, Qi H, Bramer EM, Rentroia-Pacheco B, et al. Risk factors for metastatic cutaneous squamous cell carcinoma: Refinement and replication based on 2 nationwide nested case-control studies. J Am Acad Dermatol 2022.
[123] Stefanovic N, Fitzmaurice CJ, Ormond P, Irvine AD, Barry RB. Risk factors for distant metastasis in cutaneous squamous cell carcinoma. Br J Dermatol 2022.
[124] Kus KJB, Murad F, Smile TD, Chang M, Ashrafzadeh S, Zhou G, et al. Higher metastasis and death rates in cutaneous squamous cell carcinomas with lymphovascular invasion. J Am Acad Dermatol 2022;86:766–73.
[125] O'Connor DM, Murad F, Danesh MJ, Butler W, Smile TD, Ilori EO, et al. Immune status does not independently influence cutaneous squamous cell carcinoma metastasis and death when stratified by tumor stage: A dual center retrospective cohort analysis of primary N0 disease. J Am Acad Dermatol 2022.
[126] Massey PR, Wang DM, Murad F, Mulvaney P, Moore K, Okhovat JP, et al. Extensive Perineural Invasion vs Nerve Caliber to Assess Cutaneous Squamous Cell Carcinoma Prognosis. JAMA Dermatol 2023;159:1332–8.
[127] Hirotsu KE, Aasi SZ, Samson KK, Zheng C, Nazaroff JR, Voller LM, et al. Lymphovascular invasion is an independent predictor of metastasis and disease-

specific death in cutaneous squamous cell carcinoma: A multicenter retrospective study. J Am Acad Dermatol 2025;93:368–77.
[128] Marrazzo G, Zitelli JA, Brodland D. Clinical outcomes in high-risk squamous cell carcinoma patients treated with Mohs micrographic surgery alone. J Am Acad Dermatol 2019;80:633–8.
[129] Karia PS, Morgan FC, Ruiz ES, Schmults CD. Clinical and Incidental Perineural Invasion of Cutaneous Squamous Cell Carcinoma: A Systematic Review and Pooled Analysis of Outcomes Data. JAMA Dermatol 2017;153(8):781.
[130] Russell E, Udkoff J, Knackstedt T. Squamous Cell Carcinoma With Bone Invasion: A Systematic Review and Pooled Survival Analysis. Dermatol Surg 2022;48: 1025–8.
[131] Klein JC, Shahwan KT, Petric UB, Mallela T, Voller L, Ruiz E, et al. Impact of immunosuppression on cutaneous squamous cell carcinoma outcomes. J Am Acad Dermatol 2025.
[132] Rosenthal A, Conde G, Dodson J, Juhasz M, Gharavi N. Immunosuppression as an Independent Risk Factor for Poor Outcomes in Cutaneous Squamous Cell Carcinoma: A Prospective Study. Dermatol Surg 2025;51:852–8.
[133] Cruts EC, Moermans MMG, Abdul Hamid M, Nelemans PJ, Mosterd K. Perineural Invasion for Risk Stratification in Cutaneous Squamous Cell Carcinoma: A Scoping Review. Dermatology 2025;241:203–9.
[134] Eigentler TK, Dietz K, Leiter U, Hafner HM, Breuninger H. What causes the death of patients with cutaneous squamous cell carcinoma? A prospective analysis in 1400 patients. Eur J Cancer 2022;172:182–90.
[135] Stevens JS, Murad F, Smile TD, O'Connor DM, Ilori E, Koyfman S, et al. Validation of the 2022 National Comprehensive Cancer Network Risk Stratification for Cutaneous Squamous Cell Carcinoma. JAMA Dermatol 2023;159:728–35.
[136] Zakhem GA, Qiblawi S, Shelton E, Xu YG. Prevalence of poor outcomes in cutaneous squamous cell carcinoma by AJCC and BWH tumor stages: A systematic review and meta-analysis. J Am Acad Dermatol 2025;92:1064–71.
[137] Jambusaria-Pahlajani A, Jeanselme V, Wang DM, Ran NA, Granger EE, Canueto J, et al. riSCC: A personalized risk model for the development of poor outcomes in cutaneous squamous cell carcinoma. J Am Acad Dermatol 2025;93:73–81.
[138] Rentroia-Pacheco B, Tokez S, Bramer EM, Venables ZC, van de Werken HJG, Bellomo D, et al. Personalised decision making to predict absolute metastatic risk in cutaneous squamous cell carcinoma: development and validation of a clinico-pathological model. EClinicalMedicine 2023;63:102150.
[139] Knuutila JS, Riihila P, Karlsson A, Tukiainen M, Talve L, Nissinen L, et al. Identification of metastatic primary cutaneous squamous cell carcinoma utilizing artificial intelligence analysis of whole slide images. Sci Rep 2022;12:9876.
[140] Coudray N, Juarez MC, Criscito MC, Quiros AC, Wilken R, Jackson Cullison SR, et al. Self supervised artificial intelligence predicts poor outcome from primary cutaneous squamous cell carcinoma at diagnosis. NPJ Digit Med 2025;8:105.
[141] Wysong A, Newman JG, Covington KR, Kurley SJ, Ibrahim SF, Farberg AS, et al. Validation of a 40-gene expression profile test to predict metastatic risk in localized high-risk cutaneous squamous cell carcinoma. J Am Acad Dermatol 2021;84:361–9.
[142] Ibrahim SF, Kasprzak JM, Hall MA, Fitzgerald AL, Siegel JJ, Kurley SJ, et al. Enhanced metastatic risk assessment in cutaneous squamous cell carcinoma with the 40-gene expression profile test. Future Oncol (Lond Engl) 2021.
[143] Wysong A, Somani AK, Ibrahim SF, Canueto J, Fitzgerald AL, Siegel JJ, et al. Integrating the 40-Gene Expression Profile (40-GEP) Test Improves Metastatic Risk-Stratification Within Clinically Relevant Subgroups of High-Risk Cutaneous Squamous Cell Carcinoma (cSCC) Patients. Dermatol Ther (Heide) 2024;14: 593–612.
[144] Arron ST, Canueto J, Siegel J, Fitzgerald A, Prasai A, Koyfman SA, et al. Association of a 40-Gene Expression Profile With Risk of Metastatic Disease Progression of Cutaneous Squamous Cell Carcinoma and Specification of Benefit of Adjuvant Radiation Therapy. Int J Radiat Oncol Biol Phys 2024;120:760–71.
[145] Ruiz ES, Brito K, Karn EE, Vidimos AT, Campbell SR, Wang DM, et al. Predicting adjuvant radiation therapy benefit in cutaneous squamous cell carcinoma with the 40-gene expression profile. Future Oncol (Lond Engl) 2024;20:2737–46.
[146] Moody BR, Farberg AS, Somani AK, Taylor WA. Inconsistent Associations Between Risk Factor Profiles and Adjuvant Radiation Therapy (ART) Treatment in Patients with Cutaneous Squamous Cell Carcinoma and Utility of the 40-Gene Expression Profile to Refine ART Guidance. Dermatol Ther (Heide) 2024;14: 861–73.
[147] Somani AK, Ibrahim SF, Tassavor M, Yoo J, Farberg AS. Use of the 40-gene Expression Profile (40-GEP) Test in Medicare-eligible Patients Diagnosed with Cutaneous Squamous Cell Carcinoma (cSCC) to Guide Adjuvant Radiation Therapy (ART) Decisions Leads to a Significant Reduction in Healthcare Costs. J Clin aesthetic Dermatol 2024;17:41–4.
[148] Masarwy R, Shilo S, Carmel Neiderman NN, Kampel L, Horowitz G, Muhanna N, et al. The Prognostic Value and Clinical Utility of the 40-Gene Expression Profile (40-GEP) Test in Cutaneous Squamous Cell Carcinoma: Systematic Review and Meta-Analysis. Cancers (Basel) 2023;15.
[149] Arron ST, Wysong A, Hall MA, Bailey CN, Covington KR, Kurley SJ, et al. Gene expression profiling for metastatic risk in head and neck cutaneous squamous cell carcinoma. Laryngoscope Invest Otolaryngol 2022;7:135–44.
[150] Sax JL, McFarland CD, Carroll BT. Limitations of the commercially available gene expression test in predicting cutaneous squamous cell carcinoma metastasis and clinical outcomes. J Am Acad Dermatol 2025;93:150–4.
[151] Maubec E. Update of the Management of Cutaneous Squamous-cell Carcinoma. Acta Derm Venereol 2020;100:adv00143.
[152] Fox M, Brown M, Golda N, Goldberg D, Miller C, Pugliano-Mauro M, et al. Nodal staging of high-risk cutaneous squamous cell carcinoma. J Am Acad Dermatol 2019;81:548–57.
[153] Gurney B, Newlands C. Management of regional metastatic disease in head and neck cutaneous malignancy. 1. Cutaneous squamous cell carcinoma. Br J Oral Maxillofac Surg 2014;52:294–300.
[154] de Bondt RB, Nelemans PJ, Hofman PA, Casselman JW, Kremer B, van Engelshoven JM, et al. Detection of lymph node metastases in head and neck cancer: a meta-analysis comparing US, USgFNAC, CT and MR imaging. Eur J Radio 2007;64:266–72.
[155] Land R, Herod J, Moskovic E, King M, Sohaib SA, Trott P, et al. Routine computerized tomography scanning, groin ultrasound with or without fine needle aspiration cytology in the surgical management of primary squamous cell carcinoma of the vulva. Int J Gynecol Cancer 2006;16:312–7.
[156] Maher JM, Schmults CD, Murad F, Karia PS, Benson CB, Ruiz ES. Detection of subclinical disease with baseline and surveillance imaging in high-risk cutaneous squamous cell carcinomas. J Am Acad Dermatol 2020;82:920–6.
[157] Tokez S, Koekelkoren FHJ, Baatenburg de Jong RJ, Grunhagen DJ, Mooyaart AL, Nijsten T, et al. Assessment of the Diagnostic Accuracy of Baseline Clinical Examination and Ultrasonographic Imaging for the Detection of Lymph Node Metastasis in Patients With High-Risk Cutaneous Squamous Cell Carcinoma of the Head and Neck. JAMA Dermatol 2021.
[158] Humphreys TR, Shah K, Wysong A, Lexa F, MacFarlane D. The role of imaging in the management of patients with nonmelanoma skin cancer: When is imaging necessary? J Am Acad Dermatol 2017;76:591–607.
[159] Williams LS, Mancuso AA, Mendenhall WM. Perineural spread of cutaneous squamous and basal cell carcinoma: CT and MR detection and its impact on patient management and prognosis. Int J Radiat Oncol Biol Phys 2001;49:1061–9.
[160] MacFarlane D, Shah K, Wysong A, Wortsman X, Humphreys TR. The role of imaging in the management of patients with nonmelanoma skin cancer: Diagnostic modalities and applications. J Am Acad Dermatol 2017;76:579–88.
[161] Ruiz ES, Karia PS, Morgan FC, Schmults CD. The positive impact of radiologic imaging on high-stage cutaneous squamous cell carcinoma management. J Am Acad Dermatol 2017;76:217–25.
[162] Wei AH, Cassard L, Fan C, Seck S, Vazquez MR, Bena J, et al. Radiologic imaging aids management of high-risk cutaneous squamous cell carcinoma: A retrospective cohort study. J Am Acad Dermatol 2025;93:360–7.
[163] Warren TA, Panizza B, Porceddu SV, Gandhi M, Patel P, Wood M, et al. Outcomes after surgery and postoperative radiotherapy for perineural spread of head and neck cutaneous squamous cell carcinoma. Head Neck 2016;38:824–31.
[164] Gandhi MR, Panizza B, Kennedy D. Detecting and defining the anatomic extent of large nerve perineural spread of malignancy: comparing "targeted" MRI with the histologic findings following surgery. Head Neck 2011;33:469–75.
[165] Panizza B, Solares CA, Redmond M, Parmar P, O'Rourke P. Surgical resection for clinical perineural invasion from cutaneous squamous cell carcinoma of the head and neck. Head Neck 2012;34:1622–7.
[166] Gibson FT, Murad F, Granger E, Schmults CD, Ruiz ES. Perioperative imaging for high-stage cutaneous squamous cell carcinoma helps guide management in nearly a third of cases: A single-institution retrospective cohort. J Am Acad Dermatol 2023;88:1209–11.
[167] Navarrete-Dechent C, Veness MJ, Droppelmann N, Uribe P. High-risk cutaneous squamous cell carcinoma and the emerging role of sentinel lymph node biopsy: A literature review. J Am Acad Dermatol 2015;73:127–37.
[168] Tejera-Vaquerizo A, Garcia-Doval I, Llombart B, Canueto J, Martorell-Calatayud A, Descalzo-Gallego MA, et al. Systematic review of the prevalence of nodal metastases and the prognostic utility of sentinel lymph node biopsy in cutaneous squamous cell carcinoma. J Dermatol 2018;45:781–90.
[169] Schmitt AR, Brewer JD, Bordeaux JS, Baum CL. Staging for cutaneous squamous cell carcinoma as a predictor of sentinel lymph node biopsy results: meta-analysis of American Joint Committee on Cancer criteria and a proposed alternative system. JAMA Dermatol 2014;150:19–24.
[170] Borgognoni L, Susini P, Gerlini G, Brandani P, Giannotti V, Sestini S. Sentinel Lymph Node Biopsy: Is There a Role in Non-Melanoma Skin Cancer? A Systematic Review. Cancers (Basel) 2024;16.
[171] Tejera-Vaquerizo A, Gomez-Tomas A, Jaka A, Toll A, Del Rio M, Ferrandiz-Pulido C, et al. Sentinel lymph node biopsy versus observation in high-risk cutaneous squamous cell carcinoma in immunosuppressed and immunocompetent patients: An inverse probability of treatment weighting study. J Eur Acad Dermatol Venereol 2024;38:1588–98.
[172] Zhang W, Fang Q, Zhang X, Dai L, Luo R, Yuan J. Sentinel lymph node biopsy versus observation in high risk cutaneous squamous cell carcinoma of head and neck: a propensity score matching analysis. Arch Dermatol Res 2024;316:120.
[173] Kesmodel SB, Lopez-Aguiar A, Grossman J, Zhao W, Koru-Sengul T, Tang J, et al. Sentinel Lymph Node Biopsy for Cutaneous Squamous Cell Carcinoma. J Am Coll Surg 2025.
[174] Huis In 't Veld, Boere T EA, Zuur CL, Wouters MW, van Akkooi ACJ, Haanen J, et al. Oncological Outcome After Lymph Node Dissection for Cutaneous Squamous Cell Carcinoma. Ann Surg Oncol 2023;30:5017–26.
[175] Quinn PL, Oliver JB, Mahmoud OM, Chokshi RJ. Cost-Effectiveness of Sentinel Lymph Node Biopsy for Head and Neck Cutaneous Squamous Cell Carcinoma. J Surg Res 2019;241:15–23.
[176] Lhote R, Lambert J, Lejeune J, Gottlieb J, Badaoui A, Battistella M, et al. Sentinel Lymph Node Biopsy in Cutaneous Squamous Cell Carcinoma Series of 37 Cases and Systematic Review of the Literature. Acta Derm Venereol 2018;98:671–6.
[177] Ross AS, Schmults CD. Sentinel lymph node biopsy in cutaneous squamous cell carcinoma: a systematic review of the English literature. Dermatol Surg 2006;32: 1309–21.

[178] Costantino A, Canali L, Festa BM, Spriano G, Mercante G, De Virgilio A. Sentinel lymph node biopsy in high-risk cutaneous squamous cell carcinoma of the head and neck: Systematic review and meta-analysis. Head Neck 2022.
[179] Dessinioti C, Liopyris K, Stratigos AJ. Diagnosis of invasive cutaneous squamous cell carcinoma, imaging and staging. Ital J Dermatol Venerol 2024;159:118–27.
[180] Jambusaria-Pahlajani A, Kanetsky PA, Karia PS, Hwang WT, Gelfand JM, Whalen FM, et al. Evaluation of AJCC tumor staging for cutaneous squamous cell carcinoma and a proposed alternative tumor staging system. JAMA Dermatol 2013;149:402–10.
[181] Forest VI, Clark JJ, Veness MJ, Milross C. N1S3: a revised staging system for head and neck cutaneous squamous cell carcinoma with lymph node metastases: results of 2 Australian. Cancer Cent Cancer 2010;116:1298–304.
[182] Oddone N, Morgan GJ, Palme CE, Perera L, Shannon J, Wong E, et al. Metastatic cutaneous squamous cell carcinoma of the head and neck: the Immunosuppression, Treatment, Extranodal spread, and Margin status (ITEM) prognostic score to predict outcome and the need to improve survival. Cancer 2009;115:1883–91.
[183] Smile TD, Ruiz ES, Kus KJB, Murad F, Wei W, Xiong DD, et al. Implications of Satellitosis or In-transit Metastasis in Cutaneous Squamous Cell Carcinoma: A Prognostic Omission in Cancer Staging Systems. JAMA Dermatol 2022;158(4): 390.
[184] Pahalyants V, Jairath NK, Maas DE, Cheraghlou S, Mandal S, Friedman S, et al. Satellitosis or in-transit metastasis in cutaneous squamous cell carcinoma: Risk factors and the prognostic significance. J Am Acad Dermatol 2025.
[185] Ruiz ES, Karia PS, Besaw R, Schmults CD. Performance of the American Joint Committee on Cancer Staging Manual, 8th Edition vs the Brigham and Women's Hospital Tumor Classification System for Cutaneous Squamous Cell Carcinoma. JAMA Dermatol 2019;155:819–25.
[186] Venables ZC, Tokez S, Hollestein LM, Mooyaart AL, van den Bos RR, Rous B, et al. Validation of four cutaneous squamous cell carcinoma staging systems using nationwide data. Br J Dermatol 2022;186:835–42.
[187] Roscher I, Falk RS, Vos L, Clausen OPF, Helsing P, Gjersvik P, et al. Validating 4 Staging Systems for Cutaneous Squamous Cell Carcinoma Using Population-Based Data: A Nested Case-Control Study. JAMA Dermatol 2018;154:428–34.
[188] Girardi FM, Wagner VP, Machado CDC, Wysong A, Ran NA, Granger EE, et al. Validation of Current Staging Systems in HNCSCC: A Multinational Cohort Study. Head Neck 2025;47:3385–93.
[189] Voller LM, Hirotsu KE, Aasi SZ, Nikahd M, Ruiz E, Ran N, et al. Performance of staging systems for non-head and neck cutaneous squamous cell carcinoma. Am J Clin Dermatol 2026;27:181–8.
[190] O'Sullivan DE, Brenner DR, Villeneuve PJ, Walter SD, Demers PA, Friedenreich CM, et al. The current burden of non-melanoma skin cancer attributable to ultraviolet radiation and related risk behaviours in Canada. Cancer Causes Control 2021;32:279–90.
[191] Garbe C, Forsea AM, Amaral T, Arenberger P, Autier P, Berwick M, et al. Skin cancers are the most frequent cancers in fair-skinned populations, but we can prevent them. Eur J Cancer 2024;204:114074.
[192] Jackson KM, Aiken LS. Evaluation of a multicomponent appearance-based sun-protective intervention for young women: uncovering the mechanisms of program efficacy. Health Psychol 2006;25:34–46.
[193] Sandhu PK, Elder R, Patel M, Saraiya M, Holman DM, Perna F, et al. Community-wide Interventions to Prevent Skin Cancer: Two Community Guide Systematic Reviews. Am J Prev Med 2016;51:531–9.
[194] Henrikson NB, Morrison CC, Blasi PR, Nguyen M, Shibuya KC, Patnode CD. Behavioral Counseling for Skin Cancer Prevention: Evidence Report and Systematic Review for the US Preventive Services Task Force. JAMA 2018;319: 1143–57.
[195] Glanz K, Steffen AD, Schoenfeld E, Tappe KA. Randomized trial of tailored skin cancer prevention for children: the Project SCAPE family study. J Health Commun 2013;18:1368–83.
[196] Youl PH, Soyer HP, Baade PD, Marshall AL, Finch L, Janda M. Can skin cancer prevention and early detection be improved via mobile phone text messaging? A randomised, attention control trial. Prev Med 2015;71:50–6.
[197] Green A, Williams G, Neale R, Hart V, Leslie D, Parsons P, et al. Daily sunscreen application and betacarotene supplementation in prevention of basal-cell and squamous-cell carcinomas of the skin: a randomised controlled trial. Lancet (Lond Engl) 1999;354:723–9.
[198] van der Pols JC, Williams GM, Pandeya N, Logan V, Green AC. Prolonged prevention of squamous cell carcinoma of the skin by regular sunscreen use. Cancer Epidemiol Biomark Prev 2006;15:2546–8.
[199] Thompson SC, Jolley D, Marks R. Reduction of solar keratoses by regular sunscreen use. N Engl J Med 1993;329:1147–51.
[200] Ulrich C, Jurgensen JS, Degen A, Hackethal M, Ulrich M, Patel MJ, et al. Prevention of non-melanoma skin cancer in organ transplant patients by regular use of a sunscreen: a 24 months, prospective, case-control study. Br J Dermatol 2009;161(3):78–84.
[201] Silva ESD, Tavares R, Paulitsch FDS, Zhang L. Use of sunscreen and risk of melanoma and non-melanoma skin cancer: a systematic review and meta-analysis. Eur J Dermatol 2018;28:186–201.
[202] Rueegg CS, Stenehjem JS, Egger M, Ghiasvand R, Cho E, Lund E, et al. Challenges in assessing the sunscreen-melanoma association. Int J Cancer 2019;144: 2651–68.
[203] Diepgen TL. New developments in occupational dermatology. J der Dtsch Dermatol Ges = J Ger Soc Dermatol JDDG 2016;14:875–89.
[204] International Commission on Non-Ionizing Radiation P. ICNIRP statement–Protection of workers against ultraviolet radiation. Health Phys 2010;99:66–87.
[205] Kim C, Cheng J, Colegio OR. Cutaneous squamous cell carcinomas in solid organ transplant recipients: emerging strategies for surveillance, staging, and treatment. Semin Oncol 2016;43:390–4.
[206] Harwood CA, Mesher D, McGregor JM, Mitchell L, Leedham-Green M, Raftery M, et al. A surveillance model for skin cancer in organ transplant recipients: a 22-year prospective study in an ethnically diverse population. Am J Transpl J Am Soc Transpl Am Soc Transpl Surg 2013;13:119–29.
[207] Saraiya M, Glanz K, Briss PA, Nichols P, White C, Das D, et al. Interventions to prevent skin cancer by reducing exposure to ultraviolet radiation: a systematic review. Am J Prev Med 2004;27:422–66.
[208] Crane LA, Deas A, Mokrohisky ST, Ehrsam G, Jones RH, Dellavalle R, et al. A randomized intervention study of sun protection promotion in well-child care. Prev Med 2006;42:162–70.
[209] Shaheen Glasser A, Glenn M, Bastani BA. R. The sun sense study: an intervention to improve sun protection in children. Am J Health Behav 2010;34:500–10.
[210] Norman GJ, Adams MA, Calfas KJ, Covin J, Sallis JF, Rossi JS, et al. A randomized trial of a multicomponent intervention for adolescent sun protection behaviors. Arch Pedia Adolesc Med 2007;161:146–52.
[211] Nemer KM, Council ML. Topical and Systemic Modalities for Chemoprevention of Nonmelanoma Skin Cancer. Dermatol Clin 2019;37:287–95.
[212] Damian DL, Patterson CR, Stapelberg M, Park J, Barnetson RS, Halliday GM. UV radiation-induced immunosuppression is greater in men and prevented by topical nicotinamide. J Invest Dermatol 2008;128:447–54.
[213] Mainville L, Smilga AS, Fortin PR. Effect of Nicotinamide in Skin Cancer and Actinic Keratoses Chemoprophylaxis, and Adverse Effects Related to Nicotinamide: A Systematic Review and Meta-Analysis. J Cutan Med Surg 2022; 26:297–308.
[214] Chen AC, Martin AJ, Choy B, Fernandez-Penas P, Dalziell RA, McKenzie CA, et al. A Phase 3 Randomized Trial of Nicotinamide for Skin-Cancer Chemoprevention. N Engl J Med 2015;373:1618–26.
[215] Breglio KF, Knox KM, Hwang J, Weiss R, Maas K, Zhang S, et al. Nicotinamide for Skin Cancer Chemoprevention. JAMA Dermatol 2025.
[216] Kadakia KC, Barton DL, Loprinzi CL, Sloan JA, Otley CC, Diekmann BB, et al. Randomized controlled trial of acitretin versus placebo in patients at high-risk for basal cell or squamous cell carcinoma of the skin (North Central Cancer Treatment Group Study 969251). Cancer 2012;118:2128–37.
[217] Nijsten TE, Stern RS. Oral retinoid use reduces cutaneous squamous cell carcinoma risk in patients with psoriasis treated with psoralen-UVA: a nested cohort study. J Am Acad Dermatol 2003;49:644–50.
[218] Anforth R, Blumetti TC, Clements A, Kefford R, Long GV, Fernandez-Penas P. Systemic retinoids for the chemoprevention of cutaneous squamous cell carcinoma and verrucal keratosis in a cohort of patients on BRAF inhibitors. Br J Dermatol 2013;169:1310–3.
[219] Harwood CA, Leedham-Green M, Leigh IM, Proby CM. Low-dose retinoids in the prevention of cutaneous squamous cell carcinomas in organ transplant recipients: a 16-year retrospective study. Arch Dermatol 2005;141:456–64.
[220] Chen K, Craig JC, Shumack S. Oral retinoids for the prevention of skin cancers in solid organ transplant recipients: a systematic review of randomized controlled trials. Br J Dermatol 2005;152:518–23.
[221] Muranushi C, Olsen CM, Pandeya N, Green AC. Aspirin and nonsteroidal anti-inflammatory drugs can prevent cutaneous squamous cell carcinoma: a systematic review and meta-analysis. J Invest Dermatol 2015;135:975–83.
[222] Reinau D, Surber C, Jick SS, Meier CR. Nonsteroidal anti-inflammatory drugs and the risk of nonmelanoma skin cancer. Int J Cancer 2015;137:144–53.
[223] Pandeya N, Olsen CM, Thompson BS, Dusingize JC, Neale RE, Green AC, et al. Aspirin and nonsteroidal anti-inflammatory drug use and keratinocyte cancers: a large population-based cohort study of skin cancer in Australia. Br J Dermatol 2019;181:749–60.
[224] Tang JY, Fu T, Leblanc E, Manson JE, Feldman D, Linos E, et al. Calcium plus vitamin D supplementation and the risk of nonmelanoma and melanoma skin cancer: post hoc analyses of the women's health initiative randomized controlled trial. J Clin Oncol 2011;29:3078–84.
[225] Passarelli MN, Karagas MR, Mott LA, Rees JR, Barry EL, Baron JA. Risk of keratinocyte carcinomas with vitamin D and calcium supplementation: a secondary analysis of a randomized clinical trial. Am J Clin Nutr 2020;112: 1532–9.
[226] Weinstock MA, Thwin SS, Siegel JA, Marcolivio K, Means AD, Leader NF, et al. Chemoprevention of Basal and Squamous Cell Carcinoma With a Single Course of Fluorouracil, 5%, Cream: A Randomized Clinical Trial. JAMA Dermatol 2018;154: 167–74.
[227] Rosenberg AR, Tabacchi M, Ngo KH, Wallendorf M, Rosman IS, Cornelius LA, et al. Skin cancer precursor immunotherapy for squamous cell carcinoma prevention. JCI Insight 2019;4.
[228] Weinstock MA, Bingham SF, Digiovanna JJ, Rizzo AE, Marcolivio K, Hall R, et al. Tretinoin and the prevention of keratinocyte carcinoma (Basal and squamous cell carcinoma of the skin): a veterans affairs randomized chemoprevention trial. J Invest Dermatol 2012;132:1583–90.
[229] Chung EYM, Palmer SC, Strippoli GFM. Interventions to Prevent Nonmelanoma Skin Cancers in Recipients of a Solid Organ Transplant: Systematic Review of Randomized Controlled Trials. Transplantation 2019;103:1206–15.
[230] James LJ, Saglimbene V, Wong G, Tong A, Luu LDW, Craig J, et al. Behavioural and pharmaceutical interventions for the prevention of skin cancers in solid organ transplant recipients: a systematic review of randomised controlled trials. BMJ Open 2020;10:e029265.
[231] Massey PR, Schmults CD, Li SJ, Arron ST, Asgari MM, Bouwes Bavinck JN, et al. Consensus-Based Recommendations on the Prevention of Squamous Cell

Carcinoma in Solid Organ Transplant Recipients: A Delphi Consensus Statement. JAMA Dermatol 2021;157:1219–26.
[232] Reichrath J. Dermatologic management, sun avoidance and vitamin D status in organ transplant recipients (OTR). J Photochem Photobio B 2010;101:150–9.
[233] Transplantation EEGoR. European best practice guidelines for renal transplantation. Section IV: Long-term management of the transplant recipient. IV.3.1 Long-term immunosuppression. Late steroid or cyclosporine withdrawal. Nephrol Dial Transpl 2002;17(4):19–20.
[234] Ismail F, Mitchell L, Casabonne D, Gulati A, Newton R, Proby CM, et al. Specialist dermatology clinics for organ transplant recipients significantly improve compliance with photoprotection and levels of skin cancer awareness. Br J Dermatol 2006;155:916–25.
[235] Papier K, Gordon LG, Khosrotehrani K, Isbel N, Campbell S, Griffin A, et al. Increase in preventive behaviour by organ transplant recipients after sun protection information in a skin cancer surveillance clinic. Br J Dermatol 2018; 179:1195–6.
[236] Bottomley MJ, Massey PR, Thuraisingham R, Doyle A, Rao S, Bibee KP, et al. Interventions After First Post-Transplant Cutaneous Squamous Cell Carcinoma: A Proposed Decision Framework. Transpl Int 2022;35:10880.
[237] Bavinck JN, Tieben LM, Van der Woude FJ, Tegzess AM, Hermans J, ter Schegget J, et al. Prevention of skin cancer and reduction of keratotic skin lesions during acitretin therapy in renal transplant recipients: a double-blind, placebo-controlled study. J Clin Oncol 1995;13:1933–8.
[238] George R, Weightman W, Russ GR, Bannister KM, Mathew TH. Acitretin for chemoprevention of non-melanoma skin cancers in renal transplant recipients. Australas J Dermatol 2002;43:269–73.
[239] de Sevaux RG, Smit JV, de Jong EM, van de Kerkhof PC, Hoitsma AJ. Acitretin treatment of premalignant and malignant skin disorders in renal transplant recipients: clinical effects of a randomized trial comparing two doses of acitretin. J Am Acad Dermatol 2003;49:407–12.
[240] Badri O, Schmults CD, Karia PS, Ruiz ES. Efficacy and Cost Analysis for Acitretin for Basal and Squamous Cell Carcinoma Prophylaxis in Renal Transplant Recipients. Dermatol Surg 2021;47:125–6.
[241] Bhullar S, Christensen SR. Effectiveness of acitretin for skin cancer prevention in immunosuppressed and nonimmunosuppressed patients: A retrospective cohort study. J Am Acad Dermatol 2024;90:821–2.
[242] Martinez JC, Otley CC, Euvrard S, Arpey CJ, Stasko T, International Transplant-Skin Cancer C. Complications of systemic retinoid therapy in organ transplant recipients with squamous cell carcinoma. Dermatol Surg 2004;30:662–6.
[243] Otley CC, Stasko T, Tope WD, Lebwohl M. Chemoprevention of nonmelanoma skin cancer with systemic retinoids: practical dosing and management of adverse effects. Dermatol Surg 2006;32:562–8.
[244] Hoegler KM, Khachemoune A. Is the first-line systemic chemoprevention of nonmelanoma skin cancer nicotinamide or acitretin? Int J Dermatol 2021;60: 749–50.
[245] Chen AC, Martin AJ, Dalziell RA, McKenzie CA, Lowe PM, Eris JM, et al. A phase II randomized controlled trial of nicotinamide for skin cancer chemoprevention in renal transplant recipients. Br J Dermatol 2016;175(5):1073.
[246] Drago F, Ciccarese G, Cogorno L, Calvi C, Marsano LA, Parodi A. Prevention of non-melanoma skin cancers with nicotinamide in transplant recipients: a case-control study. Eur J Dermatol 2017;27:382–5.
[247] Schmults CD, Jambusaria-Pahlajani A, Ruiz E. Nicotinamide for Skin-Cancer Chemoprevention in Transplantation. N Engl J Med 2023;388:2493.
[248] Allen NC, Martin AJ, Snaidr VA, Eggins R, Chong AH, Fernandez-Penas P, et al. Nicotinamide for Skin-Cancer Chemoprevention in Transplant Recipients. N Engl J Med 2023;388:804–12.
[249] Hwang JC, Savage KT, Pugliano-Mauro M. Nicotinamide for secondary keratinocyte carcinoma prevention in solid organ transplant recipients. Arch Dermatol Res 2025;317:807.
[250] Saif MW, Katirtzoglou NA, Syrigos KN. Capecitabine: an overview of the side effects and their management. Anticancer Drugs 2008;19:447–64.
[251] Jirakulaporn T, Endrizzi B, Lindgren B, Mathew J, Lee PK, Dudek AZ. Capecitabine for skin cancer prevention in solid organ transplant recipients. Clin Transpl 2011;25:541–8.
[252] Endrizzi B, Ahmed RL, Ray T, Dudek A, Lee P. Capecitabine to reduce nonmelanoma skin carcinoma burden in solid organ transplant recipients. Dermatol Surg 2013;39:634–45.
[253] Schauder DM, Kim J, Nijhawan RI. Evaluation of the Use of Capecitabine for the Treatment and Prevention of Actinic Keratoses, Squamous Cell Carcinoma, and Basal Cell Carcinoma: A Systematic Review. JAMA Dermatol 2020;156:1117–24.
[254] Cornejo CM, Jambusaria-Pahlajani A, Willenbrink TJ, Schmults CD, Arron ST, Ruiz ES. Field cancerization: Treatment. J Am Acad Dermatol 2020;83:719–30.
[255] Zwald F, Leitenberger J, Zeitouni N, Soon S, Brewer J, Arron S, et al. Recommendations for Solid Organ Transplantation for Transplant Candidates With a Pretransplant Diagnosis of Cutaneous Squamous Cell Carcinoma, Merkel Cell Carcinoma and Melanoma: A Consensus Opinion From the International Transplant Skin Cancer Collaborative (ITSCC). Am J Transpl J Am Soc Transpl Am Soc Transpl Surg 2016;16:407–13.
[256] Coghill AE, Johnson LG, Berg D, Resler AJ, Leca N, Madeleine MM. Immunosuppressive Medications and Squamous Cell Skin Carcinoma: Nested Case-Control Study Within the Skin Cancer after Organ Transplant (SCOT) Cohort. Am J Transpl J Am Soc Transpl Am Soc Transpl Surg 2016;16:565–73.
[257] Vos M, Plasmeijer EI, van Bemmel BC, van der Bij W, Klaver NS, Erasmus ME, et al. Azathioprine to mycophenolate mofetil transition and risk of squamous cell carcinoma after lung transplantation. J Heart Lung Transpl 2018;37:853–9.
[258] Wang M, Mittal A, Colegio OR. Belatacept reduces skin cancer risk in kidney transplant recipients. J Am Acad Dermatol 2020;82:996–8.
[259] Asgari MM, Arron ST, Warton EM, Quesenberry Jr CP, Weisshaar D. Sirolimus use and risk of cutaneous squamous cell carcinoma (SCC) in solid organ transplant recipients (SOTRs). J Am Acad Dermatol 2015;73:444–50.
[260] Phan K, Moloney FJ, Hogarty DT, Lenane P, McColl D, Yazdabadi A. Mammalian target of rapamycin (mTOR) inhibitors and skin cancer risk in nonrenal solid organ transplant recipients: systematic review and meta-analysis. Int J Dermatol 2019.
[261] Knoll GA, Kokolo MB, Mallick R, Beck A, Buenaventura CD, Ducharme R, et al. Effect of sirolimus on malignancy and survival after kidney transplantation: systematic review and meta-analysis of individual patient data. BMJ 2014;349: g6679.
[262] Karia PS, Azzi JR, Heher EC, Hills VM, Schmults CD. Association of Sirolimus Use With Risk for Skin Cancer in a Mixed-Organ Cohort of Solid-Organ Transplant Recipients With a History of Cancer. JAMA Dermatol 2016;152:533–40.
[263] Krisl JC, Doan VP. Chemotherapy and Transplantation: The Role of Immunosuppression in Malignancy and a Review of Antineoplastic Agents in Solid Organ Transplant Recipients. Am J Transpl J Am Soc Transpl Am Soc Transpl Surg 2017;17:1974–91.
[264] Blomberg M, He SY, Harwood C, Arron ST, Demehri S, Green A, et al. Research gaps in the management and prevention of cutaneous squamous cell carcinoma in organ transplant recipients. Br J Dermatol 2017;177:1225–33.
[265] Hirotsu KE, Crowe L, Michalski-McNeely B, Arron ST, Bibee K, Bottomley MJ, et al. Dermatology Scheduling Triage of Transplant Patients and Transplant Candidates to Improve Early Diagnosis and Prevention of Skin Cancer: International Immunosuppression and Transplant Skin Cancer Collaborative Expert Consensus Recommendations. Transpl Int 2025;38:14711.
[266] Acuna SA, Huang JW, Scott AL, Micic S, Daly C, Brezden-Masley C, et al. Cancer Screening Recommendations for Solid Organ Transplant Recipients: A Systematic Review of Clinical Practice Guidelines. Am J Transpl J Am Soc Transpl Am Soc Transpl Surg 2017;17:103–14.
[267] Chan AW, Fung K, Austin PC, Kim SJ, Singer LG, Baxter NN, et al. Improved keratinocyte carcinoma outcomes with annual dermatology assessment after solid organ transplantation: Population-based cohort study. Am J Transpl J Am Soc Transpl Am Soc Transpl Surg 2019;19:522–31.
[268] Crow LD, Jambusaria-Pahlajani A, Chung CL, Baran DA, Lowenstein SE, Abdelmalek M, et al. Initial skin cancer screening for solid organ transplant recipients in the United States: Delphi method development of expert consensus guidelines. Transpl Int 2019;32:1268–76.
[269] Jambusaria-Pahlajani A, Crow LD, Lowenstein S, Garrett GL, Melcher ML, Chan AW, et al. Predicting skin cancer in organ transplant recipients: development of the SUNTRAC screening tool using data from a multicenter cohort study. Transpl Int 2019;32:1259–67.
[270] Gomez-Tomas A, Bouwes Bavinck JN, Genders R, Gonzalez-Cruz C, de Jong E, Arron S, et al. External Validation of the Skin and UV Neoplasia Transplant Risk Assessment Calculator (SUNTRAC) in a Large European Solid Organ Transplant Recipient Cohort. JAMA Dermatol 2023;159:29–36.
[271] Lee DS, Gigoyan L, Sells RE, Nugent JR, Goes NB, Harris HR, et al. Skin Cancer Surveillance Program for Solid Organ Transplant Recipients. JAMA Dermatol 2025.
[272] Mansfield AS, Rabe KG, Slager SL, Schwager SM, Call TG, Brewer JD, et al. Skin cancer surveillance and malignancies of the skin in a community-dwelling cohort of patients with newly diagnosed chronic lymphocytic leukemia. J Oncol Pr 2014; 10:e1–4.
[273] Ishdorj G, Beiggi S, Nugent Z, Streu E, Banerji V, Dhaliwal D, et al. Risk factors for skin cancer and solid tumors in newly diagnosed patients with chronic lymphocytic leukemia and the impact of skin surveillance on survival. Leuk Lymphoma 2019;60:3204–13.
[274] Anderson A, Ferris LK, Click B, Ramos-Rivers C, Koutroubakis IE, Hashash JG, et al. Low Rates of Dermatologic Care and Skin Cancer Screening Among Inflammatory Bowel Disease Patients. Dig Dis Sci 2018;63:2729–39.
[275] Salgo R, Gossmann J, Schofer H, Kachel HG, Kuck J, Geiger H, et al. Switch to a sirolimus-based immunosuppression in long-term renal transplant recipients: reduced rate of (pre-)malignancies and nonmelanoma skin cancer in a prospective, randomized, assessor-blinded, controlled clinical trial. Am J Transpl J Am Soc Transpl Am Soc Transpl Surg 2010;10:1385–93.
[276] Euvrard S, Morelon E, Rostaing L, Goffin E, Brocard A, Tromme I, et al. Sirolimus and secondary skin-cancer prevention in kidney transplantation. N Engl J Med 2012;367:329–39.
[277] Hoogendijk-van den Akker JM, Harden PN, Hoitsma AJ, Proby CM, Wolterbeek R, Bouwes Bavinck JN, et al. Two-year randomized controlled prospective trial converting treatment of stable renal transplant recipients with cutaneous invasive squamous cell carcinomas to sirolimus. J Clin Oncol 2013;31:1317–23.
[278] Campbell SB, Walker R, Tai SS, Jiang Q, Russ GR. Randomized controlled trial of sirolimus for renal transplant recipients at high risk for nonmelanoma skin cancer. Am J Transpl J Am Soc Transpl Am Soc Transpl Surg 2012;12:1146–56.
[279] Bonerandi JJ, Beauvillain C, Caquant L, Chassagne JF, Chaussade V, Clavere P, et al. Guidelines for the diagnosis and treatment of cutaneous squamous cell carcinoma and precursor lesions. J Eur Acad Dermatol Venereol 2011;25(5):1–51.
[280] Rischin D, Porceddu S, Day F, Brungs DP, Christie H, Jackson JE, et al. Adjuvant Cemiplimab or Placebo in High-Risk Cutaneous Squamous-Cell Carcinoma. N Engl J Med 2025;393:774–85.