Clinical Endocrinology

WILEY

REVIEW ARTICLE OPEN ACCESS

Adrenal

Adrenal Vein Sampling for Primary Aldosteronism: Recommendations From the Australian and New Zealand Working Group

Jun Yang[1,2] | Damon A. Bell[3,4] | Richard Carroll[5] | Cherie Chiang[6] | Diane Cowley[7] | Emma Croker[8] | James C. G. Doery[2,9] | Marianne Elston[10] | Paul Glendenning[11] | Julie Hetherington[12] | Andrea R. Horvath[13] | Shanshan Lu-Shirzad[1] | Elisabeth Ng[1] | Amanda Mather[14] | Nimalie Perera[15] | Muddassir Rashid[16,17] | Nirupa Sachithanandan[18,19] | Jimmy Shen[20] | Michael Stowasser[21] | Michael J. Swarbrick[22] | Hong Lin Evelyn Tan[8] | Moe Thuzar[21,23] | Simon Young[24] | Winston Chong[25]

[1]Centre for Endocrinology and Metabolism, Hudson Institute of Medical Research, Clayton, Victoria, Australia | [2]Department of Medicine, Monash University, Clayton, Victoria, Australia | [3]Department of Clinical Biochemistry, Royal Perth Hospital and Fiona Stanley Hospital Network, Pathwest Laboratory Medicine, Perth, Western Australia, Australia | [4]Medical School, University of Western Australia, Perth, Western Australia, Australia | [5]Endocrinology, Diabetes, and Research Centre, Wellington Regional Hospital, Wellington, New Zealand | [6]Royal Melbourne Hospital, Parkville, Victoria, Australia | [7]Princess Alexandra Hospital, Brisbane, Queensland, Australia | [8]Department of Endocrinology, John Hunter Hospital, Lambton Heights, New South Wales, Australia | [9]Monash Pathology, Monash Medical Centre, Clayton, Victoria, Australia | [10]Waikato Clinical Campus, University of Auckland, Hamilton, New Zealand | [11]Department of Clinical Biochemistry, Royal Perth Hospital, Perth, Western Australia, Australia | [12]Endocrinology and Metabolism Centre, Royal Prince Alfred Hospital, Camperdown, New South Wales, Australia | [13]Department of Chemical Pathology, New South Wales Health Pathology, Prince of Wales Hospital, Randwick, New South Wales, Australia | [14]Department of Renal Medicine, Royal North Shore Hospital, St Leonards, New South Wales, Australia | [15]Department of Endocrinology and Chemical Pathology, Royal Prince Alfred Hospital, Camperdown, New South Wales, Australia | [16]Department of interventional radiology, Gold Coast University Hospital, Gold Coast, Queensland, Australia | [17]Bond University Medical School, Gold Coast, Queensland, Australia | [18]Department of Endocrinology, St Vincent's Hospital, Fitzroy, Victoria, Australia | [19]Department of Medicine, The University of Melbourne, Parkville, Australia | [20]Monash Medical Centre, Clayton, Victoria, Australia | [21]Endocrine Hypertension Research Centre, University of Queensland Frazer Institute, Brisbane, Australia | [22]Department of Radiology, Waikato Hospital, Hamilton, New Zealand | [23]Department of Endocrinology, Princess Alexandra Hospital, Wooloongabba, Queensland, Australia | [24]Department of Endocrinology, North Shore Hospital, North Auckland, New Zealand | [25]Department of Radiology, Alfred Hospital, Melbourne, Victoria, Australia

Correspondence: Jun Yang (Jun.yang@hudson.org.au)

Received: 22 July 2024 | **Revised:** 5 September 2024 | **Accepted:** 10 September 2024

Funding: This study was supported by Medical Research Future Fund (MRFF, MRFAR000172).

Keywords: adrenal vein sampling | conn syndrome | endocrine hypertension | hyperaldosteronism | hypertension | primary aldosteronism | subtyping

ABSTRACT

Adrenal vein sampling (AVS) is the current recommended procedure for identifying unilateral subtypes of primary aldosteronism (PA), which are amenable to surgery with the potential for cure. AVS is a technically challenging procedure usually undertaken by interventional radiologists at tertiary centres. However, there are numerous variations in AVS protocols relating to patient preparation, sampling techniques and interpretation which may impact the success of AVS and patient care. To reduce practice variations, improve the success rates of AVS and optimise patient outcomes, we established an Australian and New Zealand AVS Working Group and developed evidence-based expert consensus recommendations for the preparation, performance and interpretation of AVS. These recommendations can be used by all healthcare professionals in a multidisciplinary team who look after the diagnosis and management of PA.

The second to second last authors are listed in alphabetical order.

This is an open access article under the terms of the Creative Commons Attribution-NonCommercial License, which permits use, distribution and reproduction in any medium, provided the original work is properly cited and is not used for commercial purposes.

© 2024 The Author(s). *Clinical Endocrinology* published by John Wiley & Sons Ltd.

1 | Introduction

Primary aldosteronism (PA), the most common endocrine cause of hypertension, is potentially curable when caused by a unilateral aldosterone-producing adrenal adenoma that may be surgically resected. In contrast, bilateral subtypes of PA require lifelong targeted medical treatment. The distinction between these two subtypes is important as surgery is associated with lower all-cause mortality, fewer adverse cardiovascular outcomes and lower risk of progression to chronic kidney disease (CKD) when compared to medical therapy in a meta-analysis of 15,541 patients from 16 studies [1]. Adrenal vein sampling (AVS) is the current recommended procedure for subtyping [2].

AVS involves the cannulation of both adrenal veins and measuring aldosterone and cortisol concentrations compared to peripheral samples to determine the source of aldosterone excess. It is technically challenging and usually undertaken by interventional radiologists, with a higher success rate observed in centres with focussed expertise [3, 4].

There are numerous variations in AVS protocols relating to patient preparation, sampling techniques and interpretation which may impact the success of AVS and patient care [5]. The need for uniform AVS guidelines was highlighted in a recent survey of endocrinologists and interventional radiologists from around Australia and New Zealand [5].

To address this need, we established an Australian and New Zealand AVS Working Group to develop evidence-based expert consensus recommendations for the preparation, performance and interpretation of AVS with the aim of reducing practice variations, improving success rates and optimising patient outcomes.

The Working Group comprised of 11 endocrinologists, 2 endocrine nurses, 3 interventional radiologists, 5 chemical pathologists, 1 nephrologist and 3 consumers. Relevant clinical questions were answered through a comprehensive literature review, using the PICO (Patient, Problem or Population, Intervention, Control or Comparison, Outcome) strategy. In view of limited high-quality evidence in the form of randomised controlled trials or systematic reviews with meta-analyses in the AVS field, the Working Group agreed to develop updated practical consensus recommendations, based on evidence, expertise and previous consensus statements [2, 6], without using the Grading of Recommendations, Assessment, Development and Evaluation (GRADE) framework. The final draft recommendations were circulated for endorsement by the Endocrine Society of Australia (ESA) and the Royal College of Pathologists of Australasia Chemical Pathology Advisory Committee (CPAC).

These recommendations can be used by all healthcare professionals in a multidisciplinary team who look after the diagnosis and management of PA, in healthcare settings where AVS is available. A patient handout was also developed with input from consumers with lived experience.

2 | Part 1—Preparation for AVS

2.1 | Who Should be Referred for AVS?

Rationale: AVS is currently considered the gold standard for identifying surgically curable PA [2, 7–11]. However, AVS is invasive and time-consuming, with limited access in many parts of the world.

Recommendations: In accordance with the Endocrine Society Guidelines for PA, people with a confirmed diagnosis of PA who are considering the option of adrenalectomy and are appropriate surgical candidates should be referred for AVS irrespective of adrenal imaging findings [2, 12, 13].

Exceptions to this include:

I. People aged < 35 years with florid PA (aldosterone > 550 pmol/L, suppressed renin, spontaneous hypokalaemia) and a solitary unilateral adrenal nodule on imaging. This group may proceed to imaging-guided surgery without AVS with a very high likelihood of biochemical cure [2, 14–20]. Some centres extend this exception to age < 45 years [21] or any age [22] if there is a normal contralateral gland on imaging.

II. Those with certain confirmed germline mutations (rare, < 5% of cases) [23].

a Chimeric *CYP11B1/CYP11B2* gene (Familial Hyperaldosteronism Type I, FH-I).

b Germline mutation of *CLCN2* (FH-II), *KCNJ5* (FH-III), *CACNA1H* (FH-IV).

III. Adrenal lesion suspicious for adrenal cortical carcinoma.

There should be no upper age limit to offering AVS if surgery is considered a feasible therapeutic option [24–26].

2.2 | How Should the Patient and Referring Doctor be Educated About AVS?

Rationale: The patient and referring doctor should receive sufficient education about AVS to ensure a clear understanding about the role, risks and benefits of AVS.

Recommendation: In the absence of specific literature, a patient handout based on information sheets from health services in Australia and New Zealand and expert opinions from this Working Group was developed (Figure 1).

2.3 | How Should Patients be Prepared for AVS?

Rationale: Patient preparation is important to minimise confounding factors and obtain meaningful results from AVS.

Recommendation: Patients should have their medications, plasma potassium and renin concentration assessed 4–6 weeks before AVS. Hypokalaemia should be corrected, renin should be

low/suppressed and, where feasible, interfering medications withdrawn (≥ 4–6 weeks for mineralocorticoid receptor antagonists and diuretics, and ≥ 2 weeks for ACE-inhibitors and angiotensin II receptor blockers) before AVS.

Summary of evidence: The recommendation is based on current guidelines and knowledge of the physiological effects of the confounding conditions [2, 6, 27, 28]. Hypokalaemia suppresses aldosterone production while medications which stimulate renin production may increase aldosterone production from the unaffected adrenal gland and mask lateralisation [27]. Mineralocorticoid receptor antagonists may be continued in selected patients to avoid uncontrolled hypertension and severe hypokalaemia, if they have low/suppressed renin [29–31].

2.4 | When and How Should Pre-AVS Adrenal Imaging be Performed?

Rationale: The right adrenal vein is difficult to cannulate. Adrenal CT can be used to localise the adrenal veins [32], and to help exclude the rare adrenocortical carcinoma [33, 34] but is not accurate alone for subtyping [12].

Recommendation: Contrast-enhanced thin-slice CT scans should be performed before AVS to localise the adrenal veins.

Summary of evidence: The right adrenal vein can be localised by CT [32]. More sophisticated imaging techniques on modern CT and MRI scanners, and in the case of CT, optimisation of the

Adrenal Vein Sampling (AVS) Patient Information

WHAT IS ADRENAL VEIN SAMPLING (AVS)?

You have been diagnosed with primary aldosteronism (PA) where the hormone aldosterone is being overproduced in the body. Aldosterone is made by the adrenal glands. PA may involve one or both adrenal glands. If PA involves one gland, surgery to remove the gland can be performed. AVS is done for those who are suitable and willing to undergo surgery.

AVS is a procedure where blood is collected from the adrenal veins, to work out whether the right, left or both glands are overactive. Blood samples are taken directly from the adrenal glands by inserting thin tubes into a vein in the groin and passing them up to the adrenal veins.

AVS is useful even if you have an adrenal tumour on CT, because a tumour on CT may not necessarily be overactive.

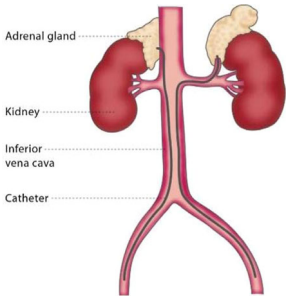

WHAT DO I NEED TO DO TO PREPARE FOR THE PROCEDURE?

4-8 weeks before AVS: Medication changes may be needed.

- Medications which interfere with AVS results will need to be stopped, including some blood pressure and hormonal therapies. Alternative medications can be used to manage blood pressure during this time.

2-4 weeks before AVS:

- Have a blood test: Your endocrinologist/kidney specialist should organise this with you to check your electrolytes (especially your potassium level), kidney function and hormone levels.
- Arrange help: You will need a responsible friend or family member to accompany you home, and if possible, accompany you overnight.
- Inform the Radiology team if you have allergies, diabetes or are pregnant, or if you are taking spironolactone, diuretics, or blood thinning medications.

24 hours before AVS: Avoid alcohol or recreational drugs.

6 hours before AVS: Fast from food for 6 hrs before AVS; clear water can be consumed until 2 hrs before AVS.

You must follow the instructions about taking your blood pressure medication(s) and potassium tablets.

WHAT CAN I EXPECT ON THE DAY?

- AVS takes 2-3 hours in most cases, and up to 5 hours in some cases.
- A small needle (cannula) will be inserted in your arm before AVS.
- Most people do not require sedation for AVS but some radiologists will use it, and they will talk to you about whether it will be given.
- You will lie on a table, the area around your groin will be cleaned with an antiseptic wash, and a sterile cover will be placed over your body.
- Local anaesthetic will be injected in the groin area, which may sting.
- The radiologist will insert 1 or 2 thin plastic tubes into the femoral vein in the groin or into a vein in the elbow.
- Iodinated contrast (X-Ray dye) will be injected to help the radiologist see your blood vessels on X-ray and guide the tube to the adrenal veins. You should not be able to feel the catheters inside your body.
- During the procedure you will lie still and flat on your back.
- Sometimes a medication may need to be given to increase the amount of hormone production in the adrenal glands.
- Once the catheters are in place, blood samples will be collected, which will be sent for hormone analysis.
- There will be at least one radiologist, radiographer and nurse in the room. A radiology trainee, chemical pathologist, Endocrine nurse or Endocrine registrar may also be present.
- Once all samples are collected, the catheter will be removed from the puncture site and firm pressure applied for 10-15 minutes.

FIGURE 1 | Adrenal vein sampling—plain language information for patients.

Adrenal Vein Sampling (AVS) Patient Information

WHAT ARE THE RISKS OF THIS PROCEDURE?

Common risks and complications include:

- Minor pain/bruising at the puncture site or groin.
- Bleeding at the puncture site (usually stopped by applying pressure and limiting movement)

Less common risks include:

- Infection, requiring antibiotics and further treatment.
- Damage to surrounding structures such as blood vessels including the groin (femoral) artery.
- A blood clot or excessive bleeding from the puncture site.
- Adverse effects and hypersensitivity reactions may be experienced with the medications which may be used during AVS, including iodinated contrast, synacthen, pain-relief, or sedative medications.
- The Radiologist may not be able to locate the adrenal veins and therefore will not be successful.

Rare risks and complications include:

- Damage to the groin artery or blood vessels in the abdomen may cause severe internal bleeding which may require surgery. These complications are very uncommon and rarely life threatening.
- Deep vein thrombosis (blood clots) in the leg(s).
- Damage to the adrenal glands may very rarely occur. If both glands are damaged, you may need adrenal hormone replacement.
- Temporary nerve irritation may occur in the groin due to the local anaesthetic. Permanent nerve damage is very rare.
- Life-threatening allergic reaction to contrast or sedation.
- Very small increased risk of lifetime cancer due to X-ray exposure.
- If the procedure is prolonged, there may be some inflammatory skin changes.

The Radiologist will discuss the above with you and obtain your written consent. In general, the risks are outweighed by the potential benefits.

WHAT CAN I EXPECT AFTER THE PROCEDURE?

Immediately:

- You will be transferred onto a bed to lay flat for 2-4 hours to recover.
- There will be nurses looking after you and monitoring your progress.
- You can eat and drink one hour after AVS, or as determined by the radiologist.
- Please advise the nursing staff if you require a medical certificate.

On going home:

- You cannot drive yourself home
- You must be accompanied by an adult and go home by car or taxi
- You must ensure that you avoid any strenuous exercise for the 48 hours after your procedure
- You can shower but keep the dressing site dry, and keep the groin area clean and dry
- You may experience discomfort at the puncture site for 1-2 days.

If given sedation, DO NOT:

- Drive any type of car, bike or other vehicle.
- Operate machinery including cooking implements.
- Make important decisions or sign a legal document.
- Drink alcohol, take other mind-altering substances, or smoke. They may react with the anaesthetic drugs.

If you experience any of the following, present to your nearest Emergency Department or GP

- Swelling, lumps or continuous bleeding at the puncture site or in the limb.
- Fever or other signs of an infection.
- Severe abdominal pain.

TO FIND OUT THE RESULTS OF YOUR AVS

The hormone levels tested in AVS can take several days to weeks to be processed and then analysed. A clinic appointment will be made by your requesting doctor to discuss these results with you.

FIGURE 1 | (Continued)

contrast enhancement phase, have increased the reliability of visualisation of the right adrenal vein [35–38]. These methods can improve AVS success rates and reduce radiation dose [39–41].

3 | Performance of AVS

3.1 | Should AVS be Performed via a Simultaneous or Sequential Approach?

Rationale: Both sequential and simultaneous AVS are used in practice [4] with theoretical advantages and disadvantages to each approach.

Recommendation: Simultaneous sampling is recommended, where possible, to avoid biological variations in cortisol and aldosterone production over time. If sequential sampling is used, the right adrenal vein should be cannulated first to minimise the time between sampling the two sides (< 5 min).

Summary of evidence: There are limited retrospective studies with conflicting results. A comparison of simultaneous and simulated sequential sampling results at baseline and 15 min after the start of AVS found simultaneous sampling more accurate for lateralisation [42] but a difference was not found in two other studies where adrenal vein samples were

collected within 5 min [43, 44]. Hence, in sequential AVS, the right adrenal vein should be cannulated first to minimise the time elapsed between two sides, as the left adrenal vein is easier to cannulate.

3.2 | Should AVS be Done With, Without or Both Pre- and Post-ACTH Stimulation?

Rationale: ACTH stimulation during AVS improves the rate of successful adrenal vein catheterisation, but its impact on lateralisation is debated.

Recommendation: ACTH stimulation is recommended, but it may reduce lateralisation rates. In centres that perform AVS both before and after ACTH stimulation, discordant lateralisation may reflect asymmetric bilateral disease. Greater value is placed on the post-ACTH lateralisation index, with consideration of the patient's clinical, biochemical and radiological parameters.

Summary of evidence: Studies have consistently demonstrated an increase in catheterisation success with ACTH administration, due to enhanced gradient between adrenal vein and peripheral vein cortisol concentrations, leading to improved ability to recognise successful cannulation with a reduction in the proportion of nondiagnostic studies [45–50]. ACTH stimulation can also prevent sampling during a quiescent phase of aldosterone production (discussed in Section 3.9).

In contrast, lateralisation can be discordant in up to 40% of subjects when comparing pre- and post-ACTH stimulated results [47, 48, 50–57]. Patients who only lateralized pre-ACTH experienced less biochemical cures than those with concordant lateralisation [57]. Patients with discordant AVS results tend to have milder disease (lower rate of hypokalaemia, lower aldosterone concentration) compared to those with concordant results [47, 48, 56, 57]. One study suggested that simultaneous bilateral AVS performed both pre- and post-ACTH stimulation maximises the identification of surgically curable PA [58] while another reported that the loss of lateralisation post-ACTH stimulation (with LI < 2) was associated with lack of surgical cure [54]. Indeed, a large multicentre study of 283 patients found that the odds of achieving a surgical cure for PA was 13.3-fold lower in those with exclusive pre-ACTH lateralisation versus those with concordant lateralisation both pre- and post-ACTH [59]. Therefore, to reduce the possibility of unnecessary adrenalectomy, greater value may be placed on the poststimulation LI with a minimum of two required for lateralisation, whilst considering other characteristics suggestive of unilateral PA such as contralateral aldosterone suppression, suppressed baseline renin with markedly elevated aldosterone concentrations and a history of hypokalaemia [22]. In the only RCT comparing ACTH versus non-ACTH stimulated AVS, there was no difference in cannulation success or surgical outcomes [60], although the study was conducted in an expert centre in China and may not be generalisable. To maximise outcome data for decision making, several expert centres conduct AVS both before and after ACTH stimulation [50, 51, 54, 61].

3.3 | What Is the Role of Point of Care (POC) Testing During AVS to Assess Cannulation Success in Real Time?

Rationale: Cannulation of adrenal veins is technically challenging with reported success rate as low as 30% in some centres [62]. Higher cortisol concentration in the samples drawn from the adrenal veins relative to the peripheral vein or inferior vena cava (IVC) is an indication of adrenal vein cannulation success in individuals without autonomous cortisol production [28, 63]. Rapid POC measurement of cortisol with real-time feedback to the radiologist may allow catheter position readjustment and immediate sample recollection as needed, thereby potentially improving the success of AVS.

Recommendation: Rapid cortisol assays can be used to improve adrenal vein cannulation success, particularly for less experienced operators, and AVS performed without ACTH stimulation.

Summary of evidence: A systematic review and meta-analysis including 3485 patients from 11 studies found that bilateral adrenal vein selectivity was significantly higher for AVS performed with intraprocedural cortisol measurements compared with routine AVS (84% vs. 64%, 95% confidence interval: 1.27–1.59, $p < 0.01$), especially for non-ACTH-stimulated AVS [64].

The improvement in AVS cannulation success rate with POC cortisol was most evident in less experienced centres, although potential 'training effect' (acquisition of skill by the operators over time) could not be excluded [62, 65–68]. However, even in a tertiary centre with experienced operators, cannulation success rate increased from 81% to 93% with POC cortisol [69] and cost saving was demonstrated in another centre [67]. The turnaround time for a POC kit was approximately 5 min [70] while others employing laboratory analysers reported turn-around time of 0.5–2 h [65, 69, 71, 72].

3.4 | What Are the Options for Sedation or Analgesia During AVS?

Rationale: Interventional radiologists may administer intravenous anxiolytics before procedures for patient comfort. Sedatives affect cortisol and possibly aldosterone production and may impact AVS results [73–75].

Recommendation: When sedation is required during AVS, ACTH stimulation should be used to overcome the suppressive effect of midazolam or fentanyl on cortisol production.

Summary of evidence: Two studies which evaluated the effect of low-dose intravenous midazolam (1–2 mg) and fentanyl (25–50 mg) on AVS outcomes reported a reduction in cortisol levels post-sedation in non-ACTH-stimulated AVS while the effect was abolished following ACTH infusion [76, 77]. Low adrenal vein cortisol concentration could lead to the false assessment of 'failed cannulation', especially if POC cortisol is used to determine cannulation success in real time. The effect of sedation on aldosterone remains unclear, as the two studies reported either lower or comparable aldosterone levels following sedation.

3.5 | How to Perform AVS in Patients With Contrast Allergy?

Rationale: Of patients undergoing AVS, 2.6%–4% have a history of iodinated contrast allergy [78, 79] who may require premedication with glucocorticoids and anti-histamines [80]. Glucocorticoids can diminish ACTH release leading to reduced cortisol production [42, 78].

Recommendation: Immunology opinion should be sought to determine the most appropriate premedication regimen. If glucocorticoid premedication is required, dexamethasone with ACTH stimulation is recommended.

Summary of evidence: Dexamethasone has negligible cross-reactivity with cortisol assays as compared to prednisone, hydrocortisone or methylprednisolone [79, 81, 82]. ACTH stimulation is recommended with dexamethasone to overcome suppression of basal cortisol and aldosterone secretion [79, 81]. Two to three doses of 6–8 mg dexamethasone can be given starting 10–12 h before AVS [79, 81]. In patients who require other glucocorticoids, adrenal androgens, DHEA and metanephrine could be measured instead of cortisol to assess selectivity and lateralisation [83–87]. The use of gadolinium contrast for people with iodine allergy has been reported in case studies [88, 89] but contrast volume should be minimised to avoid nephrogenic systemic fibrosis [90].

3.6 | How to Perform AVS in Patients With CKD?

Rationale: Patients with preexisting CKD with eGFR < 60 mL/min/1.73 m^2 are known to be at increased risk of contrast-induced nephropathy [91], yet AVS cannot be performed reliably without contrast guidance.

Recommendation: The use of IV contrast in AVS in patients with CKD should be managed similar to other procedures [92], focussing on minimal contrast volume and referral to an expert centre.

Summary of evidence: The risk of IV contrast media-related acute kidney injury is likely to be negligible for patients with eGFR > 45 mL/min/1.73 m^2, and negligible to low for eGFR 30–45. For those with eGFR < 30, periprocedural hydration with intravenous saline should be considered [92]. A single centre study reported 96% procedural success in 25 patients with CKD (eGFR < 60), who received peri- and intraprocedural sodium bicarbonate infusion [93]. The mean volume of contrast given was 37 mL (range, 10–250 mL; median, 25 mL). Contrast-induced acute kidney injury was only documented in two patients, one who received 250 mL of contrast and another with Stage V CKD, whose renal function returned to baseline within 4 weeks.

Several techniques have been reported to reduce contrast volume, including POC cortisol testing [94], pre-AVS adrenal vein localisation with CT [41] and multipurpose catheter [95]. Referring patients with CKD to an expert centre has theoretical advantages of higher likelihood of success (see Section 3.8).

3.7 | What Are the Complications of AVS and How to Prevent/Manage Them?

Rationale: AVS is an invasive procedure requiring informed consent from patients. Clinicians should be aware of their local complication rates in comparison to the international literature.

Recommendation: Complications from AVS are uncommon, including adrenal vein rupture and adrenal haemorrhage. In the case of adrenal haemorrhage, symptomatic management is required together with an assessment of adrenal function. Increased operator expertise may help minimise complications.

Summary of evidence: AVS complications are uncommon with a median rate of 0.85% (IQR 0, 1.4%) based on retrospective series [4, 41, 55, 66, 72, 94, 96–111]. The most reported complications are adrenal vein rupture and adrenal haemorrhage but also include contrast extravasation, periadrenal haemorrhage, femoral puncture site complications and allergic reaction. A retrospective study focusing on adrenal haemorrhage reported a complication rate of approximately 0.8% with risk factors including sampling of the right adrenal vein and older age [103]. Rates of adrenal vein rupture have been reported to correlate inversely with radiologist experience [4].

Adrenal haemorrhage should be considered if chest, abdominal or back pain develops during or following the procedure. Non-contrast CT is recommended for diagnosis. Conservative management is usual with analgesia as required [103]. Adrenal function should be assessed if there is a bilateral adrenal haemorrhage or contralateral adrenalectomy is planned. Repeat AVS after adrenal haemorrhage has been reported to be performed safely in two patients [103].

3.8 | What to do in the Setting of Inconclusive AVS Results Due to Unsuccessful Cannulation of One or Both Adrenal Veins?

Rationale: Unsuccessful cannulation of the adrenal veins, especially the right adrenal vein, is more common with lower experience [112].

Recommendations: Repeating the study following adrenal vein localisation by CT, ideally by operators who perform at least 15 procedures per year, utilising POC cortisol measurements and/or ACTH stimulation, is recommended. If AVS is unilaterally selective, the adrenal vein/IVC indices may be useful for subtyping in conjunction with clinical, biochemical and radiological characteristics.

Summary of evidence: A learning curve of 20–32 cases has been well described in AVS [72, 101, 102]. Success rates of AVS improved from 50%–60% to 80%–95% after 30–50 procedures are performed, with > 15–25 procedures needed per year to maintain a success rate of ~95% over 8 years [62, 101, 108]. If < 20 procedures are performed annually, these should be performed by a single operator [61, 101].

Adrenal vein localisation by CT before AVS (see Section 2.4), POC cortisol testing (see Section 3.3) and ACTH stimulation (see Section 3.2) can improve cannulation success.

Following the failure of right adrenal vein cannulation, a study of 36 ACTH-stimulated AVS procedures proposed a left adrenal vein aldosterone/cortisol:IVC aldosterone/cortisol ratio > 5.5 for diagnosing ipsilateral unilateral PA and ≤ 0.5 for contralateral unilateral PA, achieving 100% specificity [113]. However, subsequent studies did not validate these ratios [111] or only found the ratio of ≤ 0.5 to be useful [114, 115]. An ensuing study of 987 AVS procedures suggested decision limits of > 2.55 or ≤ 0.96, but the specificity was lower at 85% [116]. Another study of 455 patients proposed decision limits of > 17.05 and < 0.15 to achieve 100% specificity (in unstimulated AVS), although those could be lowered to > 3.60 and < 0.70 when combined with CT findings of a unilateral adrenal nodule > 10 mm [117]. Hypokalaemia, high aldosterone concentration, suppressed renin and a unilateral adrenal adenoma also support the diagnosis of unilateral PA [22].

Alternative subtyping strategies, including algorithms, functional imaging and steroid metabolite profiling, may supplement AVS in the future [118–123].

3.9 | What to do in the Setting of Apparent Bilateral Aldosterone Suppression (ABAS) During AVS?

Rationale: ABAS can occur when aldosterone secretion is quiescent, super-selective cannulation fails to collect venous effluent from an aldosterone producing adenoma, aberrant venous drainage is present, or there is ectopic secretion [122].

Recommendation: Review cross-sectional imaging of venous anatomy to identify aberrant venous drainage and/or repeat AVS, preferably with ACTH stimulation. There are insufficient and contradictory findings to recommend the use of super-selective cannulation.

Summary of evidence: Aldosterone secretion varies up to fourfold within minutes during sampling studies. ACTH stimulation may reduce stress-induced fluctuations and increase aldosterone secretion from an aldosterone producing adenoma. ABAS occurs between 2.6% [124], 9.5% [125] and 18% [126] of studies without ACTH stimulation and between 2.05% [125] and 7.6% [126] after ACTH stimulation. Repeating AVS may be technically successful in 80% of cases [124].

To detect aberrant venous drainage, a late venous scan can be used to map venous anatomy. In a study of 20 cases of ABAS, two had repeat studies with identifiable anomalous venous drainage [126].

Super-selective cannulation may allow sampling of all draining portions of the adrenal gland, including the hypersecreting segment, with four of six procedures technically successful in one series following ABAS on initial AVS [127]. However, dilution of the blood sample with low aldosterone concentration from the left inferior phrenic vein [126] or super-selective cannulation of the right adrenal vein may cause ABAS [128].

4 | Part 3—Interpretation of AVS

4.1 | How Should Cannulation Success be Assessed?

Rationale: The concentration of adrenal hormones decreases exponentially according to distance from the adrenal glands. The current gold standard for cannulation success is based on the measured cortisol with the assumption that production is stable bilaterally throughout sampling. A high selectivity index (SI), calculated as the cortisol concentration in the adrenal vein divided by the cortisol concentration in the IVC, indicates adequate cannulation.

Recommendation: For unstimulated AVS, an SI cut-off ≥ 2 is considered successful cannulation [2, 6, 129–131]. For ACTH-stimulated AVS, an SI cut-off ≥ 5 reflects successful cannulation [28, 132, 133] although some consider an SI ≥ 3 to be sufficient [6, 129].

Summary of evidence: The recommendations are based on expert consensus and retrospective data (summarised in [134]) as there are no prospective outcome-based diagnostic studies. Prospective studies to assess PA surgical outcomes using paired SI and lateralisation indices (LI) found that non-stimulated SI ≥ 2 and LI ≥ 2 or poststimulated SI ≥ 5 and LI ≥ 4 led to 80%–90% biochemical success following adrenalectomy [48]. Unstimulated SI ≥ 2 is supported by multiple studies and guidelines [28, 131] while ACTH-stimulated SI recommendations range from ≥ 3 to ≥ 5 with ≥ 5 being more common [2, 28, 135–137].

Cortisol is not the ideal selectivity marker, due to its relatively low adrenal to peripheral gradient in the absence of ACTH stimulation, and the potential for interference by sedation (see Section 3.4) or adrenal Cushing's (see Section 4.3). Other adrenal hormones have been explored, including androstenedione, DHEA, 17-α-hydroxyprogesterone and metanephrine (see Section 4.3), but these require validation before routine use [83, 85, 138].

4.2 | How Should Lateralisation be Assessed?

Rationale: Determining the laterality of excess aldosterone secretion and identifying surgically curable disease is the main aim of AVS. Several parameters have been utilised to determine lateralisation including: (1) LI calculated as the aldosterone to cortisol ratio on the dominant side divided by the same ratio on the nondominant side; (2) contralateral suppression ratio (CSR) calculated as the aldosterone to cortisol ratio on the nondominant side divided by the same ratio in the IVC; (3) AV/IVC ratio calculated as the aldosterone to cortisol ratio in either adrenal vein divided by the same ratio in the IVC. There is variability in how these parameters are used to determine lateralisation.

Recommendation: Following successful bilateral adrenal vein cannulation, aldosterone production is considered lateralized when the aldosterone-cortisol ratio on one side is at least fourfold higher than the contralateral side (i.e., LI ≥ 4), irrespective of ACTH-stimulation.

Summary of evidence: The recommendations for LI ≥ 4 is based on expert consensus. A study of 40 non-PA hypertensive

patients demonstrated that none had LI ≥ 4 in AVS [139]. However, even patients with LI ≥ 4 may experience lack of biochemical cure after adrenalectomy due to asymmetric bilateral disease [59]. In cases where the LI is between 2 and 4, additional features may support the diagnosis of unilateral PA. These include biochemical characteristics of florid PA (PAC > 550pmol/L, renin < 5mU/L, hypokalaemia) or contralateral suppression with CSR < 1 in AVS [140–142]. A number of studies reported that LI > 4 pre-ACTH is crucial for predicting surgical cure while LI could be as low as > 2 post-ACTH stimulation [54, 58]. The AV/IVC ratio is not widely used for lateralisation but may be useful in patients with unilaterally selected AVS (see Section 3.8). The lateralisation result should be prioritised over adrenal imaging for decision making regarding adrenalectomy as it is associated with higher rates of biochemical cure following surgery [143], even in the context of bilateral or contralateral adrenal adenomas [59]. However, no procedure is perfect and even AVS showing lateralisation may lead to lack of surgical cure, especially in people of African background and where there is loss of lateralisation post-ACTH infusion [59].

4.3 | How to Interpret AVS Results in Patients With Autonomous Cortisol Secretion?

Rationale: Concomitant autonomous cortisol secretion, as defined by a morning cortisol > 50 nmol/L following a 1 mg overnight dexamethasone suppression test, occurs in approximately 5%–18% of patients with PA [144–149] and may confound the interpretation of AVS results [130, 150]. In the case of increased cortisol production from an adrenal adenoma with contralateral cortisol suppression, cannulation may be deemed unsuccessful on the contralateral side when it is actually successful, while the aldosterone to cortisol ratio on the side of the adenoma may be low and therefore mask lateralisation [144].

Recommendation: Mild autonomous cortisol excess as indicated by cortisol concentration of 50–137 nmol/L post 1 mg dexamethasone overnight has not been reported to significantly alter cannulation or lateralisation outcomes during AVS. However, individuals with cortisol > 137 nmol/L post 1 mg dexamethasone suppression may require the measurement of additional markers, such as plasma metanephrine, during AVS to assess for selectivity and lateralisation.

Summary of evidence: Two retrospective studies (one case-control, one cohort) suggested that the SI, LI and CSR were not significantly altered in individuals with autonomous cortisol secretion, with and without the use of ACTH stimulation [145, 151]. However, individuals with cortisol > 137nmol/L (5 ug/dL) post 1 mg DST, had significantly lower LI [151]. Current evidence suggests that the measurement of plasma metanephrine, which displays minimum fluctuation during stress and a higher adrenal-peripheral gradient compared to cortisol [152], is useful in these cases to assess selectivity and lateralisation. Suggested thresholds include SI > 12 and LI > 4 where metanephrine replaced cortisol in the calculation of SI and LI, although validation is required [87, 138, 149, 153–155].

5 | Conclusion

A harmonised and evidence-based approach to AVS should improve the standard of AVS and lead to better patient outcomes across centres. It may also equip centres for upscaling AVS to meet increased demand given the increased recognition of PA as a common secondary cause of hypertension. The lack of high-level evidence for these recommendations stresses the need for quality clinical trials which may be facilitated by standardised procedures across centres. Given the key role that AVS plays in identifying surgically curable PA, further efforts to optimise the procedure, in addition to identifying accurate alternative subtyping strategies for low-resource health settings, are warranted.

Acknowledgements

We acknowledge the contribution of Ms Susan Bedford, Mr John Malios and Ms Pamela Lincoln, who contributed to AVS guideline development as consumer advocates and provided valuable patient perspectives on AVS. We also acknowledge the endorsement of these recommendations from the Endocrine Society of Australia (ESA) and the Royal College of Pathologists of Australasia (RCPA) Chemical Pathology Advisory Committee (CPAC). The authors acknowledge the specific project funding contribution from the Medical Research Future Fund (MRFF, MRFAR000172). Open access publishing facilitated by Monash University, as part of the Wiley - Monash University agreement via the Council of Australian University Librarians.

References

1. S. Samnani, I. Cenzer, G. A. Kline, et al., "Time to Benefit of Surgery vs. Targeted Medical Therapy for Patients With Primary Aldosteronism: A Meta-Analysis," *Journal of Clinical Endocrinology and Metabolism* 109, no. 3 (2024): e1280–e1289.

2. J. W. Funder, R. M. Carey, F. Mantero, et al., "The Management of Primary Aldosteronism: Case Detection, Diagnosis, and Treatment: An Endocrine Society Clinical Practice Guideline," *Journal of Clinical Endocrinology & Metabolism* 101, no. 5 (2016): 1889–1916.

3. K. N. Muhamad Pauzi, R. Zakaria, Y. Y. Leong, N. F. Nik Fuad, N. A. Nik Ismail, and N. Sukor, "Success Rate of Adrenal Venous Sampling and Its Determining Factors: Experience of a Single Center in Malaysia," *Annals of Vascular Surgery* 98 (2024): 258–267.

4. G. P. Rossi, M. Barisa, B. Allolio, et al., "The Adrenal Vein Sampling International Study (AVIS) for Identifying the Major Subtypes of Primary Aldosteronism," *Journal of Clinical Endocrinology & Metabolism* 97, no. 5 (2012): 1606–1614.

5. E. Ng, W. Chong, K. K. Lau, et al., "The Where, Who and How of Adrenal Vein Sampling in Australia and New Zealand," *Journal of Medical Imaging and Radiation Oncology* 68, no. 1 (2024): 87–93.

6. G. P. Rossi, R. J. Auchus, M. Brown, et al., "An Expert Consensus Statement on Use of Adrenal Vein Sampling for the Subtyping of Primary Aldosteronism," *Hypertension* 63, no. 1 (2014): 151–160.

7. P. Mulatero, L. A. Sechi, T. A. Williams, et al., "Subtype Diagnosis, Treatment, Complications and Outcomes of Primary Aldosteronism and Future Direction of Research: A Position Statement and Consensus of the Working Group on Endocrine Hypertension of the European Society of Hypertension," *Journal of Hypertension* 38, no. 10 (2020): 1929–1936.

8. S. Bardet, B. Chamontin, C. Douillard, et al., "SFE/SFHTA/AFCE Consensus on Primary Aldosteronism, Part 4: Subtype Diagnosis," *Annales d'Endocrinologie* 77, no. 3 (2016): 208–213.

9. A. A. Leung, K. Nerenberg, S. S. Daskalopoulou, et al., "Hypertension Canada's 2016 Canadian Hypertension Education Program Guidelines

for Blood Pressure Measurement, Diagnosis, Assessment of Risk, Prevention, and Treatment of Hypertension," *Canadian Journal of Cardiology* 32, no. 5 (2016): 569–588.

10. M. Naruse, T. Katabami, H. Shibata, et al., "Japan Endocrine Society Clinical Practice Guideline for the Diagnosis and Management of Primary Aldosteronism 2021," *Endocrine Journal* 69, no. 4 (2022): 327–359.

11. V.-C. Wu, Y.-H. Hu, L. K. Er, et al., "Case Detection and Diagnosis of Primary Aldosteronism: The Consensus of Taiwan Society of Aldosteronism," *Journal of the Formosan Medical Association* 116, no. 12 (2017): 993–1005.

12. Y. Zhou, D. Wang, L. Jiang, et al., "Diagnostic Accuracy of Adrenal Imaging for Subtype Diagnosis in Primary Aldosteronism: Systematic Review and Meta-Analysis," *BMJ Open* 10, no. 12 (2020): e038489.

13. Y. Yan, H.-W. Sun, and Y. Qi, "Prognosis of Adrenalectomy Guided by Computed Tomography Versus Adrenal Vein Sampling in Patients With Primary Aldosteronism: A Systematic Review and Meta-Analysis," *Journal of Clinical Hypertension* 24, no. 2 (2022): 106–115.

14. L. Zhu, Y. Zhang, H. Zhang, et al., "Comparison Between Adrenal Venous Sampling and Computed Tomography in the Diagnosis of Primary Aldosteronism and in the Guidance of Adrenalectomy," *Medicine* 95, no. 39 (2016): e4986.

15. H. Wachtel, S. Zaheer, P. K. Shah, et al., "Role of Adrenal Vein Sampling in Primary Aldosteronism: Impact of Imaging, Localization, and Age," *Journal of Surgical Oncology* 113, no. 5 (2016): 532–537.

16. H. Umakoshi, T. Ogasawara, Y. Takeda, et al., "Accuracy of Adrenal Computed Tomography in Predicting the Unilateral Subtype in Young Patients With Hypokalaemia and Elevation of Aldosterone in Primary Aldosteronism," *Clinical Endocrinology* 88, no. 5 (2018): 645–651.

17. T. A. Williams, J. Burrello, L. A. Sechi, et al., "Computed Tomography and Adrenal Venous Sampling in the Diagnosis of Unilateral Primary Aldosteronism," *Hypertension* 72, no. 3 (2018): 641–649.

18. S. H. Lee, J. W. Kim, H.-K. Yoon, et al., "Diagnostic Accuracy of Computed Tomography in Predicting Primary Aldosteronism Subtype According to Age," *Endocrinology and Metabolism* 36, no. 2 (2021): 401–412.

19. E. Gkaniatsa, A. Sakinis, M. Palmér, A. Muth, P. Trimpou, and O. Ragnarsson, "Adrenal Venous Sampling in Young Patients With Primary Aldosteronism. Extravagance or Irreplaceable?," *Journal of Clinical Endocrinology & Metabolism* 106, no. 5 (2021): e2087–e2095.

20. R. Kaur and S. Young, "Discordant Imaging: Adrenal Vein Sampling in Almost Half of Patients With Primary Aldosteronism and a Unilateral Adrenal Adenoma," *Internal Medicine Journal* 53, no. 8 (2023): 1409–1414.

21. G. P. Rossi, F. Crimì, G. Rossitto, et al., "Feasibility of Imaging-Guided Adrenalectomy in Young Patients With Primary Aldosteronism," *Hypertension* 79, no. 1 (2022): 187–195.

22. Y. Song, J. Yang, H. Shen, et al., "Development and Validation of Model for Sparing Adrenal Venous Sampling in Diagnosing Unilateral Primary Aldosteronism," *Journal of Hypertension* 40, no. 9 (2022): 1692–1701.

23. F. L. Fernandes-Rosa, S. Boulkroun, B. Fedlaoui, et al., "New Advances in Endocrine Hypertension: From Genes to Biomarkers," *Kidney International* 103, no. 3 (2023): 485–500.

24. M. Takeda, K. Yamamoto, H. Akasaka, et al., "Clinical Characteristics and Postoperative Outcomes of Primary Aldosteronism in the Elderly," *Journal of Clinical Endocrinology & Metabolism* 103, no. 10 (2018): 3620–3629.

25. P. Mulatero, J. Burrello, T. A. Williams, and S. Monticone, "Primary Aldosteronism in the Elderly," *Journal of Clinical Endocrinology & Metabolism* 105, no. 7 (2020): e2320–e2326.

26. P. Parra Ramírez, P. M. Rojas-Marcos, M. Paja Fano, et al., "Differences in the Presentation and Evolution of Primary Aldosteronism in Elderly (≥65 Years) and Young Patients (<65 Years)," *Endocrine Connections* 11, no. 6 (2022): e220169.

27. M. Stowasser and R. D. Gordon, "Primary Aldosteronism: Changing Definitions and New Concepts of Physiology and Pathophysiology Both Inside and Outside the Kidney," *Physiological Reviews* 96, no. 4 (2016): 1327–1384.

28. M. Reincke, I. Bancos, P. Mulatero, U. I. Scholl, M. Stowasser, and T. A. Williams, "Diagnosis and Treatment of Primary Aldosteronism," *Lancet Diabetes & Endocrinology* 9, no. 12 (2021): 876–892.

29. M. Ganesh, S. S. Abadin, and L. Fogelfeld, "Adrenal Vein Sampling Without Discontinuation of Mineralocorticoid Receptor Antagonist Therapy," *Endocrine Practice* 26, no. 9 (2020): 953–959.

30. A. T. Nanba, T. Wannachalee, J. J. Shields, et al., "Adrenal Vein Sampling Lateralisation Despite Mineralocorticoid Receptor Antagonists Exposure in Primary Aldosteronism," *Journal of Clinical Endocrinology & Metabolism* 104, no. 2 (2018): 487–492.

31. G. Pintus, T. M. Seccia, L. Amar, et al., "Subtype Identification of Surgically Curable Primary Aldosteronism During Treatment With Mineralocorticoid Receptor Blockade," *Hypertension* 81 (2024): 1391–1399.

32. N. Daunt, "Adrenal Vein Sampling: How to Make It Quick, Easy, and Successful," supplement, *Radiographics* 25, no. S1 (2005): S143–S158.

33. Y. Ohkubo, Y. Shimada, H. Tanaka, M. Yamazaki, and M. Komatsu, "A Case of Primary Aldosteronism Turned Out to be Adrenocortical Carcinoma With Disorganized Steroidogenesis," *Cureus* 16, no. 1 (2024): e52137.

34. L. Amar, P. F. Plouin, and O. Steichen, "Aldosterone-Producing Adenoma and Other Surgically Correctable Forms of Primary Aldosteronism," *Orphanet Journal of Rare Diseases* 5 (2010): 9.

35. Y. Noda, S. Goshima, S. Nagata, et al., "Right Adrenal Vein: Comparison Between Adaptive Statistical Iterative Reconstruction and Model-Based Iterative Reconstruction," *Clinical Radiology* 73, no. 6 (2018): 594.e1–594.e6.

36. Y. Takahashi, H. Ota, K. Omura, et al., "Image Quality and Radiation Dose of Low-Tube-Voltage CT With Reduced Contrast Media for Right Adrenal Vein Imaging," *European Journal of Radiology* 98 (2018): 150–157.

37. K. Nakayama, M. Shimohira, M. Nakagawa, et al., "Advanced Monoenergetic Reconstruction Technique in Dual-Energy Computed Tomography for Evaluation of Vascular Anatomy Before Adrenal Vein Sampling," *Acta Radiologica* 61, no. 2 (2020): 282–288.

38. H. Ota, K. Seiji, M. Kawabata, et al., "Dynamic Multidetector CT and Non-Contrast-Enhanced MR for Right Adrenal Vein Imaging: Comparison With Catheter Venography in Adrenal Venous Sampling," *European Radiology* 26, no. 3 (2016): 622–630.

39. S. Onozawa, S. Murata, H. Yamaguchi, et al., "Can an Enhanced Thin-Slice Computed Tomography Delineate the Right Adrenal Vein and Improve the Success Rate?," *Japanese Journal of Radiology* 34, no. 9 (2016): 611–619.

40. I. Lee and K. K. Lau, "Image Fusion-Augmented Angiography Improves Right Adrenal Vein Cannulation Success Rate in Adrenal Vein Sampling," *American Journal of Roentgenology* 217, no. 4 (2021): 945–946.

41. L. Well, C. Spink, A. Lenz, et al., "Pre-Interventional Assessment of Right Renal to Right Adrenal Vein Distance: Impact on Procedure Time and Radiation Dose in Adrenal Vein Sampling," *PLoS One* 17, no. 12 (2022): e0279552.

42. G. Rossitto, M. Battistel, G. Barbiero, et al., "The Subtyping of Primary Aldosteronism by Adrenal Vein Sampling: Sequential Blood Sampling Causes Factitious Lateralization," *Journal of Hypertension* 36, no. 2 (2018): 335–343.

43. M. K. Almarzooqi, M. Chagnon, G. Soulez, et al., "Adrenal Vein Sampling in Primary Aldosteronism: Concordance of Simultaneous vs Sequential Sampling," *European Journal of Endocrinology* 176, no. 2 (2017): 159–167.

44. C. E. Carr, C. Cope, D. L. Cohen, D. L. Fraker, and S. O. Trerotola, "Comparison of Sequential Versus Simultaneous Methods of Adrenal Venous Sampling," *Journal of Vascular and Interventional Radiology* 15, no. 11 (2004): 1245-3.

45. M. J. Wolley, A. H. Ahmed, R. D. Gordon, and M. Stowasser, "Does ACTH Improve the Diagnostic Performance of Adrenal Vein Sampling for Subtyping Primary Aldosteronism?," *Clinical Endocrinology* 85, no. 5 (2016): 703–709.

46. G. A. Kline, B. So, V. C. Dias, A. Harvey, and J. L. Pasieka, "Catheterization During Adrenal Vein Sampling for Primary Aldosteronism: Failure to Use (1–24) ACTH May Increase Apparent Failure Rate," *Journal of Clinical Hypertension* 15, no. 7 (2013): 480–484.

47. N. Yozamp, G. L. Hundemer, M. Moussa, et al., "Adrenocorticotropic Hormone-Stimulated Adrenal Venous Sampling Underestimates Surgically Curable Primary Aldosteronism: A Retrospective Cohort Study and Review of Contemporary Studies," *Hypertension* 78, no. 1 (2021): 94–103.

48. Y. Takeda, H. Umakoshi, Y. Takeda, et al., "Impact of Adrenocorticotropic Hormone Stimulation During Adrenal Venous Sampling on Outcomes of Primary Aldosteronism," *Journal of Hypertension* 37, no. 5 (2019): 1077–1082.

49. G. Rossitto, L. Amar, M. Azizi, et al., "Subtyping of Primary Aldosteronism in the AVIS-2 Study: Assessment of Selectivity and Lateralisation," *Journal of Clinical Endocrinology and Metabolism* 105, no. 6 (2020): dgz017.

50. N. El Ghorayeb, T. L. Mazzuco, I. Bourdeau, et al., "Basal and Post-ACTH Aldosterone and Its Ratios Are Useful During Adrenal Vein Sampling in Primary Aldosteronism," *Journal of Clinical Endocrinology & Metabolism* 101, no. 4 (2016): 1826–1835.

51. T. Wannachalee, L. Zhao, K. Nanba, et al., "Three Discrete Patterns of Primary Aldosteronism Lateralization in Response to Cosyntropin During Adrenal Vein Sampling," *Journal of Clinical Endocrinology and Metabolism* 104, no. 12 (2019): 5867–5876.

52. Y. Fujii, Y. Takeda, I. Kurihara, et al., "Historical Changes and Between-Facility Differences in Adrenal Venous Sampling for Primary Aldosteronism in Japan," *Journal of Human Hypertension* 34, no. 1 (2020): 34–42.

53. S. Monticone, F. Satoh, G. Giacchetti, et al., "Effect of Adrenocorticotropic Hormone Stimulation During Adrenal Vein Sampling in Primary Aldosteronism," *Hypertension* 59, no. 4 (2012): 840–846.

54. N. Y. N. Chee, A. Abdul-Wahab, R. Libianto, et al., "Utility of Adrenocorticotropic Hormone in Adrenal Vein Sampling Despite the Occurrence of Discordant Lateralisation," *Clinical Endocrinology* 93, no. 4 (2020): 394–403.

55. G. P. Rossi, G. Pitter, P. Bernante, R. Motta, G. Feltrin, and D. Miotto, "Adrenal Vein Sampling for Primary Aldosteronism: The Assessment of Selectivity and Lateralization of Aldosterone Excess Baseline and After Adrenocorticotropic Hormone (ACTH) Stimulation," *Journal of Hypertension* 26, no. 5 (2008): 989–997.

56. W. Liu, J. Zhang, Y. Yang, et al., "Effect of Adrenocorticotropic Hormone Stimulation During Simultaneous Bilateral Adrenal Vein Sampling in Primary Aldosteronism," *Hormone and Metabolic Research* 53, no. 6 (2021): 364–370.

57. H. Kobayashi, Y. Nakamura, M. Abe, et al., "Effect of Cosyntropin During Adrenal Venous Sampling on Subtype of Primary Aldosteronism: Analysis of Surgical Outcome," *European Journal of Endocrinology* 182, no. 3 (2020): 265–273.

58. E. G. Violari, M. Arici, C. K. Singh, et al., "Adrenal Vein Sampling With and Without Cosyntropin Stimulation for Detection of Surgically Remediable Aldosteronism," *Endocrinology, Diabetes & Metabolism* 2, no. 2 (2019): 00066.

59. A. F. Turcu, Y. Tezuka, J. S. Lim, et al., "Multifocal, Asymmetric Bilateral Primary Aldosteronism Cannot be Excluded by Strong Adrenal Vein Sampling Lateralisation: An International Retrospective Cohort Study," *Hypertension* 81, no. 3 (2024): 604–613.

60. S. Yang, Z. Du, X. Zhang, et al., "Corticotropin Stimulation in Adrenal Venous Sampling for Patients With Primary Aldosteronism: The ADOPA Randomized Clinical Trial," *JAMA Network Open* 6, no. 10 (2023): e2338209.

61. C. B. So, A. A. Leung, A. Chin, and G. A. Kline, "Adrenal Venous Sampling in Primary Aldosteronism: Lessons From Over 600 Single-Operator Procedures," *Clinical Radiology* 77, no. 2 (2022): e170–e179.

62. O. Vonend, N. Ockenfels, X. Gao, et al., "Adrenal Venous Sampling: Evaluation of the German Conn's Registry," *Hypertension* 57, no. 5 (2011): 990–995.

63. M. Wolley, M. Thuzar, and M. Stowasser, "Controversies and Advances in Adrenal Venous Sampling in the Diagnostic Workup of Primary Aldosteronism," *Best Practice & Research Clinical Endocrinology & Metabolism* 34, no. 3 (2020): 101400.

64. Y. Zhou, H. Zhang, J. Luo, et al., "Intraprocedural Cortisol Measurement Increases Adrenal Vein Cannulation Success Rate in Primary Aldosteronism: A Systematic Review and Meta-Analysis," *American Journal of Hypertension* 37, no. 2 (2024): 134–142.

65. R. J. Auchus, C. Michaelis, F. H. Wians Jr., et al., "Rapid Cortisol Assays Improve the Success Rate of Adrenal Vein Sampling for Primary Aldosteronism," *Annals of Surgery* 249, no. 2 (2009): 318–321.

66. C. C. Chang, B. C. Lee, Y. C. Chang, V. C. Wu, K. H. Huang, and K. L. Liu, "Comparison of C-Arm Computed Tomography and On-Site Quick Cortisol Assay for Adrenal Venous Sampling: A Retrospective Study of 178 Patients," *European Radiology* 27, no. 12 (2017): 5006–5014.

67. M. M. Umapathysivam, B. Morgan, C. Bischoff, et al., "Intraprocedural Cortisol Testing Improves Adrenal Vein Cannulation Success and Diagnostic Accuracy in Assessment of Primary Aldosteronism, in a Medium Throughput Centre," *Journal of Human Hypertension* 37, no. 9 (2023): 783–787.

68. T. Yoneda, S. Karashima, M. Kometani, et al., "Impact of New Quick Gold Nanoparticle-Based Cortisol Assay During Adrenal Vein Sampling for Primary Aldosteronism," *Journal of Clinical Endocrinology and Metabolism* 101, no. 6 (2016): 2554–2561.

69. M. A. Reardon, J. F. Angle, N. Abi-Jaoudeh, et al., "Intraprocedural Cortisol Levels in the Evaluation of Proper Catheter Placement in Adrenal Venous Sampling," *Journal of Vascular and Interventional Radiology* 22, no. 11 (2011): 1575–1580.

70. T. Yoneda, S. Karashima, M. Kometani, et al., "Impact of New Quick Gold Nanoparticle-Based Cortisol Assay During Adrenal Vein Sampling for Primary Aldosteronism," *Journal of Clinical Endocrinology & Metabolism* 101, no. 6 (2016): 2554–2561.

71. G. Mengozzi, D. Rossato, C. Bertello, et al., "Rapid Cortisol Assay During Adrenal Vein Sampling in Patients With Primary Aldosteronism," *Clinical Chemistry* 53, no. 11 (2007): 1968–1971.

72. M. J. Betz, C. Degenhart, E. Fischer, et al., "Adrenal Vein Sampling Using Rapid Cortisol Assays in Primary Aldosteronism Is Useful in Centers With Low Success Rates," *European Journal of Endocrinology* 165, no. 2 (2011): 301–306.

73. I. W. Møller, K. Dinesen, S. Søndergård, U. Knigge, and H. Kehlet, "Effect of Patient-Controlled Analgesia on Plasma Catecholamine, Cortisol and Glucose Concentrations After Cholecystectomy," *British Journal of Anaesthesia* 61, no. 2 (1988): 160–164.

74. J. M. Shapiro, L. M. Westphal, P. F. White, R. N. Sladen, and M. H. Rosenthal, "Midazolam Infusion for Sedation in the Intensive Care Unit," *Anesthesiology* 64, no. 3 (1986): 394–397.

75. G. Mistraletti, F. Donatelli, and F. Carli, "Metabolic and Endocrine Effects of Sedative Agents," *Current Opinion in Critical Care* 11, no. 4 (2005): 312–317.

76. G. A. Kline, P. Darras, A. A. Leung, B. So, A. Chin, and D. T. Holmes, "Surprisingly Low Aldosterone Levels in Peripheral Veins Following Intravenous Sedation During Adrenal Vein Sampling: Implications for the Concept of Nonsuppressibility in Primary Aldosteronism," *Journal of Hypertension* 37, no. 3 (2019): 596–602.

77. J. Yang, R. Libianto, K. K. Lau, et al., "Impact of Intraprocedural Sedation on Adrenal Vein Sampling Without Corticotropin Stimulation," *Radiology* 304, no. 3 (2022): 716–718.

78. M. Battistel, G. Ceolotto, G. Barbiero, G. Rossitto, and G. P. Rossi, "Adrenal Venous Sampling in Dye-Allergic Primary Aldosteronism Patients: Prevalence, Pitfalls and a Possible Solution," *Journal of Hypertension* 36, no. 9 (2018): 1942–1944.

79. N. Younes, E. Therasse, I. Bourdeau, and A. Lacroix, "Successful Adrenal Vein Sampling Using Dexamethasone Premedication in Patients With Iodine Contrast Media Allergy," *Journal of the Endocrine Society* 6, no. 8 (2022): bvac093.

80. E. C. Lasser, C. C. Berry, L. B. Talner, et al., "Pretreatment With Corticosteroids to Alleviate Reactions to Intravenous Contrast Material," *New England Journal of Medicine* 317, no. 14 (1987): 845–849.

81. M. L. M. Prins, B. E. P. B. Ballieux, O. C. Meijer, A. M. Pereira, and M. F. Nijhoff, "Adrenal Vein Sampling in a Patient With Primary Hyperaldosteronism and Severe Contrast Allergy," *Journal of the Endocrine Society* 5, no. 10 (2021): bvab122.

82. M. Vogeser, J. Kratzsch, Y. Ju Bae, et al., "Multicenter Performance Evaluation of a Second Generation Cortisol Assay," *Clinical Chemistry and Laboratory Medicine (CCLM)* 55, no. 6 (2017): 826–835.

83. H. Li, X. Zhang, S. Shen, et al., "Adrenal Androgen Measurement for Assessing the Selectivity of Adrenal Venous Sampling in Primary Aldosteronism," *Steroids* 134 (2018): 16–21.

84. W. Zhang, K. Zhu, H. Li, et al., "The Value of Adrenal Androgens for Correcting Cortisol Lateralisation in Adrenal Venous Sampling in Patients With Normal Cortisol Secretion," *International Journal of Endocrinology* 2019 (2019): 2860810.

85. G. Ceolotto, G. Antonelli, G. Maiolino, et al., "Androstenedione and 17-α-Hydroxyprogesterone Are Better Indicators of Adrenal Vein Sampling Selectivity Than Cortisol," *Hypertension* 70, no. 2 (2017): 342–346.

86. G. Eisenhofer, T. Dekkers, M. Peitzsch, et al., "Mass Spectrometry-Based Adrenal and Peripheral Venous Steroid Profiling for Subtyping Primary Aldosteronism," *Clinical Chemistry* 62, no. 3 (2016): 514–524.

87. R. W. Carroll, B. Corley, J. Feltham, et al., "The Value of Plasma Metanephrine Measurements During Adrenal Vein Sampling," *Endocrine Connections* 13, no. 2 (2024): e230300.

88. H. Sasamura, S. Hashimoto, S. Kuribayashi, et al., "Use of Gadolinium Contrast Adrenal Venography for the Assessment of Primary Aldosteronism in a Patient With Iodine Allergy," *Endocrine Journal* 51, no. 5 (2004): 487–492.

89. Y. Yoshida, S. Nagai, K. Shibuta, et al., "Adrenal Vein Sampling With Gadolinium Contrast Medium in a Patient With Florid Primary Aldosteronism and Iodine Allergy," *Journal of the Endocrine Society* 6, no. 3 (2022): bvac007.

90. P. Marckmann, L. Skov, K. Rossen, et al., "Nephrogenic Systemic Fibrosis: Suspected Causative Role of Gadodiamide Used for Contrast-Enhanced Magnetic Resonance Imaging," *Journal of the American Society of Nephrology* 17, no. 9 (2006): 2359–2362.

91. P. A. McCullough, J. P. Choi, G. A. Feghali, et al., "Contrast-Induced Acute Kidney Injury," *Journal of the American College of Cardiology* 68, no. 13 (2016): 1465–1473.

92. The Royal Australian and New Zealand College of Radiologists, *Iodinated Contrast Media Guideline* (Sydney: RANZCR, 2018).

93. M. Burshteyn, D. L. Cohen, D. L. Fraker, and S. O. Trerotola, "Adrenal Venous Sampling for Primary Hyperaldosteronism in Patients With Concurrent Chronic Kidney Disease," *Journal of Vascular and Interventional Radiology* 24, no. 5 (2013): 726–733.

94. Z. Liu, M. He, X. Song, et al., "Computed Tomography Image Fusion, Coaxial Guidewire Technique, Fast Intraprocedural Cortisol Testing Technique Improves Success Rate and Decreases Radiation Exposure, Procedure Time, and Contrast Use for Adrenal Vein Sampling," *Journal of Hypertension* 39, no. 9 (2021): 1918–1925.

95. D. M. DePietro and S. O. Trerotola, "Techniques in Adrenal Vein Sampling: Multipurpose Catheter Shape Facilitates Sampling of Cranially Oriented Right Adrenal Veins," *Diagnostic and Interventional Radiology* 28, no. 1 (2022): 79–82.

96. M. Araujo-Castro, M. Paja Fano, M. González Boillos, et al., "Adrenal Venous Sampling in Primary Aldosteronism: Experience of a Spanish Multicentric Study (Results From the SPAIN-ALDO Register)," *Endocrine* 78, no. 2 (2022): 363–372.

97. L. S. Becker, M. H. Hinrichs, T. Werncke, et al., "Adrenal Venous Sampling in Primary Hyperaldosteronism: Correlation of Hormone Indices and Collimated C-Arm CT Findings," *Abdominal Radiology* 46, no. 7 (2021): 3471–3481.

98. T. Dekkers, A. Prejbisz, L. J. S. Kool, et al., "Adrenal Vein Sampling Versus CT Scan to Determine Treatment in Primary Aldosteronism: An Outcome-Based Randomised Diagnostic Trial," *Lancet Diabetes & Endocrinology* 4, no. 9 (2016): 739–746.

99. F. Hannah-Shmouni, A. Demidowich, B. R. Alves, et al., "Management of Primary Aldosteronism in Patients With Adrenal Hemorrhage Following Adrenal Vein Sampling: A Brief Review With Illustrative Cases," *Journal of Clinical Hypertension* 19, no. 12 (2017): 1372–1376.

100. J. Hu, J. Chen, Q. Cheng, et al., "Comparison of Bolus and Continuous Infusion of Adrenocorticotropic Hormone During Adrenal Vein Sampling," *Frontiers in Endocrinology* 12 (2021): 784706.

101. H. Jakobsson, K. Farmaki, A. Sakinis, O. Ehn, G. Johannsson, and O. Ragnarsson, "Adrenal Venous Sampling: The Learning Curve of a Single Interventionalist With 282 Consecutive Procedures," *Diagnostic and Interventional Radiology* 24, no. 2 (2018): 89–93.

102. T. Kocjan, M. Jensterle, G. Vidmar, R. Vrckovnik, P. Berden, and M. Stankovic, "Adrenal Vein Sampling for Primary Aldosteronism: A 15-Year National Referral Center Experience," *Radiology and Oncology* 54, no. 4 (2020): 409–418.

103. S. Monticone, F. Satoh, A. S. Dietz, et al., "Clinical Management and Outcomes of Adrenal Hemorrhage Following Adrenal Vein Sampling in Primary Aldosteronism," *Hypertension* 67, no. 1 (2016): 146–152.

104. S. Morita, H. Yamazaki, Y. Sonoyama, Y. Nishina, A. Ichihara, and S. Sakai, "Successful Adrenal Venous Sampling by Non-Experts With Reference to CT Images," *CardioVascular and Interventional Radiology* 39, no. 7 (2016): 1001–1006.

105. M. M. Page, M. Taranto, D. Ramsay, et al., "Improved Technical Success and Radiation Safety of Adrenal Vein Sampling Using Rapid, Semi-Quantitative Point-of-Care Cortisol Measurement," *Annals of Clinical Biochemistry: International Journal of Laboratory Medicine* 55, no. 5 (2018): 588–592.

106. G. P. Rossi, A. Sacchetto, M. Chiesura-Corona, et al., "Identification of the Etiology of Primary Aldosteronism With Adrenal Vein Sampling in Patients With Equivocal Computed Tomography and Magnetic Resonance Findings: Results in 104 Consecutive Cases," *Journal of Clinical Endocrinology & Metabolism* 86, no. 3 (2001): 1083–1090.

107. M. H. Senussi, N. H. Senussi, A. Alwakkaf, and S. G. Kwatra, "Adrenal Haematoma as a Complication of Adrenal Vein Sampling,"

BMJ Case Reports 2013 (2013): bcr2012008539, https://doi.org/10.1136/bcr-2012-008539.

108. J. J. Siracuse, H. L. Gill, I. Epelboym, et al., "The Vascular Surgeon's Experience With Adrenal Venous Sampling for the Diagnosis of Primary Hyperaldosteronism," *Annals of Vascular Surgery* 28, no. 5 (2014): 1266–1270.

109. S. O. Trerotola, M. Asmar, Y. Yan, D. L. Fraker, and D. L. Cohen, "Failure Mode Analysis in Adrenal Vein Sampling: A Single-Center Experience," *Journal of Vascular and Interventional Radiology* 25, no. 10 (2014): 1611–1619.

110. J. Wan, F. Ran, S. Xia, et al., "Feasibility and Effectiveness of a Single-Catheter Approach for Adrenal Vein Sampling in Patients With Primary Aldosteronism," *BMC Endocrine Disorders* 21, no. 1 (2021): 22.

111. T. S. Wang, G. Kline, T. W. Yen, et al., "A Multi-Institutional Comparison of Adrenal Venous Sampling in Patients With Primary Aldosteronism: Caution Advised If Successful Bilateral Adrenal Vein Sampling Is Not Achieved," *World Journal of Surgery* 42, no. 2 (2018): 466–472.

112. J. M. Luther and A. F. Turcu, "Unilaterally Successful Adrenal Vein Sampling: Use or Repeat?," *Hypertension* 80, no. 10 (2023): 2014–2016.

113. J. D. Pasternak, I. Epelboym, N. Seiser, et al., "Diagnostic Utility of Data From Adrenal Venous Sampling for Primary Aldosteronism Despite Failed Cannulation of the Right Adrenal Vein," *Surgery* 159, no. 1 (2016): 267–274.

114. V. Strajina, Z. Al-Hilli, J. C. Andrews, et al., "Primary Aldosteronism: Making Sense of Partial Data Sets From Failed Adrenal Venous Sampling-Suppression of Adrenal Aldosterone Production Can be Used in Clinical Decision Making," *Surgery* 163, no. 4 (2018): 801–806.

115. K. J. O'Malley, M. W. Alnablsi, Y. Xi, et al., "Diagnostic Performance of the Adrenal Vein to Inferior Vena Cava Aldosterone Ratio in Classifying the Subtype of Primary Aldosteronism," *Hypertension Research* 46, no. 11 (2023): 2535–2542.

116. G. P. Rossi, D. Bagordo, L. Amar, et al., "Unilaterally Selective Adrenal Vein Sampling for Identification of Surgically Curable Primary Aldosteronism," *Hypertension* 80, no. 10 (2023): 2003–2013.

117. X. Zhang, X. Shu, F. Wu, et al., "Treatment Decision Based on Unilateral Index From Nonadrenocorticotropic Hormone-Stimulated and Adrenocorticotropic Hormone-Stimulated Adrenal Vein Sampling in Primary Aldosteronism," *Journal of Hypertension* 42, no. 3 (2024): 450–459.

118. E. Ng, S. M. Gwini, W. Zheng, P. J. Fuller, and J. Yang, "Predicting Bilateral Subtypes of Primary Aldosteronism Without Adrenal Vein Sampling: A Systematic Review and Meta-Analysis," *Journal of Clinical Endocrinology and Metabolism* 109, no. 2 (2024): e837–e855.

119. Y. Zheng, T. Long, N. Peng, et al., "The Value of Targeting CXCR4 With 68Ga-Pentixafor PET/CT for Subtyping Primary Aldosteronism," *Journal of Clinical Endocrinology and Metabolism* 109, no. 1 (2023): 171–182.

120. X. Wu, R. Senanayake, E. Goodchild, et al., "[11C]Metomidate PET-CT Versus Adrenal Vein Sampling for Diagnosing Surgically Curable Primary Aldosteronism: A Prospective, Within-Patient Trial," *Nature Medicine* 29, no. 1 (2023): 190–202.

121. G. Constantinescu, M. Schulze, M. Peitzsch, et al., "Integration of Artificial Intelligence and Plasma Steroidomics With Laboratory Information Management Systems: Application to Primary Aldosteronism," *Clinical Chemistry and Laboratory Medicine (CCLM)* 60, no. 12 (2022): 1929–1937.

122. B. A. Sacks, "Commentary on Apparent Bilateral Adrenal Suppression," *Journal of Vascular and Interventional Radiology* 32, no. 5 (2021): 666–667.

123. T. H. Puar, C. M. Khoo, C. J. Tan, et al., "11C-Metomidate PET-CT Versus Adrenal Vein Sampling to Subtype Primary Aldosteronism: A Prospective Clinical Trial," *Journal of Hypertension* 40, no. 6 (2022): 1179–1188.

124. M. Wolley, R. D. Gordon, E. Pimenta, et al., "Repeating Adrenal Vein Sampling When Neither Aldosterone/Cortisol Ratio Exceeds Peripheral Yields a High Incidence of Aldosterone-Producing Adenoma," *Journal of Hypertension* 31, no. 10 (2013): 2005–2009.

125. Y. Shibayama, N. Wada, H. Umakoshi, et al., "Bilateral Aldosterone Suppression and Its Resolution in Adrenal Vein Sampling of Patients With Primary Aldosteronism: Analysis of Data From the WAVES-J Study," *Clinical Endocrinology* 85, no. 5 (2016): 696–702.

126. Y. Shibayama, N. Wada, M. Naruse, et al., "The Occurrence of Apparent Bilateral Aldosterone Suppression in Adrenal Vein Sampling for Primary Aldosteronism," *Journal of the Endocrine Society* 2, no. 5 (2018): 398–407.

127. D. M. DePietro, D. L. Fraker, H. Wachtel, D. L. Cohen, and S. O. Trerotola, "Double-Down" Adrenal Vein Sampling Results in Patients With Apparent Bilateral Aldosterone Suppression: Utility of Repeat Sampling Including Super-Selective Sampling," *Journal of Vascular and Interventional Radiology* 32, no. 5 (2021): 656–665.

128. S. Y. T. Tan, K. S. Ng, C. Tan, M. Chuah, M. Zhang, and T. H. Puar, "Bilateral Aldosterone Suppression in Patients With Right Unilateral Primary Aldosteronism and Review of the Literature," *Journal of the Endocrine Society* 4, no. 4 (2020): bvaa033.

129. A. Harvey, J. L. Pasieka, G. Kline, and B. So, "Modification of the Protocol for Selective Adrenal Venous Sampling Results in Both a Significant Increase in the Accuracy and Necessity of the Procedure in the Management of Patients With Primary Hyperaldosteronism," *Surgery* 152, no. 4 (2012): 643–651; discussion 9-51.

130. G. A. Kline, B. So, D. J. T. Campbell, et al., "Apparent Failed and Discordant Adrenal Vein Sampling: A Potential Confounding Role of Cortisol Cosecretion?," *Clinical Endocrinology* 96, no. 2 (2022): 123–131.

131. J.-P. Mailhot, M. Traistaru, G. Soulez, et al., "Adrenal Vein Sampling in Primary Aldosteronism: Sensitivity and Specificity of Basal Adrenal Vein to Peripheral Vein Cortisol and Aldosterone Ratios to Confirm Catheterization of the Adrenal Vein," *Radiology* 277, no. 3 (2015): 887–894.

132. W. F. Young, A. W. Stanson, G. B. Thompson, C. S. Grant, D. R. Farley, and J. A. van Heerden, "Role for Adrenal Venous Sampling in Primary Aldosteronism," *Surgery* 136, no. 6 (2004): 1227–1235.

133. S. Monticone, A. Viola, D. Rossato, et al., "Adrenal Vein Sampling in Primary Aldosteronism: Towards a Standardised Protocol," *Lancet Diabetes & Endocrinology* 3, no. 4 (2015): 296–303.

134. N. Younes, S. Larose, I. Bourdeau, E. Therasse, and A. Lacroix, "Role of Adrenal Vein Sampling in Guiding Surgical Decision in Primary Aldosteronism," *Experimental and Clinical Endocrinology & Diabetes* 131, no. 7–08 (2023): 418–434.

135. P. Mulatero, S. Monticone, J. Deinum, et al., "Genetics, Prevalence, Screening and Confirmation of Primary Aldosteronism: A Position Statement and Consensus of the Working Group on Endocrine Hypertension of the European Society of Hypertension," *Journal of Hypertension* 38, no. 10 (2020): 1919–1928.

136. T. Nishikawa, M. Omura, F. Satoh, et al., "Guidelines for the Diagnosis and Treatment of Primary Aldosteronism: The Japan Endocrine Society 2009," *Endocrine Journal* 58, no. 9 (2011): 711–721.

137. W. F. Young and A. W. Stanson, "What Are the Keys to Successful Adrenal Venous Sampling (AVS) in Patients With Primary Aldosteronism?," *Clinical Endocrinology* 70, no. 1 (2009): 14–17.

138. G. Ceolotto, G. Antonelli, B. Caroccia, et al., "Comparison of Cortisol, Androstenedione and Metanephrines to Assess Selectivity and Lateralisation of Adrenal Vein Sampling in Primary Aldosteronism," *Journal of Clinical Medicine* 10, no. 20 (2021): 4755.

139. H. Umakoshi, M. Naruse, N. Wada, et al., "Adrenal Venous Sampling in Patients With Positive Screening But Negative Confirmatory Testing for Primary Aldosteronism," *Hypertension* 67, no. 5 (2016): 1014–1019.

140. M. J. Wolley, R. D. Gordon, A. Ahmed, and M. Stowasser, "Does Contralateral Suppression at Adrenal Venous Sampling Predict Outcome Following Unilateral Adrenalectomy for Primary Aldosteronism? A Retrospective Study," *Journal of Clinical Endocrinology & Metabolism* 100, no. 4 (2015): 1477–1484.

141. H. Umakoshi, K. Tanase-Nakao, N. Wada, et al., "Importance of Contralateral Aldosterone Suppression During Adrenal Vein Sampling in the Subtype Evaluation of Primary Aldosteronism," *Clinical Endocrinology* 83, no. 4 (2015): 462–467.

142. J. Lee, B. Kang, J. Ha, et al., "Clinical Outcomes of Primary Aldosteronism Based on Lateralization Index and Contralateral Suppression Index After Adrenal Venous Sampling in Real-World Practice: A Retrospective Cohort Study," *BMC Endocrine Disorders* 20, no. 1 (2020): 114.

143. G. P. Rossi, F. Crimì, G. Rossitto, et al., "Identification of Surgically Curable Primary Aldosteronism by Imaging in a Large, Multiethnic International Study," *Journal of Clinical Endocrinology & Metabolism* 106, no. 11 (2021): e4340–e4349.

144. M. Kishino, T. Yoshimoto, M. Nakadate, et al., "Optimization of Left Adrenal Vein Sampling in Primary Aldosteronism: Coping With Asymmetrical Cortisol Secretion," *Endocrine Journal* 64, no. 3 (2017): 347–355.

145. S. M. O'Toole, W. C. C. Sze, T. T. Chung, et al., "Low-Grade Cortisol Cosecretion Has Limited Impact on ACTH-Stimulated AVS Parameters in Primary Aldosteronism," *Journal of Clinical Endocrinology & Metabolism* 105, no. 10 (2020): e3776–e3784.

146. P. S. Bhatt, A. H. Sam, K. M. Meeran, and V. Salem, "The Relevance of Cortisol Co-Secretion From Aldosterone-Producing Adenomas," *Hormones* 18, no. 3 (2019): 307–313.

147. F. Fallo, C. Bertello, D. Tizzani, et al., "Concurrent Primary Aldosteronism and Subclinical Cortisol Hypersecretion: a Prospective Study," *Journal of Hypertension* 29, no. 9 (2011): 1773–1777.

148. K. Fujimoto, S. Honjo, H. Tatsuoka, et al., "Primary Aldosteronism Associated With Subclinical Cushing Syndrome," *Journal of endocrinological investigation* 36, no. 8 (2013): 564–567.

149. F. Buffolo, J. Pieroni, F. Ponzetto, et al., "Prevalence of Cortisol Cosecretion in Patients With Primary Aldosteronism: Role of Metanephrine in Adrenal Vein Sampling," *Journal of Clinical Endocrinology & Metabolism* 108, no. 9 (2023): e720–e725.

150. R. Goupil, M. Wolley, A. H. Ahmed, R. D. Gordon, and M. Stowasser, "Does Concomitant Autonomous Adrenal Cortisol Overproduction Have the Potential to Confound the Interpretation of Adrenal Venous Sampling in Primary Aldosteronism?," *Clinical Endocrinology* 83, no. 4 (2015): 456–461.

151. D. A. Heinrich, M. Quinkler, C. Adolf, et al., "Influence of Cortisol Cosecretion on Non-ACTH-Stimulated Adrenal Venous Sampling in Primary Aldosteronism: A Retrospective Cohort Study," *European Journal of Endocrinology* 187, no. 5 (2022): 637–650.

152. T. Dekkers, J. Deinum, L. J. Schultzekool, et al., "Plasma Metanephrine for Assessing the Selectivity of Adrenal Venous Sampling," *Hypertension* 62, no. 6 (2013): 1152–1157.

153. W. Liu, J. Zhang, Y. Yang, et al., "Application of Metanephrine and Normetanephrine in Evaluating the Selectivity of Adrenal Vein Sampling," *Hormone and Metabolic Research* 54, no. 3 (2022): 162–167.

154. F. Christou, E. Pivin, A. Denys, et al., "Accurate Location of Catheter Tip With the Free-to-Total Metanephrine Ratio During Adrenal Vein Sampling," *Frontiers in Endocrinology* 13 (2022): 842968.

155. G. Å. Ueland, P. Methlie, D. E. Jøssang, et al., "Adrenal Venous Sampling for Assessment of Autonomous Cortisol Secretion," *Journal of Clinical Endocrinology & Metabolism* 103, no. 12 (2018): 4553–4560.