JACC
VOL. 86, NO. 25, 2025
© 2025 BY THE AMERICAN COLLEGE OF CARDIOLOGY FOUNDATION
PUBLISHED BY ELSEVIER

CONCISE CLINICAL GUIDANCE

2025 Concise Clinical Guidance: An ACC Expert Consensus Statement on the Diagnosis and Management of Pericarditis

A Report of the American College of Cardiology Solution Set Oversight Committee

Writing Committee Members

Tom Kai Ming Wang, MBChB, MD, FACC, *Chair*
Allan L. Klein, MD, CM, FACC, *Vice Chair*

Paul C. Cremer, MD, FACC
Massimo Imazio, MD
Sarah Kohnstamm, MD, FACC
Sushil Allen Luis, MBBS, FACC
Vartan Mardigyan, MD
Monica Mukherjee, MD, MPH, FACC
Karen Ordovas, MD, MAS
Sneha Vakamudi, MD, FACC
George F. Wohlford, PharmD

Solution Set Oversight Committee

Gurusher S. Panjrath, MBBS, FACC, *Chair*
Nicole M. Bhave, MD, FACC, *Immediate Past Chair**

Niti R. Aggarwal, MD, FACC*
Katie Bates, ARNP, DNP
Eugene Chung, MD, MPH, FACC
David M. Dudzinski, MD, JD, FACC
John P. Erwin III, MD, FACC*
Martha Gulati, MD, MS, FACC
Robert Hendel, MD, MACC
Dharam J. Kumbhani, MD, SM, FACC*
Chayakrit Krittanawong, MD, FACC
Barbara Wiggins, PharmD, FACC
Megan Coylewright, MD, MPH, FACC—*Ex Officio*

*Former SSOC members who provided oversight during the development of this document.

TABLE OF CONTENTS

PREFACE 2692
1. INTRODUCTION 2693
2. ASSUMPTIONS AND DEFINITIONS 2693
2.1. General Clinical Assumptions 2693

This document was approved by the American College of Cardiology Clinical Policy Approval Committee in May 2025.

The American College of Cardiology requests that this document be cited as follows: Wang TKM, Klein AL, Cremer PC, Imazio M, Kohnstamm S, Luis SA, Mardigyan V, Mukherjee M, Ordovas K, Vakamudi S, Wohlford GF. 2025 concise clinical guidance: an ACC expert consensus statement on the diagnosis and management of pericarditis: a report of the American College of Cardiology Solution Set Oversight Committee. *J Am Coll Cardiol*. 2025;86:(25);2691-2719.

Copies: This document is available on the website of the American College of Cardiology (www.acc.org). For copies of this document, please contact the Elsevier Inc. Reprint Department, via fax (212) 633-3820 or e-mail (reprints@elsevier.com).

Permissions: Multiple copies, modification, alteration, enhancement, and/or distribution of this document are not permitted without the express permission of the American College of Cardiology. Requests may be completed online via the Elsevier site (https://www.elsevier.com/about/policies/copyright/permissions).

ISSN 0735-1097/$36.00
https://doi.org/10.1016/j.jacc.2025.05.023

JACC VOL. 86, NO. 25, 2025
DECEMBER 23/30, 2025:2691-2719

2.2. Definitions . . . 2693
2.3. Abbreviations . . . 2693
3. SUMMARY GRAPHIC . . . 2694
Figure 1. Novel Clinical and Advanced Multimodality Imaging Evaluation Guiding Therapeutics for Pericarditis . . . 2694
4. DESCRIPTION, RATIONALE, AND IMPLICATIONS . . . 2694
4.1. General Perspectives for Pericardial Diseases . . . 2694
4.1.1. Anatomy and Physiology . . . 2694
Figure 2. Anatomy of the Pericardium . . . 2695
4.1.2. Epidemiology and Etiologies . . . 2696
4.1.3. The Role of Inflammation in Pericardial Disease . . . 2697
Figure 3. Pathophysiology of Pericardial Inflammation . . . 2697
4.1.4. Multimodality Imaging and Pericardial Disease . . . 2697
4.1.5. Pericardial Diseases Center of Excellence . . . 2698
Figure 4. Framework and Components of a Pericardial Diseases Center . . . 2699
4.2. Pericarditis . . . 2699
4.2.1. Novel Clinical Diagnostic Criteria and Perspectives . . . 2699
Figure 5. Novel Diagnostic Criteria and Classification by Duration for Pericarditis . . . 2700
4.2.2. Evaluation and Multimodality Imaging . . . 2701
Figure 6. Hallmarks of Pericarditis on Cardiac Magnetic Resonance . . . 2702
Figure 7. Proposed Pericardial Late Gadolinium Enhancement Grading Criteria by Cardiac Magnetic Resonance . . . 2703
4.2.3. Management . . . 2703
Figure 8. Proposed Schematic Algorithm for Treatment of Recurrent Pericarditis . . . 2705
4.3. Complications of Pericarditis . . . 2706
4.3.1. Pericardial Effusion . . . 2706
Figure 9. Pericardial Effusion Sizing Evaluation by Echocardiography . . . 2708
4.3.2. Cardiac Tamponade and Pericardiocentesis . . . 2706
Figure 10. Echocardiography Signs of Cardiac Tamponade . . . 2709
4.3.3. Constrictive Pericarditis . . . 2707
Figure 11. Echocardiography Features of Constrictive Pericarditis . . . 2711
Figure 12. Echocardiography Parameters and Diagnostic Algorithm and Validation for Constrictive Pericarditis . . . 2712
Figure 13. Invasive Diagnosis of Constrictive Pathophysiology . . . 2713
Figure 14. Treatment Approach for Constrictive Pericarditis . . . 2715
4.3.4. Pericarditis in Oncologic Patients . . . 2710
5. CONCLUSIONS . . . 2715
REFERENCES . . . 2716
APPENDIX 1
Author Relationships with Industry and Other Entities (Relevant) . . . 2718
APPENDIX 2
Peer Reviewer Relationships with Industry and Other Entities (Comprehensive) . . . 2719

PREFACE

The American College of Cardiology (ACC) has a long history of developing documents (eg, decision pathways, appropriate use criteria) to provide clinicians with guidance on both clinical and nonclinical topics relevant to cardiovascular care. In most circumstances, these documents have been created to complement clinical practice guidelines and to inform clinicians about areas where evidence is new and evolving or where sufficient data is more limited. Despite this, numerous gaps persist, highlighting the need for more streamlined and efficient processes to implement best practices in patient care.

Central to the ACC's strategic plan is the generation of actionable knowledge—a concept that places emphasis on making clinical information easier to consume, share, integrate, and update. To this end, the ACC has shifted from developing isolated documents to creating integrated "solution sets." These are groups of closely related activities, policy, mobile applications, decision-support tools, and other resources necessary to transform care and/or improve heart health. Solution sets address key questions facing care teams and offer practical guidance to be applied at the point of care. They use both established and emerging methods to disseminate information for cardiovascular conditions and their related management. The success of solution sets rests firmly on their ability to have a measurable impact on the delivery of care. Because solution sets reflect current evidence and ongoing gaps in care, the associated tools will be refined over time to match changing evidence and member needs.

Concise Clinical Guidance (CCG) documents are a key component of solution sets. Highly focused and limited in scope, CCGs provide recommendations where none currently exist and/or outline actions required for evidence to be implemented in practice for specific patient populations. CCGs aim to illustrate clinical decision-making processes using tools (ie, figures, tables, and checklists) and are limited in scope focusing on patient populations that share certain characteristics, such as

conditions, subtypes, or lines of therapy. In some cases, covered topics will be addressed in subsequent expert consensus decision pathways, appropriate use criteria, clinical practice guidelines, and other related ACC clinical policy as the evidence base evolves. In other cases, these will serve as stand-alone policy and represent best standards.

Gurusher Panjrath, MBBS, FACC
Chair, ACC Solution Set
Oversight Committee

1. INTRODUCTION

Pericardial diseases represent a heterogenous spectrum of disorders, including acute and chronic inflammation of the pericardium (pericarditis), pericardial effusion, constrictive pericarditis, and pericardial masses with malignant infiltration (**Figure 1**).[1] Clinical management of pericarditis may be challenging, and consensus guidelines focusing on diagnosis, risk stratification, and treatment are vital for standardizing care, reducing variability in clinical practice, and improving patient outcomes. This CCG addresses diagnostic and therapeutic advances in acute and recurrent pericarditis and their complications, employing a multimodality imaging-guided therapeutic approach. This document is targeted at assisting cardiologists, emergency and internal medicine physicians, primary care physicians, rheumatologists, and other physicians and cardiovascular care team members who manage these complex patients in the real world.

In accordance with the ACC's Relationships With Industry policy, relevant disclosures for the writing committee and comprehensive disclosures for external peer reviewers can be found in Appendixes 1 and 2.

To ensure complete transparency, a comprehensive Relationships With Industry table for the writing committee, including relationships not pertinent to this document, has been created. It is available in the Supplemental Appendix.

2. ASSUMPTIONS AND DEFINITIONS

2.1. General Clinical Assumptions

1. This CCG presumes the physician will collaborate with appropriate specialists, such as a cardiologist, pharmacist, and/or other relevant specialists (eg, rheumatologist, cardiac surgeon, radiologist), and/or pericardial center of excellence program members, including advanced practice providers, to guide clinical management.
2. In all cases, clinical management should be guided by evidence-based clinical judgment, with shared decision-making that incorporates patient preferences and values.
3. This CCG is based on the latest pericardial evidence and literature available. At any point in time, physicians should be aware that this CCG's recommendations may be superseded by new data.

The writing committee endorses the recommendations of the document "Pericardial Diseases: International Position Statement on New Concepts and Advances in Multimodality Cardiac Imaging" recently published in *JACC: Cardiovascular Imaging*, endorsed by the ACC Imaging Council and Society of Cardiovascular Magnetic Resonance Imaging.[1]

2.2. Definitions

***Pericarditis*:** Inflammation of the pericardium leading to characteristic pleuritic chest pain, which can be accompanied by pericardial rub on auscultation, typical electrocardiogram changes, new or worsening pericardial effusion, and elevated inflammatory markers on laboratory tests. See document for novel diagnostic criteria.

***Pericardial effusion*:** Fluid accumulation in the pericardial space visible on cardiac imaging such as echocardiography.

***Cardiac tamponade*:** Compression of the heart by abnormal fluid accumulation in the pericardial space, leading to impaired cardiac output and hemodynamic compromise.

***Constrictive pericarditis*:** Loss of elasticity and often abnormal thickening of the pericardium, impairing diastolic filling and leading to heart failure syndrome. This can be transient/subacute (predominantly inflammatory and reversible) or advanced/chronic (often calcified and irreversible) constrictive pericarditis.

Effusive constrictive pericarditis: Presence of persistent constrictive physiology even after drainage of pericardial effusion.

2.3. Abbreviations

ACC = American College of Cardiology
CCG = Concise Clinical Guidance
CCT = cardiac computed tomography
CMR = cardiac magnetic resonance
CRP = C-reactive protein
IL-1 = interleukin-1
LGE = late gadolinium enhancement
NSAID = non-steroidal anti-inflammatory drug
PDC = pericardial diseases center
TTE = transthoracic echocardiography

JACC VOL. 86, NO. 25, 2025
DECEMBER 23/30, 2025:2691-2719

3. SUMMARY GRAPHIC

FIGURE 1 Novel Clinical and Advanced Multimodality Imaging Evaluation Guiding Therapeutics for Pericarditis

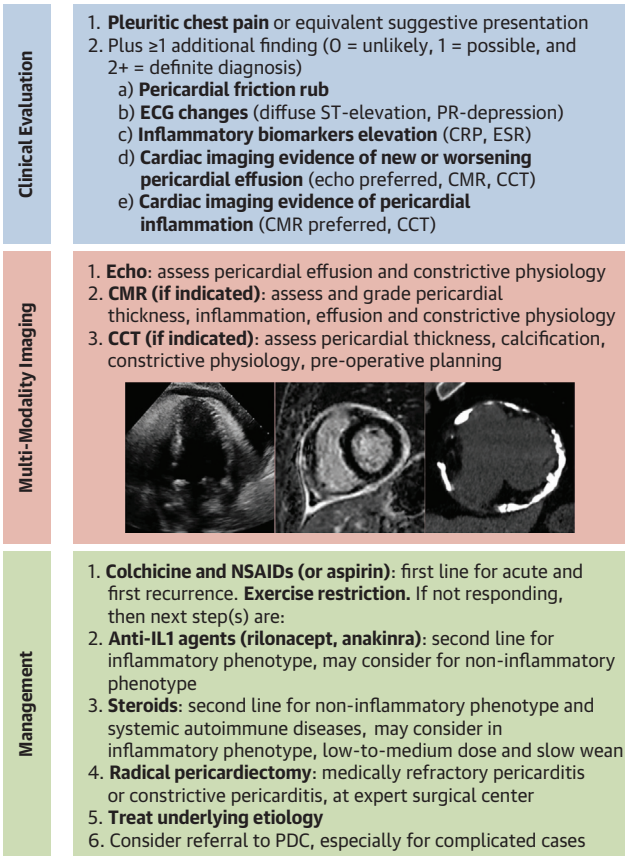

Figure panel illustrates a pericarditis case: left image—small pericardial effusion on echocardiography; middle image—pericardial late gadolinium enhancement that indicates inflammation on CMR; right image—pericardial calcifications consistent with constrictive pericarditis on CCT. CMR = cardiac magnetic resonance; CRP = C-reactive protein; CCT = cardiac computed tomography; ECG = electrocardiogram; echo = echocardiography; ESR = erythrocyte sedimentation rate; IL = interleukin; NSAID = nonsteroidal anti-inflammatory drug.

4. DESCRIPTION, RATIONALE, AND IMPLICATIONS

4.1. General Perspectives for Pericardial Diseases

4.1.1. Anatomy and Physiology

The pericardial anatomy, through the interplay of its fibrous parietal layer and elastic visceral layer, have pivotal roles in modulating cardiac pressure-volume dynamics, ensuring optimal chamber restraint and preventing overexpansion during cardiac cycles.[1-3] The parietal pericardium is an outer fibrous sac lined by a single layer of mesothelial cells, which envelops the proximal great arteries, pulmonary veins, and venae cavae to form pericardial sinuses and recesses. The visceral pericardium is a serous membrane that directly covers and protects the cardiac surface. Cardiac motion is enhanced by 20 to 50 mL of serum ultrafiltrate within the pericardium, which is drained by lymphatic vessels on the epicardial and parietal surfaces into mediastinal, peribronchial, and tracheobronchial lymph nodes (Figure 2).

FIGURE 2 Anatomy of the Pericardium

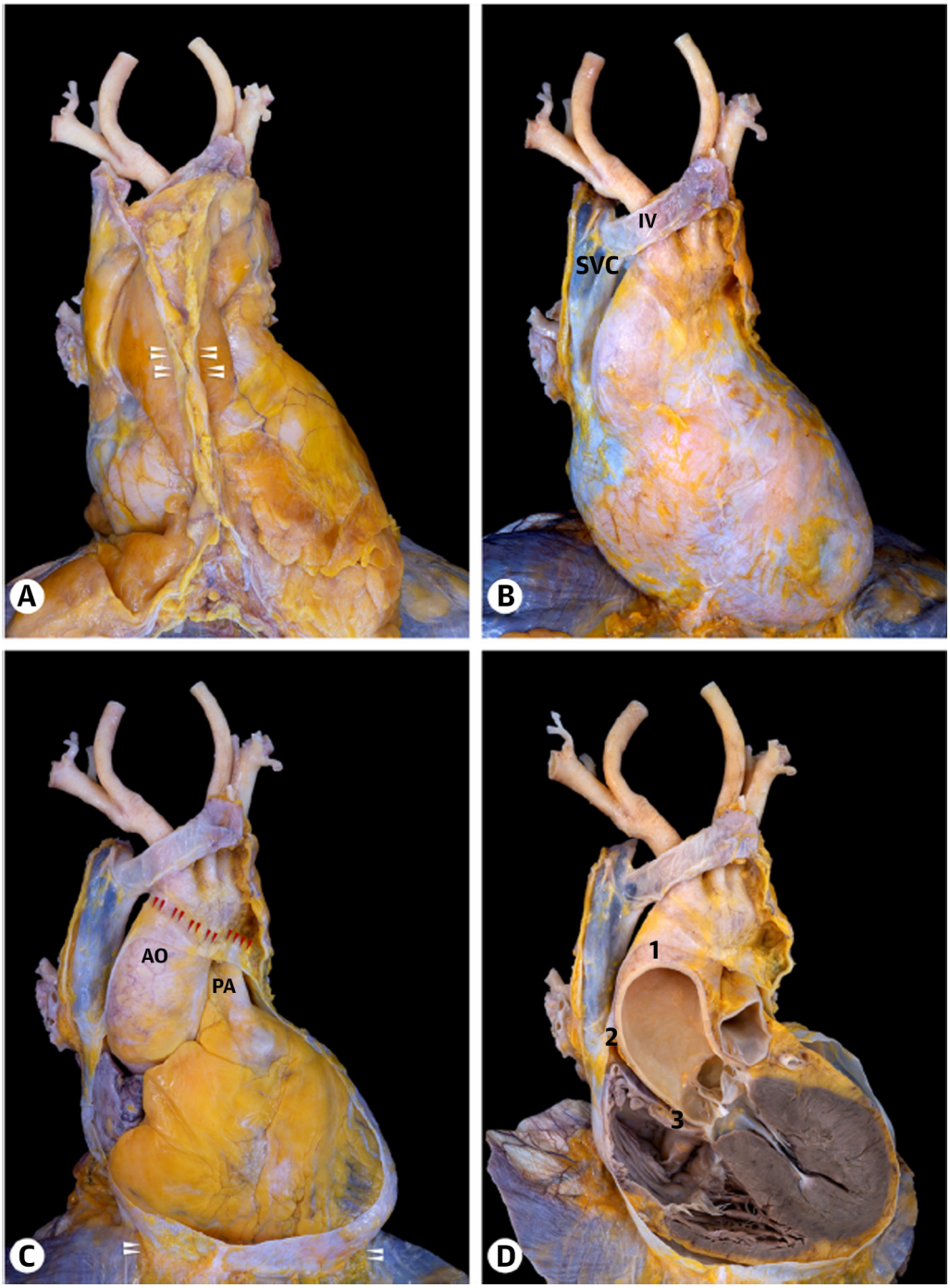

(A) Pericardium with mediastinal pleura and epipericardial adipose tissue. Arrowheads indicate the sternopericardial ligaments. (B) Fibrous pericardium after removal of adipose tissue. (C) The fibrous pericardium is continuous with the adventitia of the aorta (Ao) and pulmonary artery (PA) superiorly (red arrowheads) and is anchored to the central tendon of the diaphragm inferiorly (white arrowheads). (D) Anterior (1), superior (2), and inferior (3) aortic recesses of the transverse sinus. Adapted with permission from Klein et al.[1] IV = innominate vein; SVC = superior vena cava.

JACC VOL. 86, NO. 25, 2025
DECEMBER 23/30, 2025:2691-2719

TABLE 1 Pericardial Functions

Category	Specific Functions
Mechanical	■ Limits short-term cardiac distention ■ Facilitates cardiac chamber coupling and interaction ■ Maintains pressure-volume relations of cardiac chambers and their output
Membranous/ serosal	■ Lubricates, reduces friction ■ Equalizes gravitational, hydrostatic, and inertial forces ■ Mechanical barrier to infection
Metabolic	■ Immunologic ■ Vasomotor ■ Fibrinolytic ■ Modulates sympathetic neurotransmission and contractility
Ligamentous	■ Limits displacement of the heart ■ Neutralizes the effects of respiration and change of body position ■ Contributes to apparent compliance of the pericardium

Adapted with permission from Klein et al.[1]

The pericardium performs a multifaceted role in cardiac function, encompassing mechanical, membranous, metabolic, and ligamentous features (Table 1).[1] The pericardium mechanically limits short-term cardiac distention to optimize pressure-volume relationships of cardiac chambers and their output, mitigates the effects of respiration and positional changes, and enhances overall pericardial compliance.[4] The pressure-volume relationship of the pericardium is dynamic with small increases in cardiac volume, resulting in minimal changes to intracavitary pressure. As volume increases above the upper limit of normal cardiac filling, there is a sharp transition where further volume increases result in disproportionate increases in pressure. The abrupt change to the pressure-volume relationship highlights the limited reserve capacity and decreased compliance of the pericardial sac, restraining further cardiac expansion and resulting in ventricular interdependence. Despite the understood function of the pericardium, absence of the pericardium does not alter cardiac function, as seen in patients post-pericardiectomy or with congenital absence.

4.1.2. Epidemiology and Etiologies

Pericarditis accounts for 0.1% of hospital admissions and 5% of emergency department evaluations for chest pain.[1,5,6] Approximately 0.2% of all cardiovascular admissions are attributable to acute pericarditis, occurring more commonly in men aged 16 to 65 years, and declining by an estimated 51% per 10-year increase in age, although recurrent pericarditis is more common in women. Pericarditis is classified based on etiology, clinical course, morphology, and associated impact of fluid characteristics, size, and hemodynamics.[1,7] Idiopathic and viral etiologies are the most common cause of pericarditis in high-income countries, whereas tuberculosis, often HIV-associated, is the most common cause in low-income countries. Table 2 summarizes the various etiologies of pericardial diseases.

TABLE 2 Etiologies of Pericardial Diseases

Category	Examples
Idiopathic	■ Without identifiable etiology or trigger, presumed autoinflammatory, may be viral
Infective	■ **Viral:** coxsackieviruses, echoviruses, adenoviruses, parvovirus B-19, herpesviruses, HIV, COVID-19 ■ **Bacterial:** *Mycobacterium* species, including tuberculosis, *Staphylococcus, Streptococcus, Pneumococcus, Mycoplasma, Hemophilus, Neisseria, Mycoplasma, Chlamydia, Legionella, Leptospira, Listeria, Coxiella, Borrelia burgdorferi, Cutibacterium acnes, Trypanosoma cruzi* ■ **Fungal:** *Candida*, histoplasmosis, coccidioidomycosis ■ **Protozoal:** toxoplasma
Autoimmune	■ **Systemic conditions:** systemic lupus erythematosus, rheumatoid arthritis, scleroderma, systemic sclerosis, dermatomyositis, polymyositis, mixed connective tissue disease, vasculitis, inflammatory bowel disease, sarcoidosis, Behçet disease, Still disease, immunoglobulin G4-related diseases, Erdheim-Chester disease ■ **Autoinflammatory conditions:** familial Mediterranean fever, tumor necrosis factor receptor 1-associated periodic syndrome ■ **Drug induced:** procainamide, isoniazid, hydralazine, cyclosporine
Neoplastic	■ **Primary:** mesothelioma, fibrosarcoma, lipoma ■ **Secondary/metastatic:** lung cancer, breast cancer, lymphoma, Kaposi sarcoma
Radiation	■ Radiotherapy
Hemopericardium/Post-cardiac injury	■ **Postcardiotomy/thoracotomy** (any cardiac or thoracic surgery) ■ **Percutaneous/transcatheter procedures**: catheter ablation (including epicardial access), cardiac implantable electronic devices, percutaneous coronary intervention, transcatheter valve or congenital heart interventions, endomyocardial biopsy ■ Trauma ■ Myocardial infarction complicated by free wall rupture ■ Aortic dissection ■ Anticoagulation
Primary cardiac	■ **Myocardial infarction** (Dressler syndrome) ■ **Myocarditis** (perimyocarditis and myo-pericarditis) ■ Stress cardiomyopathy
Congenital	■ Pericardial cysts/diverticuli ■ Congenital absence of the pericardium
Metabolic	■ **Uremia, dialysis associated** ■ Endocrine: hyperthyroidism, hypothyroidism, cholesterol, anorexia
Other	■ Amyloidosis ■ Polycystic kidney disease ■ Chylopericardium ■ Pulmonary arterial hypertension ■ Pectus excavatum ■ Other drugs including chemotherapy

Adapted with permission from Klein et al.[1]

FIGURE 3 Pathophysiology of Pericardial Inflammation

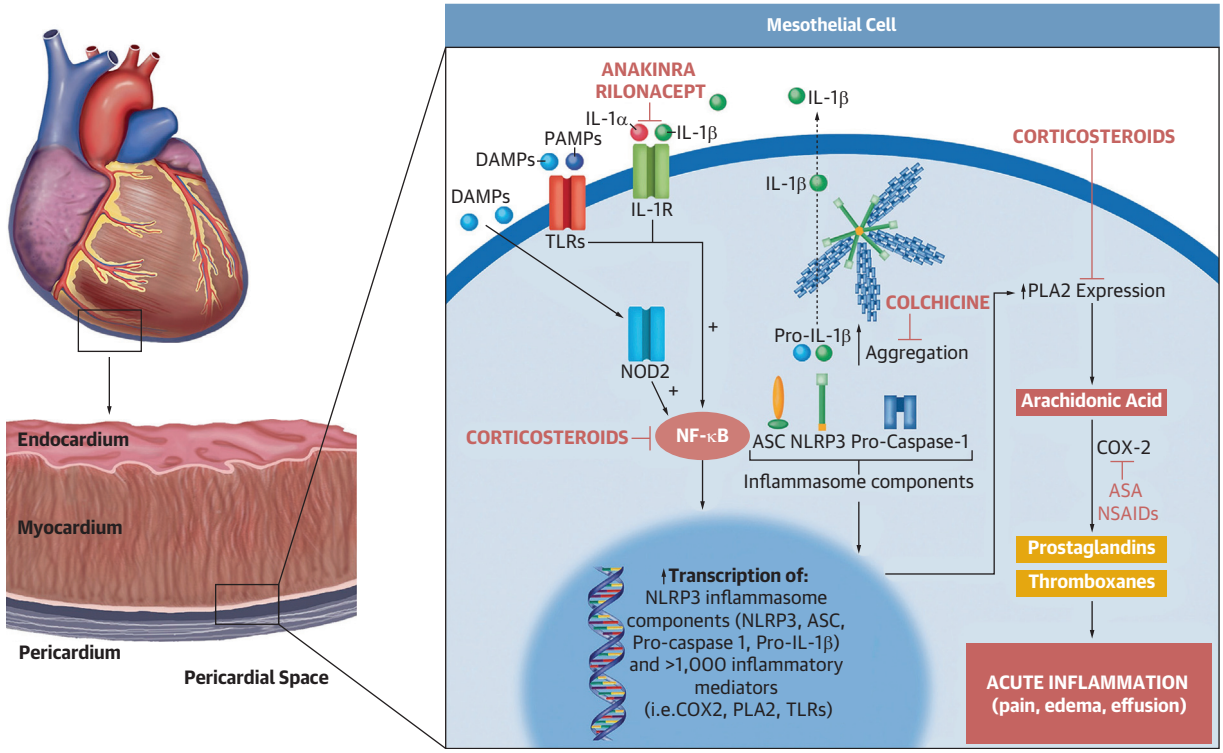

Injury to the pericardium leads to the release of DAMPs and PAMPs and induces NF-κB synthesis, which increases the transcription of precursors of inflammatory molecules and associated cytokines (NLRP3, ASC, pro-caspase-1) required for the polymerization of the NLRP3 inflammasome, ultimately releasing IL-1β and IL-18. NF-κB stimulates the synthesis of phospholipase-A2 required for promoting the arachidonic acid pathway and the subsequent synthesis of prostaglandins and thromboxanes. The IL-1 receptor (IL-1R) occupies a central role, as IL-1α functions as an alarmin or DAMP being released during tissue injury, and IL-1β is processed and released by the inflammasome, leading to amplification of the process. Adapted with permission from Chiabrando et al.[8] ASA = acetylsalicylic acid; ASC = apoptosis-associated Speck-like protein containing a carboxyterminal caspase-recruiting domain; DAMP = damage-associated molecular pattern; IL = interleukin; NF-κB = nuclear factor kappa-light-chain enhancer of activated B cells; NLRP3 = NACHT, leucine-rich repeat, and pyrin domain-containing protein 3; NOD = nucleotide-binding oligomerization domain; NSAID = nonsteroidal anti-inflammatory drug; PAMP = pathogen-associated molecular pattern; PLA2 = phospholipase A2; TLR = toll-like receptor.

4.1.3. The Role of Inflammation in Pericardial Disease

Pericarditis is characterized by a severe inflammatory response to injury of the mesothelial cells of the pericardium, triggered by factors such as viral infections, cardiac surgery or procedures, or immune derangements.[8-10] The initial immune reaction is typically a result of an unrelated stimulus that activates the inflammasome, a macromolecular cellular structure, that then activates inflammatory cytokines, such as interleukin-1β. The underlying etiology, whether infectious, autoimmune, or related to mechanical injury, also contributes to inflammation through distinct mechanisms, including the transcription and translation of proinflammatory genes and inflammasome components, leading to the activation of caspase-1 and maturation of interleukin-1β and other inflammatory cytokines. Derangements in the innate and adaptive immune response contribute to disparate clinical phenotypes and account for significant patient-level variability.[11] Dysregulated immunity is often implicated in recurrent and chronic cases, and identification of these derangements can refine targeted immunosuppressive therapies (Figure 3).

4.1.4. Multimodality Imaging and Pericardial Disease

Novel advanced multimodality imaging techniques such as echocardiography, cardiac magnetic resonance (CMR), and cardiac computed tomography (CCT) play crucial roles in diagnosis, prognosis, and management, offering

JACC VOL. 86, NO. 25, 2025
DECEMBER 23/30, 2025:2691-2719

TABLE 3 Standard Multimodality Cardiac Imaging Techniques and Protocols for Evaluating Pericardial Diseases

	TTE	CCT	CMR
Technique	a) 2-dimensional echocardiography b) Doppler echocardiography c) M-mode echocardiography d) Speckle-tracking echocardiography	a) Axial imaging, multiplanar reconstruction volume-rendered imaging + contrast and delayed phase b) Cine imaging (retrospective ECG gating)	a) Cine white-blood imaging (steady-state free precession) b) Black-blood imaging (T_1W or T_2W turbo spin echo, fat suppression may be considered) c) T_2-STIR d) LGE imaging (fat suppression recommended) e) Free-breathing cine imaging (gradient echo) f) Myocardial tagging g) Other T_1, T_2, fat saturation sequences
Evaluation	a) Pericardial thickness PEff: location, size, fluid characteristics, pericardiocentesis approach CTP: IVC plethora, cardiac chamber collapse, swinging heart CP: IVC plethora and respirophasic septal shift, wall tethering, ventricle conical deformity, pericardial thickening Pericardial mass: location, size Chamber quantification and regional wall motion abnormalities b) CTP: respirophasic variation E-wave mitral inflow >30%/tricuspid inflow >60% CP: Mitral E/A ratio >0.8, mitral medial e' >8 cm/s, annulus reversus, hepatic vein expiratory end-diastolic reversal/forward velocity >0.8, respirophasic variation E-wave mitral inflow >25%/tricuspid inflow >40%	a) Pericardial thickening, calcifications PEff: location, size, fluid characteristics, pericardiocentesis approach Pericardial mass characterization b) Chamber quantification Chamber tethering Septal bounce	a) Chamber quantification, CP: septal bounce, conical deformity, wall tethering; PEff: location, size b) Pericardial thickness, IVC plethora Pericardial mass: location, size c) Pericardial edema, myocardial edema d) Pericardial inflammation/fibrosis, myocardial inflammation/fibrosis e) Respirophasic septal shift in CP f) Wall tethering in CP g) PEff and pericardial mass characterization

Adapted with permission from Klein et al.[1]

CCT = cardiac computed tomography; CMR = cardiac magnetic resonance; CP = constrictive pericarditis; CTP = cardiac tamponade; ECG = electrocardiogram; IVC = inferior vena cava; LGE = late gadolinium enhancement; PEff = pericardial effusion; STIR = short-tau inversion recovery; T_1W = T1$_1$-weighted, T_2W = T_2-weighted, TTE = transthoracic echocardiography.

detailed assessment of pericardial inflammation, effusion, and constrictive physiology—while enhancing diagnostic precision for assessing disease activity and monitoring progression and responses to therapy.[1,3,12] **Table 3** shows the standard imaging techniques and protocols of multimodality imaging.

4.1.5. Pericardial Diseases Center of Excellence

A pericardial diseases center (PDC) offers a structured solution to managing the complexity of pericardial disorders, which can otherwise strain healthcare systems.[13,14] These centers are particularly effective in improving care and outcomes for patients with recurrent or refractory pericarditis, as well as those requiring frequent follow-ups, while reducing emergency visits and hospitalizations. Indications for referral to a specialized pericardial center include recurrent, incessant or chronic pericarditis, suspected or confirmed constrictive pericarditis, large or complex pericardial effusion requiring pericardial drainage or window, or when advanced therapies, such as biologics and pericardiectomy, are being considered. PDCs also play a vital role in screening patients for clinical trials and monitoring responses and adverse events of emerging treatments. **Figure 4** summarizes the framework and key components of a PDC.

The development of such a PDC begins with a needs assessment, considering local disease prevalence, healthcare gaps, and resource availability. A well-defined protocol is critical, outlining staff responsibilities, referral processes, clinical workflows, and strategies for continuous quality improvement. These centers should provide access to specialized resources, including multimodality imaging (eg, echocardiography, CMR, CCT), rheumatology, infectious diseases, genetics, consultation with cardiothoracic surgery, and specialty pharmacies. Advanced practice providers play a major role in the workflow of a PDC.[14] Clear communication pathways ensure timely referrals and follow-ups, particularly for high-priority cases. Key components of

FIGURE 4 Framework and Components of a Pericardial Diseases Center

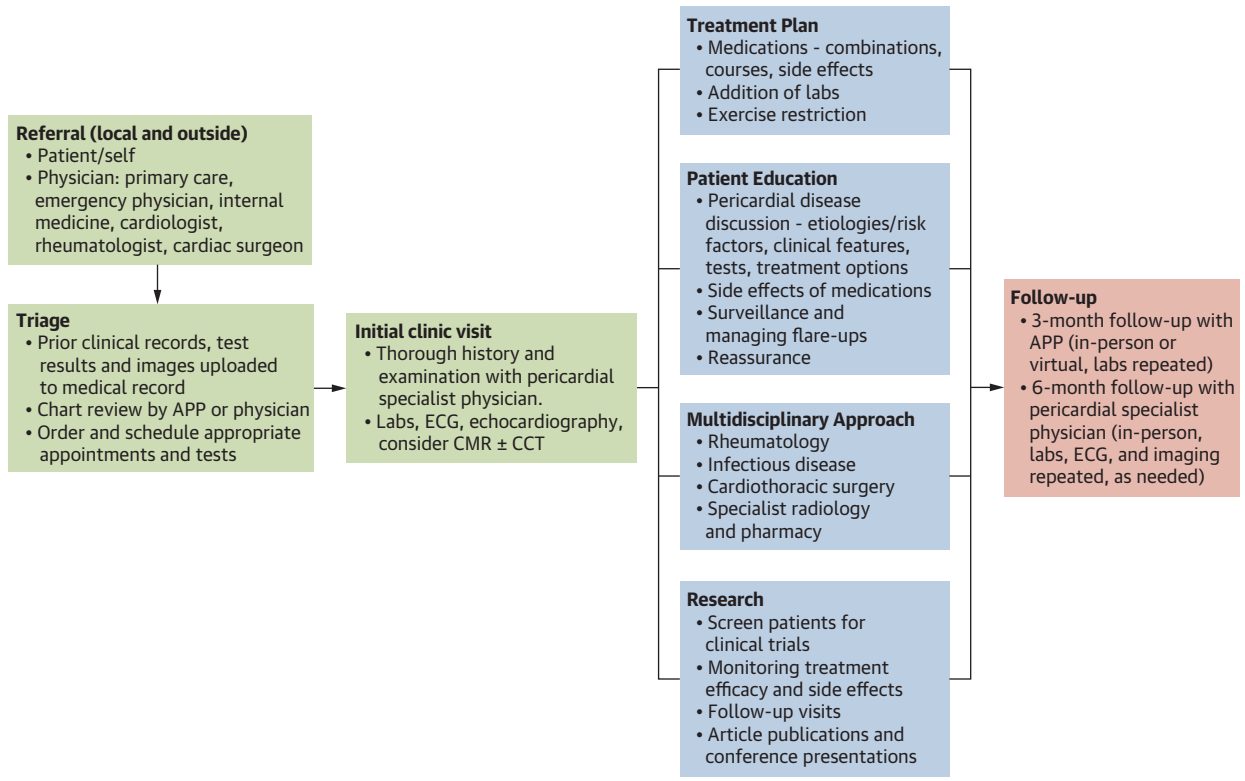

APP = advanced practice provider; CCT = cardiac computed tomography; CMR = cardiac magnetic resonance; ECG = electrocardiogram.

a PDC include comprehensive evaluations, timely imaging and laboratory investigations, and personalized treatment plans. Patients benefit from dedicated education on self-management strategies and access to rapid interventions, which help mitigate disease flares. Follow-up schedules are adjusted based on individual patient needs, ranging from frequent visits during active phases (such as every 3 months) to less frequent visits when stable (such as every 6-12 months). Protocols for medication adjustments, escalation, or tapering are also integral, ensuring effective disease management in collaboration with multidisciplinary teams. As patient volumes increase, PDCs can evolve from being part of broader cardiovascular services to standalone units, optimizing specialized care delivery. By enhancing patient outcomes and streamlining healthcare utilization, PDCs represent a valuable model for managing these conditions within tertiary care centers.

4.2. Pericarditis

4.2.1. Novel Clinical Diagnostic Criteria and Perspectives

Based on expert consensus, we propose the following novel diagnostic criteria for pericarditis (Figure 5):

1. Pleuritic chest pain or equivalent with suggestive clinical presentation (must be present)
2. Plus ≥1 additional finding (0 = unlikely, 1 = possible, and 2+ = definitive diagnosis).
   a. Pericardial friction rub (<1/3)
   b. Electrocardiogram changes consisting of diffuse ST-segment elevation and/or PR-segment depression (up to 60%)
   c. Inflammatory biomarkers elevation (such as C-reactive protein [CRP], sedimentation rate)

JACC VOL. 86, NO. 25, 2025
DECEMBER 23/30, 2025:2691-2719

FIGURE 5 Novel Diagnostic Criteria and Classification by Duration for Pericarditis

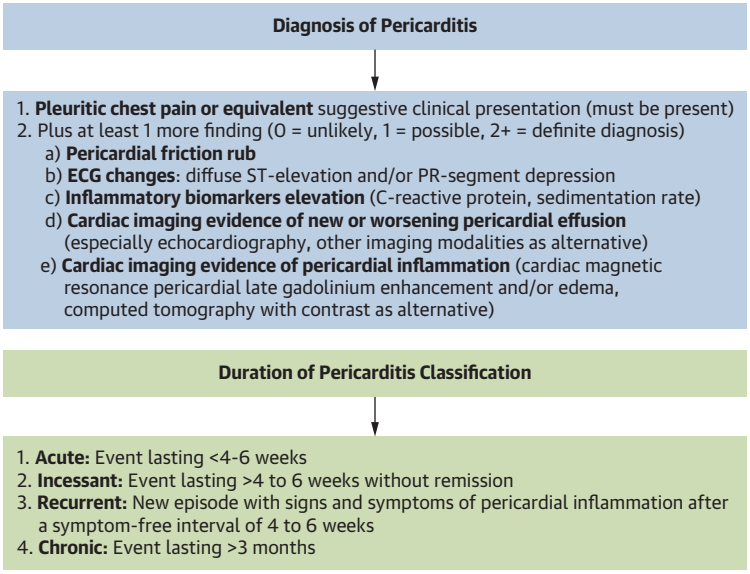

Duration of pericarditis classification is adapted with permission from Chiabrando et al.[8] ECG = electrocardiogram.

d. Cardiac imaging (especially echocardiography evidence) of new or worsening pericardial effusion (up to 60%)
e. Cardiac imaging evidence of pericardial inflammation (especially CMR pericardial late gadolinium enhancement/edema, computed tomography as alternative)

These criteria, in comparison with the prior 2015 European Society of Cardiology guidelines criteria,[7] place more emphasis on the clinical presence of classic chest pain or equivalent (typically sharp, pleuritic, relieved by sitting up or leaning forward) being necessary for diagnosis, incorporating equally elevated inflammatory biomarkers and multimodality cardiac imaging findings of pericardial effusion and inflammation into the criteria, and dividing into categories of definite, possible, and unlikely pericarditis diagnoses. The diagnostic criteria likely perform best in patients with acute pericarditis, though can be applicable to patients with recurrences/flares.

About 15% of patients will have concomitant myocarditis such as peri-myocarditis (myocarditis dominant) or myo-pericarditis (pericarditis dominant), manifested by elevated markers of myocardial injury (troponin) and left ventricular global or regional systolic dysfunction.[7,15] Pericarditis encompasses several conditions including a noninflammatory phenotype (low or near normal CRP, often associated with autoimmune conditions) seen in 10% to 20% of cases, and an inflammatory phenotype seen in 80% to 90% of patients. These patients with an inflammatory phenotype and elevated CRP can present with high fever, neutrophilic leukocytosis, and pericardial and/or pleural effusions.[16,17] If treated with appropriate anti-inflammatory therapies, most acute pericarditis cases will have a benign course and resolve without recurrence. Risk factors for a poor prognosis and/or need for hospitalization include high fevers, subacute course, presence of large pericardial effusion with echocardiography features of tamponade physiology, failure to respond to nonsteroidal anti-inflammatory drugs (NSAIDs), as well as concomitant myocarditis.[1]

Acute pericarditis refers to the diagnosis with full resolution of symptoms within 4 weeks. Recurrent pericarditis is diagnosed when there is a relapse of symptoms following a symptom-free interval of ≥4 to 6 weeks after the initial flare, with completion of medical therapy. Recurrence rates after an initial episode vary from 15% to 30% and further increase to 50% after a first recurrence.[7,15] Risk factors for recurrence include a lack of

response to NSAIDs, early use of corticosteroids, high CRP, and severe pericardial LGE on CMR.[18] Patients who do not achieve remission and have symptoms for >4 to 6 weeks but <3 months before resolution no longer have acute pericarditis, and are labeled as having incessant pericarditis, which can be more aggressive, whereas chronic pericarditis requires >3 months of symptoms. As with acute pericarditis, the presentation of recurrent or incessant/chronic pericarditis can be either inflammatory or noninflammatory, a distinction that significantly influences therapeutic approaches.

4.2.2. Evaluation and Multimodality Imaging

Evaluation starts with a thorough history, physical examination, electrocardiogram, and laboratory tests, especially elevation in sedimentation rate and CRP, along with troponin levels if myocarditis is suspected (**Figure 5**). In the presence of personal and family history or risk factors of infections, autoimmune diseases, or malignancies, associated investigations should be performed.[1] Multimodality cardiac imaging has become a crucial pillar in the evaluation of pericarditis. Transthoracic echocardiography (TTE) remains the first-line imaging modality for assessing suspected pericarditis.[1,3] Although often normal, pericarditis findings on TTE may include presence of pericardial effusion (without or with tamponade), pericardial thickening, features of constrictive physiology, and/or myocardial involvement in the setting of myo-pericarditis (such as left ventricular systolic impairment and/or regional wall motion abnormalities) (**Table 4**).[1] TTE can be serially used to monitor for improvement or worsening of these abnormal findings when present (**Table 5**). TTE's main limitation is the inability of tissue characterization to identify and grade pericardial inflammation. TTE will also provide additional information regarding cardiac chamber size and function, valvular abnormalities, pulmonary hypertension, and aortic diseases. Transesophageal echocardiography and stress echocardiography are not generally required for diagnosing pericarditis.

CMR has become a valuable comprehensive second-line imaging modality in the diagnosis, risk stratification, and surveillance (including response to therapy) of pericarditis.[19] CMR should be considered in patients with acute complicated, incessant, recurrent, or chronic pericarditis, especially when diagnostic uncertainties exist; patients who do not respond to standard first-line therapies and/or in whom escalation of therapies is planned; and patients with suspected pericardial complications such as complex effusions and/or constrictive physiology (**Table 5**).[1] The main CMR findings of pericarditis include pericardial late gadolinium enhancement on phase-sensitivity inversion recovery sequence (ideally fat-suppressed) indicating neovascularization/inflammation (**Figure 6**, and new grading criteria **Figure 7**), increased pericardial signal on T_2-short tau inversion recovery sequence indicating edema, pericardial thickening (>3 mm) especially on black-blood spin echo sequence, and pericardial effusion, whilst features of constrictive physiology may also be observed (**Table 4**).[1,19] With adequate treatment leading to resolution of the acute pericarditis flare, pericardial edema disappears and pericardial effusion and constriction may improve, whereas pericardial late gadolinium enhancement lags behind clinical improvement and typically decreases but not entirely resolves into the chronic phase in those with recurrent, incessant, or chronic pericarditis, before disappearing either after a longer period of resolution or in patients with burned out calcific constrictive pericarditis.[1,20]

CCT is the preferred modality in the assessment of pericardial calcifications in constrictive pericarditis. Other

TABLE 4 Characteristic Imaging Features in Pericarditis

TTE	CCT	CMR
■ Normal findings in some patients. Pericardial thickening	■ Noncalcified pericardial thickening (>3 mm)	■ Thickening of pericardium at T_1-weighted BB images (>3 mm)
■ Segmental wall motion abnormalities or pathological myocardial strain values (in case of myocarditis)	■ Enhancement of the thickened visceral and parietal surfaces of the pericardial sac at late postcontrast CT scan	■ Enhancement of pericardium on LGE sequence (inflammation) and T_2-STIR sequence (edema) consistent with active inflammation and neovascularization (of prognostic importance) ■ LGE+/T_2-STIR+: acute/subacute phase or recurrent flares ■ LGE+/T_2-STIR-: subacute or chronic phase ■ LGE-/T_2-STIR-: resolution or end-stage/calcific phase
■ PEff with or without CTP (present in 40%-50% of cases)	■ PEff presence. CT attenuation values of the PEff may help distinguish between exudative and transudative fluid (on noncontrast CT)	■ PEff presence. High signal intensity on T_1-weighted BB images is suggestive of exudative PEffs
■ Sign of CP (often transient)		■ Loss of the normal sliding between pericardial layers during the cardiac cycle is one feature consistent with pericarditis

Adapted with permission from Klein et al.[1]

BB = black-blood; CCT = cardiac computed tomography; CMR = cardiac magnetic resonance; CP = constrictive pericarditis; CT = computed tomography; LGE = late gadolinium enhancement; PEff = pericardial effusion; T_2-STIR = T_2-short tau inversion recovery; TTE = transthoracic echocardiography.

JACC VOL. 86, NO. 25, 2025
DECEMBER 23/30, 2025:2691-2719

TABLE 5 Recommendations for Diagnostic Evaluation, Multimodality Cardiac Imaging, and Management for Pericarditis

Recommendation	Class
Thorough history recording (including symptoms description and duration, risk factors, assessment of systemic inflammatory diseases), physical examination (auscultation of rubs), and ECG (for pericarditis changes) as part of evaluation for pericarditis	Recommended
Assessment of the presence of systemic inflammation by means of C-reactive protein, fever, neutrophil leukocytosis, and presence of pericardial and pleural effusion to target specific treatments	Recommended
TTE for evaluating and surveillance of pericardial effusion, signs of tamponade, constriction, and myocardial involvement of pericarditis	Recommended
CMR for initial evaluation of pericarditis in terms of pericardial LGE, edema, thickening, effusion, signs of constriction, and myocardial involvement for diagnosis and risk stratification, especially for complicated/indeterminant cases	Recommended (recurrent/incessant pericarditis) Reasonable (acute pericarditis)
CMR for assessing treatment response and surveillance of pericarditis	Reasonable (recurrent/incessant pericarditis) Not recommended (acute pericarditis)
CCT for evaluation of other chest pain causes other than acute pericarditis	Reasonable
CCT for routine assessment of pericarditis	Not recommended
High-dose aspirin or NSAID in combination with colchicine (3 mo, acute; 6 mo, recurrent) as first-level therapies for pericarditis (aspirin is preferred in case of concomitant ischemic heart disease)	Recommended
Anti-IL-1 agents may be considered in acute pericarditis with the inflammatory phenotype when other therapies are contraindicated, ineffective, or not tolerated	Reasonable
Corticosteroid use should be restricted to acute pericarditis cases that are refractory or intolerant to other therapies (usually low-medium doses)	Reasonable
Anti-IL-1 agents in recurrent/incessant pericarditis after failure of first-level therapies and/or corticosteroids, especially with evidence of inflammatory phenotype	Recommended
Corticosteroids after failure of first-line therapies for current/incessant pericarditis, especially without evidence of C-reactive protein elevation or specific conditions (eg, autoimmune diseases)	Reasonable
In high-volume experienced pericardial surgical centers, radical pericardiectomy is an alternative option for patients who do not respond to medical therapy for pericarditis	Reasonable
Exercise restriction for ≥1 mo after pericarditis diagnosis or flare (maximal heart rate <100 beats/min regardless of activity) until clinical remission	Recommended

Adapted with permission from Klein et al.[1]

CCT = cardiac computed tomography; CMR = cardiac magnetic resonance; ECG = electrocardiogram; IL-1 = interleukin-1; LGE = late gadolinium enhancement; NSAID = nonsteroidal anti-inflammatory drug; TTE = transthoracic echocardiography.

FIGURE 6 Hallmarks of Pericarditis on Cardiac Magnetic Resonance

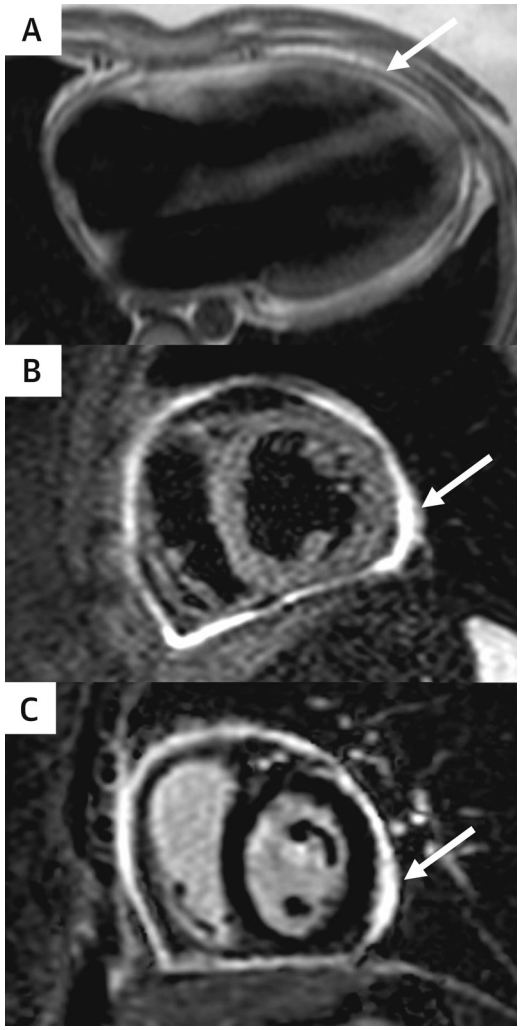

(A) Black-blood spin echo sequence axial image showing pericardial thickening (arrow). (B) T_2-short tau inversion recovery sequence short-axis image showing pericardial edema (arrow). (C) Phase-sensitive inversion recovery sequence short-axis images with fat suppression showing pericardial late gadolinium enhancement indicating inflammation (arrow). Adapted with permission from Klein et al.[1]

CCT findings in pericarditis may include the presence of pericardial effusion, thickening, and inflammation on delayed contrast sequence (although less accurate than CMR) (Table 4).[1,3] While CCT is not primarily used for diagnosing pericarditis, it can be valuable for preoperative planning in cardiac surgeries, such as pericardiectomy. Additionally, CCT is more useful in assessing other differential diagnoses of chest pain, such as acute aortic syndromes, pulmonary embolism, and coronary artery disease, although disadvantages include radiation exposure and, when iodinated contrast is used,

FIGURE 7 Proposed Pericardial Late Gadolinium Enhancement Grading Criteria by Cardiac Magnetic Resonance

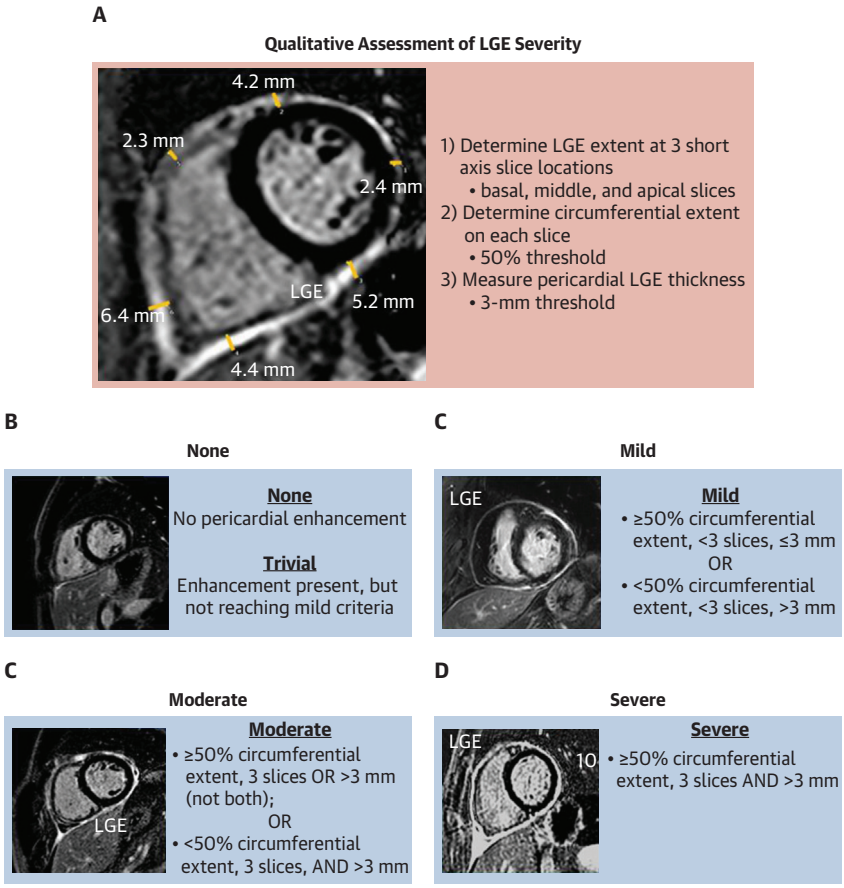

Pericardial LGE severity grading criteria on CMR PSIR-LGE sequence (fat-suppressed sequence suggested), based on pericardial enhancement thickness and circumferential extent on short-axis imaging at basal, mid, and apical slices. Adapted with permission from Klein et al.[1] CMR = cardiac magnetic resonance; LGE = late gadolinium enhancement; PSIR-LGE = phase-sensitive inversion recovery late gadolinium enhancement.

risks of kidney disease and contrast allergy. Use of nuclear imaging such as fludeoxyglucose-positron emission tomography for assessing pericarditis is currently limited to the research setting or in patients who cannot have CMR (ie, claustrophobia, gadolinium allergy, severe obesity).[21]

4.2.3. Management

Contemporary management of pericarditis aims to control symptoms and prevent complications (mainly recurrences) and hospitalizations.[22] First-line pharmacological treatment includes dual anti-inflammatory therapy with colchicine (3 months following first flare, ≥6 months following first recurrence) and NSAIDs or aspirin (starting at high dose and tapering after symptoms resolve and inflammatory markers normalize) (Tables 5 and 6). Acid suppression therapies (eg, proton-pump inhibitors) are often concomitantly prescribed with NSAIDs for gastric protection.[1] Exercise restriction for ≥1 month (maximal heart rate <100 beats/min with physical activity) until clinical remission is important.[23] Increased heart rate can trigger pericardial inflammation by enhancing the frequency of friction of pericardial layers. In patients with autoimmune pericarditis, the focus should be on treating the underlying autoimmune condition first, as the pericarditis often improves or resolves with that alone. Hospital admission may be necessary in complicated high-risk cases, such as large pericardial effusion and/or tamponade, severe pain refractory to first-line therapies, and symptomatic constrictive pericarditis. Of note, prompt diagnosis and therapy are recommended for

JACC VOL. 86, NO. 25, 2025
DECEMBER 23/30, 2025:2691-2719

TABLE 6 Common Therapeutic Options for Acute Pericarditis and Recurrent Pericarditis

Therapy	Dosing	Duration*	Tapering	Monitoring†	LOE‡
Aspirin§,‖	500-1,000 mg 3 times daily	wks (acute) to mo (recurrent)	Weekly	Needed	A
Ibuprofen§,‖	600-800 mg 3 times daily	wks (acute) to mo (recurrent)	Weekly	Needed	A
Indomethacin‖	25-50 mg 3 times daily	wks (acute) to mo (recurrent)	Weekly	Needed	B
Colchicine§,¶	0.6 mg twice daily or 0.6 mg once daily (<70 kg, severe renal/hepatic impairment)	3 mo (acute), 6-12 mo (recurrent)	May be considered	Needed	A
Prednisone#	0.2-0.5 mg/kg/d	wks to mo	Several mo	Needed	B
Anti-IL-1 agents**					
Anakinra	1-2 mg/kg/d up to 100 mg/d in adults	>12 mo	Needed	Needed	A
Rilonacept	320 mg once followed by 160 mg weekly	>12 mo	Stopping vs tapering under investigation	Needed	A
Goflikicept (Not yet available in United States)	80 mg every 2 wks	>12 mo (under investigation)	Unknown	Needed	B
Azathioprine	Starting with 1 mg/kg per d then gradually increased to 2-3 mg/kg/d	Several mo	Several mo	Needed	C
IVIG	400 to 500 mg/kg IV daily for 5 d	5 d	Not required	Needed	C
Radical pericardiectomy	High-volume pericardial surgical centers	Not applicable	Not applicable	Needed	C

Adapted with permission from Klein et al.[1]
*Therapy duration at initial dosing; duration of therapy is until clinical remission (typically longer times for recurrent cases).
†Monitoring is mandatory for all medications and may include assessment of blood count, renal function, creatine kinase, liver enzymes, lipid profile, and echocardiography, along with C-reactive protein and sedimentation rate to monitor pericarditis response to therapy or diagnose recurrence.
‡A = Data derived from multiple randomized clinical trials or meta-analyses. B = Data derived from a single randomized clinical trial or large nonrandomized studies (in this review, a study with ≥100 patients is considered "large"). C = Consensus of opinion of experts and/or small studies, retrospective studies, and registries.
§Ibuprofen and aspirin are common first-level treatments for the first episode of pericarditis (acute pericarditis) associated with colchicine for 3 months (usually longer times for recurrent cases). Aspirin often considered when patients are already on or have another indication to be on aspirin. Aspirin can be given as 325-650 mg 3 times daily.
‖In patients with a relative contraindication to NSAIDs (such as heart failure, chronic kidney disease, peptic ulcer disease, bleeding diathesis or cancer-related hypercoagulability, or when coprescribing with diuretics, angiotensin-converting enzyme inhibitors, angiotensin receptor blockers, calcineurin inhibitors or anticoagulants), NSAIDs should be prescribed at the lowest effective dose and for the shortest duration possible, and alternatives should be considered (such as high-dose aspirin in those without elevated bleeding risk).
¶Dose reductions (0.3-0.6 mg daily) should be considered when coprescribing colchicine with potent inhibitors of P-glycoprotein (P-gp) and/or cytochrome P450 3A4 (CYP3A4) to improve tolerability and reduce the risk of toxicity. Of note, dose reduction for drug-drug interactions was not evaluated in colchicine pericarditis clinical trials. Adjusting concomitant medications (via therapeutic substitutions that avoid P-gp or CYP3A4 interactions) can also be considered to maximize the tolerated dose of colchicine prescribed.
#Increased risk of recurrence if used in first episode pericarditis.
**Before starting anti-IL-1 agents, patients should be screened to be negative for hepatitis, human immunodeficiency virus, and tuberculosis.
IL-1 = interleukin-1; IV = intravenous; IVIG = intravenous immunoglobulin; LOE = Level of Evidence; NSAID = nonsteroidal anti-inflammatory drug.

pericarditis following cardiac procedures, as they are often underdiagnosed or misdiagnosed. Anti-inflammatory prophylaxis, such as colchicine, can be considered to prevent post-cardiac injury pericarditis, although data supporting this approach are limited.

Traditionally, for patients deemed to be nonresponders to first-line dual therapy (experiencing recurrence or intolerance to treatment with first-line agents), corticosteroids were added to the treatment regimen. Low to moderate doses of corticosteroids (eg, prednisone 0.2-0.5 mg/kg/day) are initiated and maintained until clinical remission, followed by a slow tapering over months (**Table 5**).[22] Corticosteroids are prescribed with caution because of the plethora of known side effects, such as weight gain, hypertension, hyperglycemia, osteoporosis, increased risk of infections, gastrointestinal ulcers, and risk of adrenal suppression. Pharmacological prophylaxis for pneumocystis pneumonia and osteoporosis should be considered for patients requiring glucocorticoid doses equivalent to >20 mg of prednisone for 1 month or longer.

Anti-interleukin-1 (anti-IL-1) agents have been demonstrated in several recent phase 3 randomized clinical trials to have strong efficacy in pericarditis patients with elevated CRP (>1 mg/dL or >10 mg/L) to achieving clinical remission, improve symptoms, reduce recurrences, and normalize inflammatory markers while maintaining good safety profile.[1,24-26] As a result, there has been a recent paradigm shift in managing patients with the inflammatory phenotype (fever and/or elevation of CRP and/or CMR imaging evidence of pericardial inflammation) who meet the

FIGURE 8 Proposed Schematic Algorithm for Treatment of Recurrent Pericarditis

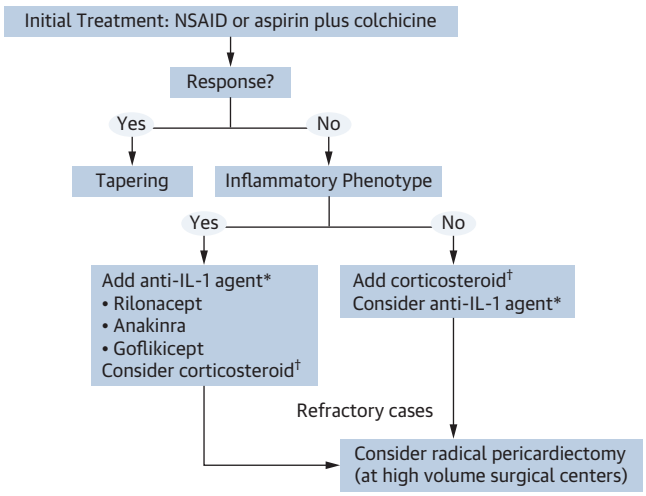

*Anti-IL-1 agent: rilonacept ≥12 months, anakinra and goflikicept ≥12 months, can be years or long-term. †Corticosteroids: start at moderate dose, slow taper over months. Adapted with permission from Klein AL, et al.[1] IL-1 = interleukin-1; NSAID = nonsteroidal anti-inflammatory drug.

aforementioned indications for corticosteroids or have become steroid-dependent, for the initiation of novel therapies targeted at the autoinflammatory process. These agents should be considered the preferred option over corticosteroids in this setting (**Figure 8**). Typically, other anti-inflammatories may be sequentially weaned off once established on anti-IL-1 agents (such as prednisone, then NSAID, then colchicine), although colchicine may sometimes be continued, with some limited evidence for additive or synergistic benefits, further reducing recurrence compared with using an anti-IL-1 agent alone, particularly with anakinra.[27,28] The optimal treatment duration with anti-IL-1 therapies remains uncertain, as recurrence rates are very low while on treatment, and many patients (~50%-75%) have recurrence upon discontinuation. A recently published long-term extension of the RHAPSODY (Rilonacept in Acute Pericarditis Study) trial[25] supports prolonged therapy beyond 18 months to achieve a better and prolonged control of the disease,[29] and further research is necessary to determine the optimal treatment duration and stopping or weaning method for each anti-IL-1 agent. In contrast, low-dose corticosteroids are typically utilized for patients lacking evidence of the inflammatory phenotype, as autoimmune mechanisms are presumed to play a more significant role in these patients (**Table 5** and **Figure 8**).[1]

Azathioprine and intravenous immunoglobulins may also be considered for patients who fail corticosteroids and anti-IL-1 agents.[30] Radical pericardiectomy on cardiopulmonary bypass can be considered as a last resort or alternative option at high-volume experienced pericardial surgical centers, especially when patients fail to respond to the aforementioned pharmacotherapies, have contraindications to conventional therapy, or desire pregnancy. In this setting, anti-inflammatory medications, including corticosteroids and/or anti-IL-1 agents, may be continued until surgery to dampen inflammation as much as possible, and may be continued for 3 to 6 months as indicated for ongoing symptoms of pericardial inflammation or active inflammation noted on the pericardial pathology. Novel risk scores including machine learning models have been developed to help with risk prognostication of recurrent pericarditis flares to guide management.[31]

4.3. Complications of Pericarditis

4.3.1. Pericardial Effusion

Pericardial effusion is defined by the accumulation of >50 mL of fluid in the pericardial space and can be a result of numerous pathologies.[3,7] Approximately one-half of pericardial effusions are idiopathic, and in North America and Western Europe, postviral infection is the most common identifiable cause, whereas tuberculosis is the most common cause in places where it is endemic (Table 2).[30,32] Malignancies are also an important cause of pericardial effusion and can present as an inflammatory effusion with negative cytology for cancer.[33,34]

The objectives of imaging pericardial effusions are to support diagnosis, evaluate the size and location of the effusion, assess its hemodynamic impact, and inform decisions regarding drainage, if indicated (Tables 7 and 8).[1] TTE is the first-line imaging investigation because it is readily available and accurately achieves these objectives). The size of a pericardial effusion is determined by measuring the greatest diameter perpendicular to the epicardium and parietal pericardium at end-diastole or -systole adjacent to ventricles and atria, respectively, with the following categories: trivial (<1.0 cm and not visualized throughout cardiac cycle), small (<1.0 cm), moderate (1.0-1.9 cm), large (2.0-2.5 cm), and very large (>2.5 cm) (Figure 9).[3] Common mimickers of a pericardial effusion echocardiography are a left pleural effusion, which is posterior to the descending thoracic aorta on a parasternal long-axis view, and an epicardial fat pad, which has a heterogenous echodensity, moves with the myocardium, and is often located anterior to the right ventricle.

CCT is a second-line investigation, and potential advantages include further delineation of the size and extent of a pericardial effusion, characterizing pericardial fluid based on Hounsfield units, informing secondary causes such as malignancy, and guiding drainage (Tables 7 to 9).[1,35] CMR imaging is also a second-line investigation that has the additional advantage of assessing for pericardial inflammation and constriction (Tables 7 to 9).[19]

4.3.2. Cardiac Tamponade and Pericardiocentesis

The hemodynamic consequences of a pericardial effusion are more closely related to the rapidity of fluid accumulation within the pericardium, not the absolute fluid volume because pericardial compliance can increase when

TABLE 7 Multimodality Imaging Protocols for Pericardial Effusions

Echocardiography	CCT	CMR
2D with respirometer ■ Size and characterize PEff in multiple projection ± off-axis views ■ Right ventricle diastolic chamber collapse with CTP ■ Respirophasic septal shift and IVC dilatation with CTP, ECP, and TCP ■ Identify pocket with clear path of vital structures for pericardiocentesis	Noncontrast ECG-gated (single phase) ■ Distinguish mimickers ■ Detect pericardial calcification or hemorrhage	Cine white-blood imaging ± tagging ■ Detect and size PEff ■ Distinguish mimickers ■ Evaluate for ECP and TCP (free-breathing sequence) ■ Assess pericardial thickness and identify adhesions (tagging)
M-mode with respirometer ■ Higher sensitivity for diastolic chamber collapse with CTP ■ Higher sensitivity for respirophasic septal shift with CTP, ECP, and TCP	Arterial ECG-gated (single or multiphase) ■ Detect, size, and characterize content of PEff ■ Identify secondary causes and mimickers ■ Evaluate pericardial thickness	T_1W BB (± T_1 mapping) ■ Detect and characterize PEff ■ Identify secondary causes and mimickers
Doppler with respirometer ■ Respirophasic changes in atrioventricular and hepatic vein velocities with CTP, ECP, and TCP	± delayed ECG-gated (single phase) ■ Detect pericardial inflammation ■ Evaluate for acute bleeding with contrast extravasation into pericardium	T_2-STIR ■ Detect and characterize PEff ■ Evaluate for pericardial edema ■ Evaluate for myocardial edema
± 3D echocardiography ■ ± incremental value in PEff sizing and spatial relationship with surrounding structures ■ ± improved visualization of pericardial adhesions/strands in complex PEff		LGE ■ Ascertain for pericardial thickening and inflammation ■ Evaluate for pericardial malignancies

Adapted with permission from Klein et al.[1]

2D = 2-dimensional; 3D = 3-dimensional; BB = black-blood; CCT = cardiac computed tomography; CMR = cardiac magnetic resonance; CTP = cardiac tamponade; ECG = electrocardiogram; ECP = effusive constrictive pericarditis; IVC = inferior vena cava; LGE = late gadolinium enhancement; PEff = pericardial effusion; STIR = short tau inversion recovery; T_1W = T_1-weighted; T_2W = T_2-weighted; TCP = transient constrictive pericarditis.

TABLE 8 Multimodality Cardiac Imaging Indications, Characterization, and Added Value for Evaluating Pericardial Effusions

Imaging Modality	Echocardiography	CCT	CMR
Indications	■ First-line imaging	■ Second-line if echocardiography inconclusive, or suspects secondary causes	■ Second-line if echocardiography inconclusive, or suspects pericarditis, pericardial malignancy, and/or CP
PEff characterization	■ Transudate: anechoic, homogenous, free flowing ■ Exudate/complex: echogenic, heterogenous ± loculations, stranding or adhesions	■ Transudate: 0-20 HU ■ Exudate: 20-50 HU ■ Hemorrhagic: >50-60 HU ■ If very high HU: pericardial leakage of contrast (eg, ruptured aortic dissection) ■ Chylous: -60 to -80 HU	■ Transudate (homogenous): Low SI on T_1W or T_2W BB High SI on TW2/cine white-blood T_1 time >3,015 ms (1.5-T) Jet-black on LGE PSIR ■ Exudate/complex (nonhomogenous): Intermediate/mixed SI on T_1W or T_2W BB T_1 time <3,015 ms (1.5-T) ■ Acute hemorrhagic: High SI in T_1W or T_2W BB ■ Subacute hemorrhagic: Intermediate SI in T_1W or T_2W BB ■ Chronic hemorrhagic: Low SI in T_1W or T_2W BB
Added value	■ Evaluate for coexisting CTP or ECP ■ Guide pericardiocentesis ■ TEE useful in detecting focal CTP (eg, post-cardiac surgery)	■ Identify secondary causes and mimickers ■ Assess for loculated PEff/focal CTP (stable patients) ■ May identify pericardial inflammation with late iodine enhancement ■ CT-guided pericardiocentesis in challenging cases	■ Evaluate for coexisting pericarditis ■ Evaluate for constriction if echocardiography equivocal ■ Useful when suspecting pericardial malignancy ■ Assess for loculated PEff/focal CTP (stable patients)

Adapted with permission from Klein et al.[1]

BB = black-blood; CCT = cardiac computed tomography; CMR = cardiac magnetic resonance; CP = constrictive pericarditis; CTP = cardiac tamponade; ECP = effusive constrictive pericarditis; HU = Hounsfield units; LGE = late gadolinium enhancement; PEff = pericardial effusion; PSIR = phase-sensitive inversion-recovery; SI = signal intensity; T_1W = T_1-weighted; T_2W = T_2-weighted; TCP = transient constrictive pericarditis; TEE = transesophageal echocardiography.

effusions slowly develop.[32] When pericardial reserve volume is exhausted, additional pericardial fluid results in a marked increase in pericardial pressure with increased and equalized end-diastolic intracardiac pressures.[36] Cardiac output may be maintained initially by a compensatory sinus tachycardia prior to hemodynamic deterioration, and other clinical features include pulsus paradoxus, and hypotension in most but not all cases. Echocardiography is essential in suspected cardiac tamponade, and clinical correlation with symptoms, heart rate, and blood pressure are vital. A dilated inferior vena cava (>2.1 cm) with minimal or no respiratory variation is a useful tool to screen for tamponade (high sensitivity) but does not confirm it, whereas diastolic right ventricular collapse is the most specific finding. Right atrial inversion beyond one-third of the cardiac cycle and marked respiratory variation in ventricular inflow (trans-mitral >30% and trans-tricuspid >60%) are also features of cardiac tamponade (**Figure 10**).[3]

Pericardiocentesis is therapeutically performed in cases of impending or established cardiac tamponade, especially in urgent or emergency settings with echocardiography guidance, and diagnostically when there is concern for specific causes, such as bacterial, tuberculous, or malignant etiologies.[7] In patients with an inflammatory pericardial effusion and no concern for tamponade, anti-inflammatory therapy should be pursued prior to pericardiocentesis. Anatomical approaches to pericardiocentesis include subxiphoid, apical, and parasternal. In an emergency, a subxiphoid or apical approach is preferred. Otherwise, the approach should be determined by where pericardial fluid is most accessible with the least likelihood of damaging intervening vital structures. Echocardiography, fluoroscopy, and/or computed tomography may be utilized to guide the pericardiocentesis procedure. Surgical creation of a pericardial window is considered in select patients with recurrent large pericardial effusions and/or cardiac tamponade despite prior pericardiocentesis. In certain rare cases, radical pericardiectomy surgery may be indicated for recurrent pericardial effusions, even following the creation of a pericardial window, especially when there is concomitant medically refractory constrictive pericarditis or pericarditis.

4.3.3. Constrictive Pericarditis

Constrictive pathophysiology arises from a loss of pericardial elasticity, which impairs diastolic ventricular filling and presents as a heart failure syndrome, typically with normal ejection fraction.[1,37] This condition can be caused by irreversible pericardial thickening and fibrosis, termed chronic constrictive pericarditis, or from

JACC VOL. 86, NO. 25, 2025
DECEMBER 23/30, 2025:2691-2719

FIGURE 9 Pericardial Effusion Sizing Evaluation by Echocardiography

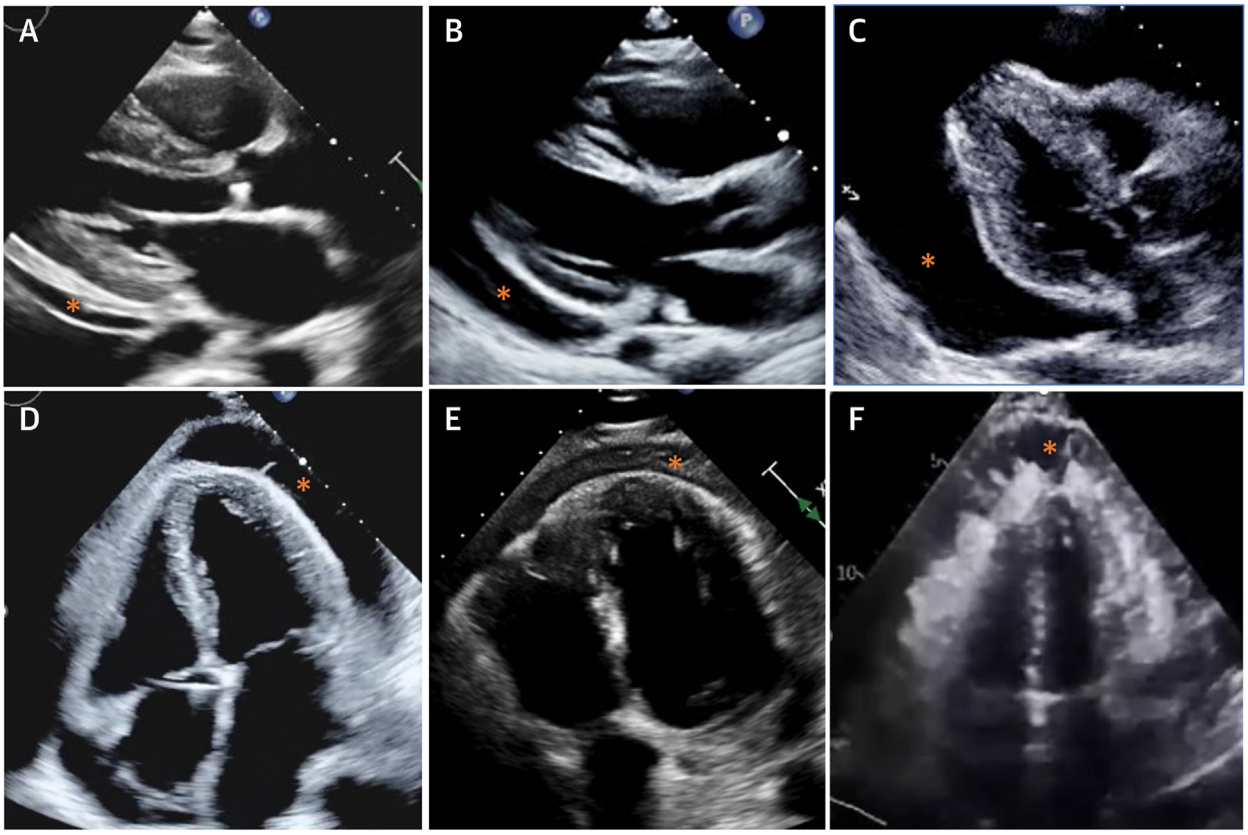

Representative (A) small, (B) moderate, and (C) large PEffs (*). Representative (D) simple PEff with fibrin strands, (E) exudative PEff, and (F) malignant PEff (*) caused by pericardial mesothelioma. Adapted with permission from Klein et al.[1] PEff = pericardial effusion; TTE = transthoracic echocardiography.

significant pericardial inflammation, termed transient constrictive pericarditis. This distinction is crucial, as the former usually requires surgical radical pericardiectomy, whereas the latter may resolve spontaneously or with anti-inflammatory therapy given for 3 to 6 months.[38] In areas where tuberculosis is endemic, it is the most common cause of constrictive pericarditis.[39] Outside of this setting, the most common cause is idiopathic, followed by post-cardiac surgery and prior mediastinal radiation.[1]

Effusive constrictive pericarditis is a distinct entity defined as persistent constrictive pathophysiology after drainage of a pericardial effusion. Classically, this phenomenon was diagnosed invasively by a failure of the right atrial pressure (or pericardial pressure) to decrease following pericardiocentesis and is attributed to marked inflammation of the visceral pericardium.[40] Currently, this condition is often diagnosed based on features of constrictive pathophysiology with echocardiography that appear after pericardial effusion drainage.[41]

The primary objectives of imaging here are to identify constrictive pathophysiology and to assess the presence and severity of pericardial inflammation. Echocardiography and CMR imaging play complementary roles, with echocardiography serving as the primary and initial modality, whereas CMR offers the most comprehensive assessment of pericardial inflammation.[42] The predominant hemodynamic features of constrictive pathophysiology are dissociation of intrathoracic and intracardiac pressures during respiration with resultant accentuated interventricular dependence and elevated diastolic filling

TABLE 9 Recommendations for Multimodality Cardiac Imaging Evaluation and Management for Pericardial Effusions and Cardiac Tamponade

Recommendation	Class
TTE to identify pericardial effusion and assess for cardiac tamponade	Recommended
CCT/CMR or transesophageal echocardiogram to confirm diagnosis of pericardial effusion when clinically indicated if TTE inconclusive	Recommended
CCT/CMR to assess for secondary causes of pericardial effusion when clinically indicated	Reasonable
CCT/CMR for routine assessment of cardiac tamponade	Not recommended
Transesophageal echocardiogram/CCT to confirm clinical diagnosis of focal cardiac tamponade in cases of high suspicion with unrevealing/equivocal TTE	Recommended
TTE for surveillance of pericardial effusion (at least moderate in size)	Reasonable
Pericardiocentesis for cardiac tamponade	Recommended
Pericardiocentesis for pericardial effusion without tamponade	Not recommended
Pericardial window after prior pericardiocentesis for recurrent large pericardial effusion and cardiac tamponade	Reasonable

Adapted with permission from Klein et al.[1]

CCT = cardiac computed tomography; CMR = cardiac magnetic resonance; TTE = transthoracic echocardiography.

pressures in right- and left-side cardiac chambers. On echocardiography, this hemodynamic abnormality results in shift of the interventricular septum to the left with inspiration, an E-wave predominant mitral inflow pattern, an elevated medial e' tissue Doppler velocity, a plethoric inferior vena cava, and late-diastolic flow expiratory reversal in the hepatic veins (Tables 10 and 11, Figures 11 and 12).[43,44]

With CMR imaging, early inspiratory septal shift during a free-breathing cine white-blood acquisition is indicative of constrictive pathophysiology. Pericardial thickness is also readily assessed. Inflammation is characterized based on whether there is increased pericardial signal on T_2-short tau inversion recovery imaging indicative of edema and late gadolinium enhancement compatible with neovascularization and inflammation. CCT evaluates pericardial calcifications and defines thoracic anatomy before pericardiectomy, particularly the relationship between cardiovascular structures and the sternum (Tables 10 and 11).[1] If clinical and imaging data are incongruent, a detailed invasive hemodynamic evaluation should be performed with right and left heart catheterization, including an assessment for respiratory

FIGURE 10 Echocardiography Signs of Cardiac Tamponade

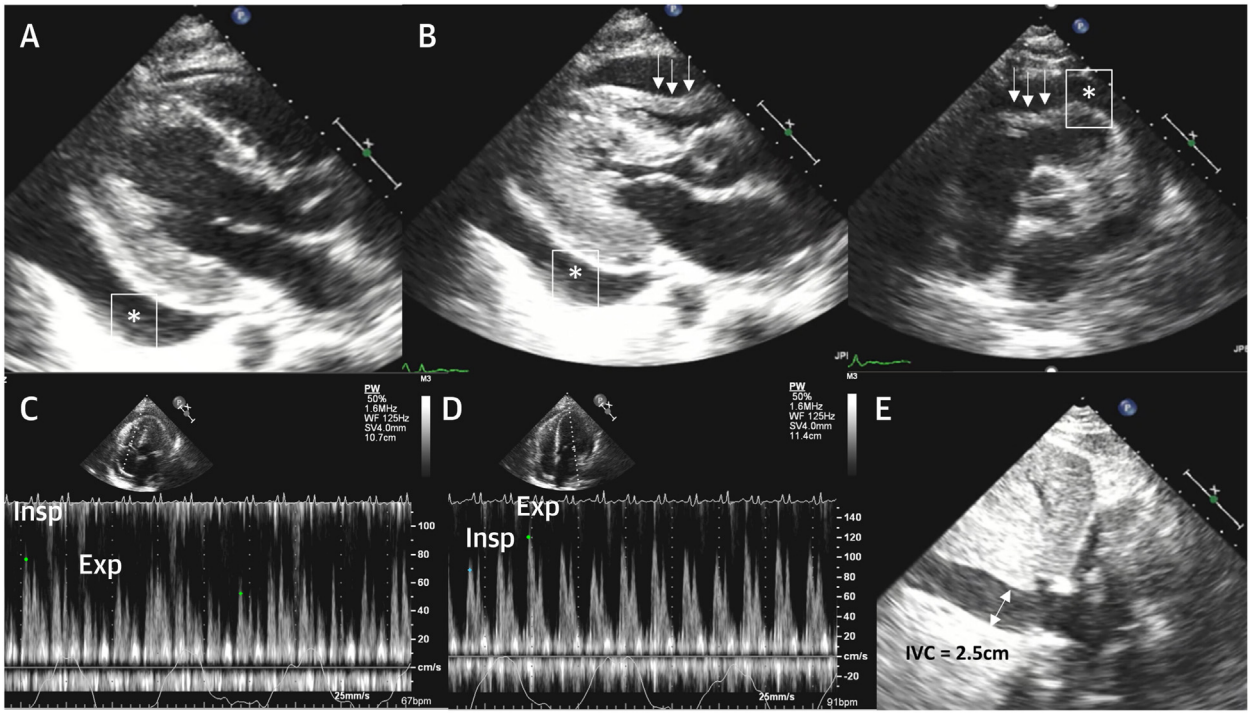

(A) TTE in parasternal long-axis view featuring moderate-to-large PEff (*). (B) Parasternal long-axis and short-axis views demonstrate end-diastolic right ventricular free wall collapse. Significant respirophasic tricuspid (C) and mitral (D) inflow velocity variation is noted, and there is a plethoric IVC (E). Adapted with permission from Klein et al.[1] Exp = expiration; Insp = inspiration; IVC = inferior vena cava; PEff = pericardial effusion; TTE = transthoracic echocardiography.

JACC VOL. 86, NO. 25, 2025
DECEMBER 23/30, 2025:2691-2719

TABLE 10 Multimodality Imaging Features of Constrictive Pericarditis

TTE	CCT	CMR
■ Respirophasic ventricular dependence/septal shift ■ E-wave predominant LV filling with respirophasic variation ■ Dilated inferior vena cava with <50% collapse ■ Hepatic vein end-diastolic expiratory reversal flow velocity/forward flow velocity ≥0.8 ■ Normal or increased medial mitral annular e' velocity (>8 cm/s) ■ Annulus reversus (medial > lateral e' mitral annular velocity) ■ Loss of superior vena cava systolic flow variation ■ Respirophasic variation across mitral and tricuspid valve E-wave inflow velocities (>25% and >40%, respectively)	■ Increased pericardial thickness ■ Pericardial calcification	■ Increased pericardial thickness ■ Respirophasic ventricular dependence on free breathing cine white-blood sequences ■ Wall tethering and conical deformity of the ventricle on cine-white blood and tagging sequences ■ Inflammation LGE and edema on T_2-STIR (in inflammatory TCP)

No single isolated imaging finding is diagnostic of CP; a constellation of findings in conjunction with clinical features of CP is required to make the diagnosis. Adapted with permission from Klein et al.[1]

CCT = cardiac computed tomography; CMR = cardiac magnetic resonance; CP = constrictive pericarditis; LGE = late gadolinium enhancement; LV = left ventricular; STIR = short tau inversion recovery; TCP = transient constrictive pericarditis; TTE = transthoracic echocardiography.

TABLE 11 Recommendations for Multimodality Cardiac Imaging Evaluation and Management for Constrictive Pericarditis

Recommendation	Class
Noninvasive hemodynamic assessment by TTE for the diagnosis of constrictive pericarditis and effusive constrictive pericarditis	Recommended
CMR to provide supportive evidence of constrictive pericarditis, especially when TTE inconclusive	Reasonable
CMR to identify pericardial inflammation as an etiology of for constrictive pericarditis	Recommended
CCT to identify pericardial calcifications as supplementary evidence for constriction, and for preoperative evaluation for pericardiectomy surgery	Reasonable
Invasive cardiac catheterization for the diagnosis of constrictive pericarditis, where noninvasive methods are nondiagnostic or equivocal	Recommended
First-line treatment of inflammatory constrictive pericarditis with anti-inflammatory therapy	Recommended
Diuretics for symptomatic treatment of constrictive pericarditis	Reasonable
Radical surgical pericardiectomy for noninflammatory constrictive pericarditis and inflammatory constrictive pericarditis failing anti-inflammatory therapy	Recommended
Partial anterior and/or diaphragmatic pericardiectomy for constrictive pericarditis	Not recommended

Adapted with permission from Klein et al.[1]

CMR = cardiac magnetic resonance; CCT = cardiac computed tomography; TTE = transthoracic echocardiography.

discordance in left and right ventricular systolic pressures using systolic area index (Figure 13).[45,46] Table 12 compares the characteristics of constrictive pericarditis with cardiac tamponade and restrictive cardiomyopathy.

For patients with underlying pericardial inflammation as in transient constriction, anti-inflammatory therapy should be initiated before considering pericardiectomy (Figure 14).[48] This approach may resolve the constrictive pathophysiology, or if pericardiectomy remains indicated, facilitates a more successful surgery on a less-inflamed pericardium.[38] In tuberculous constrictive pericarditis, antituberculous therapy may resolve constrictive pathophysiology, and corticosteroids may enhance clinical improvement.[49] In patients with chronic constrictive pericarditis and heart failure, diuretic therapy can treat volume overload but does not alter the natural history. Goal-directed heart failure therapy may be implemented, although evidence is limited. Surgical radical pericardiectomy is preferred, with resection of the entire pericardium—including anterior, diaphragmatic and posterior segments—on cardiopulmonary bypass, and should be performed at experienced tertiary surgical centers for optimal clinical outcomes.[38]

4.3.4. Pericarditis in Oncologic Patients

Pericardial involvement in the setting of known malignancy can occur with direct spread or hematologic or lymphatic dissemination.[50] Most pericardial metastases are identified as part of a staging chest computed tomography or positron emission tomography-computed tomography study. Frequently, the presence of new pericardial effusion or nodularity in staging imaging studies is the first clue for pericardial malignant involvement. The presence of hemorrhagic or complex pericardial effusion increases the likelihood of pericardial metastasis in that setting. Symptoms of pericardial metastasis, if present, are related to associated pericardial

FIGURE 11 Echocardiography Features of Constrictive Pericarditis

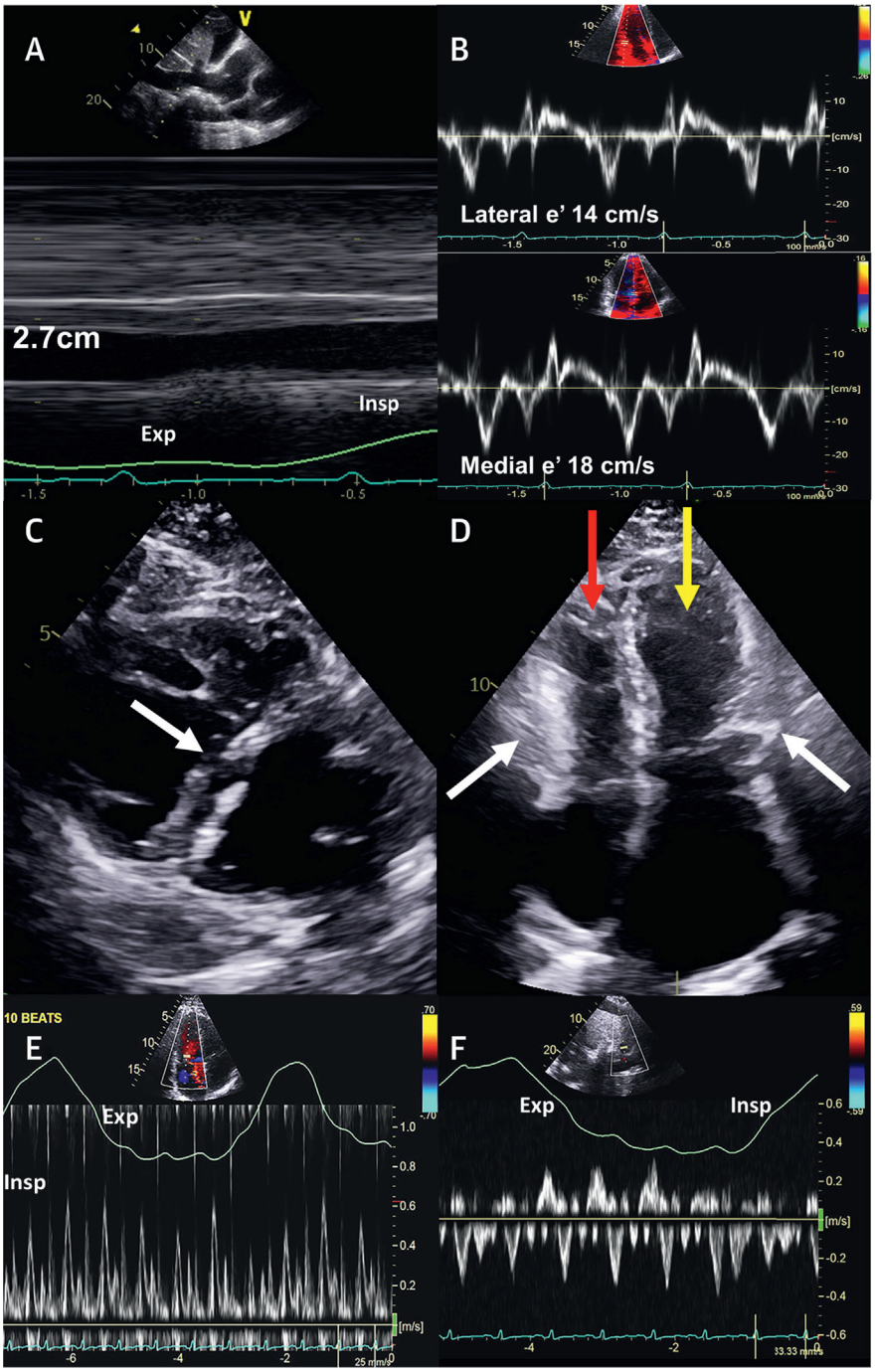

(A) M-mode subcostal view showing dilated IVC measuring 2.7 cm with <50% collapse. (B) Tissue Doppler of mitral annulus lateral e′ lower than medial e′, indicating annulus reversus. (C) Parasternal ventricular short-axis view with respiratory interventricular septal shift (arrow). (D) Apical 4-chamber view with pericardial calcifications and tethering at the lateral to mitral and tricuspid annulus (white arrows); and left ventricle cylindrical (yellow arrow) and right ventricle conical (red arrow) deformities. (E) Mitral valve inflow pulsed-wave Doppler indicating significant >25% respirophasic variation. (F) Hepatic vein pulsed-wave Doppler indicating expiratory end-diastolic reversal flow velocity/forward flow velocity ≥0.8. Adapted with permission from Klein et al.[1] Exp = expiration; Insp = inspiration IVC = inferior vena cava.

JACC VOL. 86, NO. 25, 2025
DECEMBER 23/30, 2025:2691-2719

FIGURE 12 Echocardiography Parameters and Diagnostic Algorithm and Validation for Constrictive Pericarditis

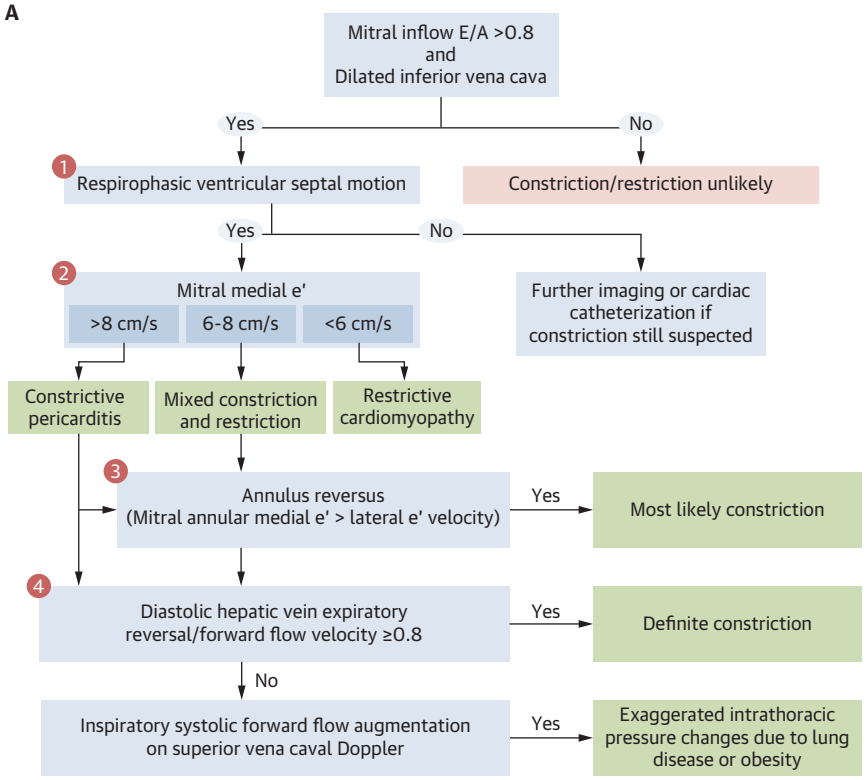

B

	Sensitivity	Specificity	PPV	NPV
1	94%	73%	93%	77%
2	81%	91%	97%	58%
3	71%	79%	93%	45%
4	73%	66%	86%	42%
1 and 2	80%	96%	99%	58%
1 with both 2 and 4	67%	99%	100%	50%

Adapted with permission from Klein et al.[1] NPV = negative predictive value; PPV = positive predictive value.

effusion or pericarditis. When pericardial involvement is suspected, the main role of imaging is to confirm the presence of metastases and to identify associated complications, including pericarditis, hemorrhage, CP, and hemodynamic consequence of pericardial tumor infiltration. Table 13 lists imaging findings of pericardial manifestations associated with malignancy by echocardiography, computed tomography, and CMR. Cardiac

FIGURE 13 Invasive Diagnosis of Constrictive Pathophysiology

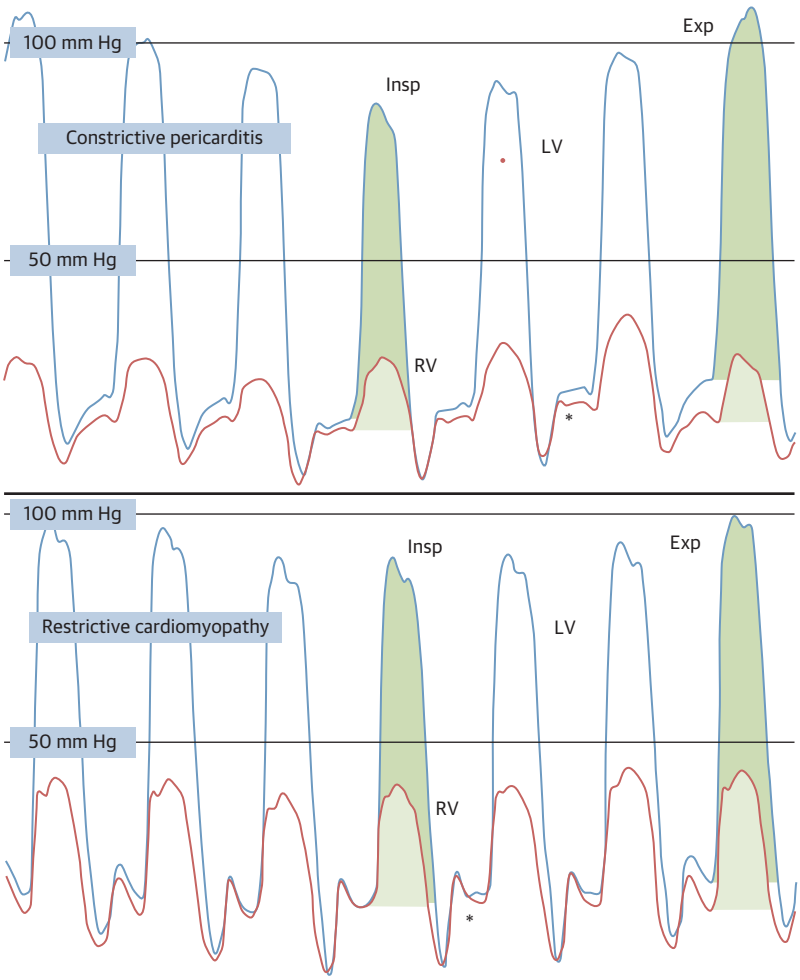

(Top) Left ventricular (LV) (blue) and right ventricular (RV) (orange) hemodynamic pressure tracings in constrictive pericarditis. End-diastolic filling pressures are elevated and a "square root" sign is present on both pressure tracings (*). Enhanced ventricular interdependence is present, demonstrated by visualization of the systolic area index; RV (gray) and LV (dark gray) areas under the curve are shown for both inspiration and expiration. During inspiration, there is an increase in the area of the RV pressure curve and decrease in the area of the LV pressure curve. (Bottom) LV and RV pressure tracings in restrictive cardiomyopathy. Although end-diastolic filling pressures are elevated and a square root sign (*) is present, there is no evidence of enhanced ventricular interdependence, with parallel changes in LV and RV pressure curve areas. Adapted with permission from Geske et al.[47] Exp = expiration; Insp = inspiration.; LV = left ventricle; RV = right ventricle.

imaging, especially CMR, also plays a critical role in differentiating pericardial masses, including cysts, diverticulum, and complex effusions; benign tumors such as lipomas, fibromas, hemangiomas, and teratomas; and malignant tumors, such as mesothelioma, sarcoma, lymphoma, or metastases.[1]

Pericarditis may be another first manifestation of malignancy involving the pericardium; however, pericarditis is more frequently related to the oncologic treatment in these patients.[50] Infectious pericarditis may be seen in immunosuppressed patients, and the etiology in this setting is different than in nononcologic patients.

TABLE 12 Clinical Features, Test Results, and Management of Cardiac Tamponade, Constrictive Pericarditis, and Restrictive Cardiomyopathy

Features	Cardiac Tamponade	Constrictive Pericarditis	Restrictive Cardiomyopathy
Physical examination	■ Tachycardia ■ Hypotension ■ Pulsus paradoxus ■ ↑ JVP with prominent x and absent y descent ■ Muffled heart sounds	■ ↑ JVP with prominent x and y descents ■ Kussmaul's sign ■ Pericardial knock ■ Ascites ■ Peripheral edema	■ ↑ JVP with prominent y and attenuated x descents ■ Kussmaul's sign ■ Third heart sound (S3) ■ Peripheral edema
ECG	■ Tachycardia ■ Low voltage amplitude ■ Electrical alternans	■ No pathognomonic features ■ Low voltage amplitude ■ Atrial fibrillation	■ No pathognomonic features ■ Atrial fibrillation
Chest x-ray	■ ↑ Cardiac silhouette	■ Pericardial calcification seen in one-third of patients	■ No pericardial calcification
Echocardiography	■ Pericardial effusion ■ Cardiac chamber compression or collapse ■ Respirophasic ventricular interdependence by 2D and M-mode ■ Respirophasic variation in mitral and tricuspid inflow Doppler ■ Dilated inferior vena cava ■ Expiratory hepatic venous diastolic flow reversals	■ Respirophasic ventricular interdependence by 2D and M-mode ■ Respirophasic variation in mitral and tricuspid inflow Doppler ■ ↑ Mitral annular e' velocities ■ Annulus reversus (medial > lateral mitral annular e' velocities) ■ Dilated inferior vena cava ■ Expiratory hepatic venous diastolic flow reversals	■ Atrial enlargement ■ ↓ mitral annular e' velocities ■ Diastolic dysfunction ■ Elevated right ventricular systolic pressure ■ Dilated inferior vena cava ■ Inspiratory hepatic venous diastolic flow reversals ■ Increased left ventricular wall thickness
Cardiac MRI	■ Should not typically be used for diagnosis of tamponade ■ Pericardial effusion ■ Cardiac chamber compression or collapse	■ ↑ Pericardial thickness ■ Respirophasic ventricular interdependence/septal shift on free breathing imaging sequences ■ Pericardial late gadolinium enhancement* ■ Pericardial edema* ■ Wall tethering, conical deformity of the ventricle	■ Abnormal myocardial late gadolinium enhancement ■ Other abnormal myocardial sequences including abnormal nulling or T2 time* ■ Normal pericardial thickness without pericardial late gadolinium enhancement ■ No ventricular interdependence on free-breathing sequences ■ Increased left ventricular wall thickness
Cardiac catheterization	■ ↑ RA pressure with prominent x and attenuated y descent ■ Equalization of right and left ventricular diastolic pressures ■ Respirophasic ventricular interdependence and pulsus paradoxus ■ Intrathoracic-intracardiac dissociation	■ ↑ RA pressure with rapid x and y descent and Kussmaul's sign ■ Equalization of right and left ventricular diastolic pressures with dip-and-plateau waveforms ■ Respirophasic ventricular interdependence and pulsus paradoxus ■ Intrathoracic-intracardiac dissociation ■ Distal coronary artery fixation on angiography	■ ↑ RA pressure with prominent y and attenuated x descents ■ Elevated right ventricular systolic pressure ■ No ventricular interdependence ■ No intrathoracic-intracardiac dissociation
Treatment	■ Pericardiocentesis ■ Pericardial window	■ Surgical radical pericardiectomy† ■ Diuretics	■ Goal directed medical therapy for heart failure and treat underlying etiology (eg, amyloidosis)

*While mild pericardial late gadolinium enhancement may be present in constrictive pericarditis due to pericardial fibrosis, the presence of significant pericardial late gadolinium enhancement and/or pericardial edema on T2 short tau inversion recovery imaging suggests the presence of transient constrictive pericarditis secondary to pericardial inflammation.
†In patients with pericardial inflammation by inflammatory markers or cardiac magnetic resonance imaging, consider a trial of anti-inflammatory therapy as first-line therapy and proceed to surgical pericardiectomy if this fails to resolve constrictive physiology.

JVP = jugular venous pressure; RA = right atrial.

Fungal and bacterial etiologies have a higher prevalence in this population compared with that of nononcologic patients. Inflammatory pericarditis and concomitant myocarditis are commonly associated with chemotherapy and immunotherapy and may be subclinical or cause significant symptoms. In patients undergoing radiation treatment, pericarditis and CP are notable complications when radiation field includes or is near the pericardium.

Pericarditis treatment in oncologic patients is tailored to the underlying etiology and is aimed at providing symptomatic relief and achieving hemodynamic stability. Although treatment of pericarditis is this setting should

FIGURE 14 Treatment Approach for Constrictive Pericarditis

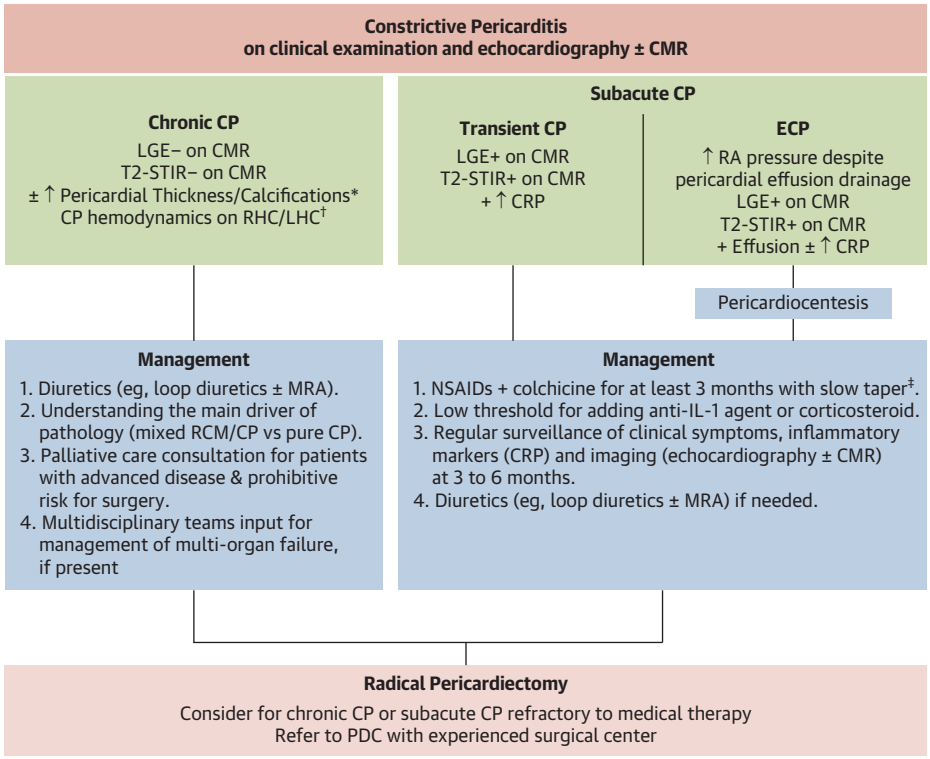

Differentiating chronic vs subacute CP using CMR imaging guides therapy and can negate the need for pericardiectomy. Aggressive anti-inflammatory therapy for subacute CP is the cornerstone of management; however, pericardiectomy remains the main therapy for chronic CP patients who are surgical candidates. *Pericardial thickness can be normal in 18% of CP cases. †CMR and echocardiography made the diagnosis of CP more reliable without need for diagnostic cardiac catheterization in most cases. ‡Tapering should only start if patient symptoms resolve, and C-reactive protein (CRP) normalizes. Adapted with permission from Al-Kazaz et al.[38] CMR = cardiac magnetic resonance; CP = constrictive pericarditis; CRP = C-reactive protein; ECP = effusive constrictive pericarditis; IL-1 = interleukin-1; LGE = late gadolinium enhancement; LHC = left heart catheterization; MRA = mineralocorticosteroid receptor antagonist; NSAID = nonsteroidal anti-inflammatory drug; PDC = pericardial disease center; RA = right atrial; RCM = restrictive cardiomyopathy; RHC = right heart catheterization; T_2-STIR = T_2-weighted short tau inversion recovery.

follow general recommendations, it should be adapted to the goals of care of each patient. Improvement of the underlying disease is generally associated with improvement of the pericardial inflammation. When pericarditis is related to the oncologic treatment, discontinuation or alternative drug regimen may be necessary to alleviate symptoms. Treatment of large pericardial effusions to alleviate symptoms with pericardiocentesis, and sometimes with pericardial window given recurrences, are options in advanced stages of disease.[51]

5. CONCLUSIONS

Pericarditis remains a challenging and heterogenous condition not infrequently encountered in clinical practice. A novel diagnostic criteria for pericarditis has been devised, consisting of pericarditic chest pain with 5 additional criteria (0 = unlikely pericarditis, 1 = possible pericarditis, 2+ = definite diagnosis). These criteria include clinical findings of pericardial rub, ECG changes, new or worsening pericardial effusions, serologic findings of elevated inflammatory markers, and imaging findings of pericardial inflammation on CMR or CT.

Multimodality cardiac imaging—including echocardiography, CCT, and CMR—play a critical and complimentary role in the diagnosis, risk stratification, treatment guidance, and surveillance of pericarditis. Recent advances in targeted biologic therapies have led to a paradigm shift, positioning these agents as second-line

TABLE 13 Pericarditis in Oncologic Patients

TTE	CCT	CMR
May identify nodular pericardial thickening or pericardial masses when malignant involvement If large mass, used to characterize hemodynamic impairment	Nodular pericardial thickening and enhancement on contrast-enhanced CCT is highly indicative of pericardial metastasis If large mass, used to characterize the size and relationship with adjacent structures Whole-body staging scan to evaluate for lymph node involvement and distant metastasis Best modality for evaluating calcified structures	Pericardial nodular thickening with intermediate to high SI on T_1W BB with contrast enhancement after gadolinium If large mass, used to characterize the size, tissue characteristics, and relationship with adjacent structures Best method to identify cardiac involvement characterized by abnormal SI of the myocardium adjacent to pericardial lesion, and lack of normal sliding on cine white-blood images
Segmental wall motion abnormalities or pathological myocardial strain values (in case of associated myocarditis)	Enhancement of the thickened visceral and parietal surfaces of the pericardium, best seen on delayed CCT images	Pericardial inflammation diagnosed by enhancement of pericardium on LGE sequence (inflammation) or T_2-STIR sequence (edema)
PEff presence and volume Abnormal echogenicity suggestive of exudative or hemorrhagic effusion Best method to identify signs of tamponade Evaluate features of CP physiology	PEff presence and volume CT attenuation values of PEff on noncontrast CT may help distinguish between exudative, hemorrhagic, and transudative fluid May be useful to guide intervention or surgery when indicated	PEff presence and volume High SI on T_1-weighted BB images and intermediate intensity on cine white-blood is suggestive of exudative PEffs Hemorrhagic effusion can be characterized and imaging appearance depends on acuity of bleeding: ■ Acute: high SI in T_1W or T_2W BB ■ Subacute: intermediate SI in T_1W or T_2W BB ■ Evaluate features of CP physiology

BB = black-blood; CMR = cardiac magnetic resonance; CCT = cardiac computed tomography; CP = constrictive pericarditis; CT = computed tomography; LGE = late gadolinium enhancement; PEff = pericardial effusion; SI = signal intensity; T_1W = T_1-weighted; T_2-STIR = T_2-short tau inversion recovery; T2W = T2-weighted; TTE = transthoracic echocardiography.

treatments after traditional first-line anti-inflammatory therapies, as reflected in new treatment algorithms. PDC are excellent multi-disciplinary destinations for referrals, management of complex cases, education, and research.

This CCG aims to guide clinicians to optimize evaluation and management of patients with pericarditis, with the goal of improving clinical outcomes.

PRESIDENT AND STAFF

American College of Cardiology

Christopher M. Kramer, MD, FACC

Cathleen C. Gates, Chief Executive Officer

Richard J. Kovacs, MD, MACC, Chief Medical Officer

Brendan Mullen, Senior Executive Vice President

Joseph M. Allen, MA, Team Leader, Science & Quality

Amy Dearborn, Team Leader, Decision Science

Ashleigh M. Covington, MA, Team Leader, Decision Science Delivery

Alan Shinkar, MPH, Project Manager, Decision Science Delivery

Grace D. Ronan, Senior Production and Operations Manager, Clinical Policy Publications

REFERENCES

1. Klein AL, Wang TKM, Cremer PC, et al. Pericardial diseases: international position statement on new concepts and advances in multimodality cardiac imaging. *JACC Cardiovasc Imaging*. 2024;17:937–988.

2. Rodriguez ER, Tan CD. Structure and anatomy of the human pericardium. *Prog Cardiovasc Dis*. 2017;59:327–340.

3. Klein AL, Abbara S, Agler DA, et al. American Society of Echocardiography clinical recommendations for multimodality cardiovascular imaging of patients with pericardial disease: endorsed by the Society for Cardiovascular Magnetic Resonance and Society of Cardiovascular Computed Tomography. *J Am Soc Echocardiogr*. 2013;26:965–1012.

4. Hoit BD. Pathophysiology of the pericardium. *Prog Cardiovasc Dis*. 2017;59:341–348.

5. Imazio M, Gaita F. Diagnosis and treatment of pericarditis. *Heart*. 2015;101:1159–1168.

6. LeWinter MM. Clinical practice. Acute pericarditis. *N Engl J Med*. 2014;371:2410–2416.

7. Adler Y, Charron P, Imazio M, et al. 2015 ESC guidelines for the diagnosis and management of pericardial diseases: the Task Force for the Diagnosis and Management of Pericardial Diseases of the European Society of Cardiology (ESC) endorsed by: the European Association for Cardio-Thoracic Surgery (EACTS). *Eur Heart J*. 2015;36:2921–2964.

8. Chiabrando JG, Bonaventura A, Vecchie A, et al. Management of acute and recurrent pericarditis: JACC state-of-the-art review. *J Am Coll Cardiol*. 2020;75:76–92.

9. Vecchie A, Del Buono MG, Chiabrando GJ, et al. Interleukin-1 and the NLRP3 inflammasome in pericardial disease. *Curr Cardiol Rep*. 2021;23:157.

10. Mauro AG, Bonaventura A, Vecchie A, et al. The role of NLRP3 inflammasome in pericarditis: potential for therapeutic approaches. *JACC Basic Transl Sci*. 2021;6:137–150.

11. Brucato A, Imazio M, Cremer PC, et al. Recurrent pericarditis: still idiopathic? The pros and cons of a well-honoured term. *Intern Emerg Med*. 2018;13:839–844.

12. Weber BN, Paik JJ, Aghayev A, et al. Novel imaging approaches to cardiac manifestations of systemic inflammatory diseases: JACC scientific statement. *J Am Coll Cardiol*. 2023;82:2128–2151.

13. Aldajani A, Berube M, Mardigyan V. How and why to set up a pericardial disease clinic. *Can J Cardiol*. 2023;39:1149–1151.

14. Heine M, Agrawal A, Wensink E, et al. The role of the advanced practice provider in a pericardial center of excellence. *Curr Cardiol Rep*. 2025;27:69.

15. Cremer PC, Kumar A, Kontzias A, et al. Complicated pericarditis: understanding risk factors and pathophysiology to inform imaging and treatment. *J Am Coll Cardiol*. 2016;68:2311–2328.

16. Pisacreta AM, Mascolo R, Nivuori M, et al. Acute pericarditis with pleuropulmonary involvement, fever and elevated C-reactive protein: a systemic autoinflammatory disease? A cohort study. *Eur J Intern Med*. 2023;113:45–48.

17. Tombetti E, Casarin F, Bizzi E, et al. Relapsing pericarditis: peripheral blood neutrophilia, lymphopenia and high neutrophil-to-lymphocyte ratio herald acute attacks, high-grade inflammation, multiserosal involvement, and predict multiple recurrences. *Int J Rheum Dis*. 2023;26:337–343.

18. Imazio M, Brucato A, Maestroni S, et al. Prevalence of C-reactive protein elevation and time course of normalization in acute pericarditis: implications for the diagnosis, therapy, and prognosis of pericarditis. *Circulation*. 2011;123:1092–1097.

19. Wang TKM, Ayoub C, Chetrit M, et al. Cardiac magnetic resonance imaging techniques and applications for pericardial diseases. *Circ Cardiovasc Imaging*. 2022;15:e014283.

20. Chetrit M, Xu B, Kwon DH, et al. Imaging-guided therapies for pericardial diseases. *JACC Cardiovasc Imaging*. 2020;13:1422–1437.

21. Kim MS, Kim EK, Choi JY, et al. Clinical utility of [(18)F]FDG-PET/CT in pericardial disease. *Curr Cardiol Rep*. 2019;21:107.

22. Imazio M. Medical therapy of pericarditis: tips and tricks for clinical practice. *J Cardiovasc Med (Hagerstown)*. 2024;25:420–425.

23. Sivalokanathan S, Chokshi N. American College of Cardiology. Pericarditis in athletes: approach to exercise restriction. Accessed April 2025. https://www.acc.org/Latest-in-Cardiology/Articles/2022/09/06/11/53/Pericarditis-in-Athletes

24. Brucato A, Imazio M, Gattorno M, et al. Effect of anakinra on recurrent pericarditis among patients with colchicine resistance and corticosteroid dependence: the AIRTRIP randomized clinical trial. *JAMA*. 2016;316:1906–1912.

25. Klein AL, Imazio M, Cremer P, et al. Phase 3 trial of interleukin-1 trap rilonacept in recurrent pericarditis. *N Engl J Med*. 2021;384:31–41.

26. Myachikova VY, Maslyanskiy AL, Moiseeva OM, et al. Treatment of idiopathic recurrent pericarditis with goflikicept: phase II/III study results. *J Am Coll Cardiol*. 2023;82:30–40.

27. Collini V, Andreis A, De Biasio M, et al. Efficacy of colchicine in addition to anakinra in patients with recurrent pericarditis. *Open Heart*. 2024;11:e002599.

28. Imazio M, Agrimi C, Cescon L, et al. Colchicine for the treatment of the spectrum of cardiovascular diseases: current evidence and ongoing perspectives. *J Cardiovasc Med (Hagerstown)*. 2024;25:653–663.

29. Imazio M, Klein AL, Brucato A, et al. Sustained pericarditis recurrence risk reduction with long-term rilonacept. *J Am Heart Assoc*. 2024;13:e032516.

30. Kumar S, Khubber S, Reyaldeen R, et al. Advances in imaging and targeted therapies for recurrent pericarditis: a review. *JAMA Cardiol*. 2022;7:975–985.

31. Yesilyaprak A, Kumar AK, Agrawal A, et al. Predicting long-term clinical outcomes of patients with recurrent pericarditis. *J Am Coll Cardiol*. 2024;84:1193–1204.

32. Vakamudi S, Ho N, Cremer PC. Pericardial effusions: causes, diagnosis, and management. *Prog Cardiovasc Dis*. 2017;59:380–388.

33. Gornik HL, Gerhard-Herman M, Beckman JA. Abnormal cytology predicts poor prognosis in cancer patients with pericardial effusion. *J Clin Oncol*. 2005;23:5211–5216.

34. Imazio M, Demichelis B, Parrini I, et al. Relation of acute pericardial disease to malignancy. *Am J Cardiol*. 2005;95:1393–1394.

35. Cremer PC, Kwon DH. Multimodality imaging of pericardial disease. *Curr Cardiol Rep*. 2015;17:24.

36. Ditchey R, Engler R, LeWinter M, et al. The role of the right heart in acute cardiac tamponade in dogs. *Circ Res*. 1981;48:701–710.

37. Miranda WR, Oh JK. Constrictive pericarditis: a practical clinical approach. *Prog Cardiovasc Dis*. 2017;59:369–379.

38. Al-Kazaz M, Klein AL, Oh JK, et al. Pericardial diseases and best practices for pericardiectomy: JACC state-of-the-art review. *J Am Coll Cardiol*. 2024;84:561–580.

39. Mayosi BM, Burgess LJ, Doubell AF. Tuberculous pericarditis. *Circulation*. 2005;112:3608–3616.

40. Sagrista-Sauleda J, Angel J, Sanchez A, et al. Effusive-constrictive pericarditis. *N Engl J Med*. 2004;350:469–475.

41. Kim KH, Miranda WR, Sinak LJ, et al. Effusive-constrictive pericarditis after pericardiocentesis: incidence, associated findings, and natural history. *JACC Cardiovasc Imaging*. 2018;11:534–541.

42. Klein AL, Cremer PC. Ephemeral effusive constrictive pathophysiology. *JACC Cardiovasc Imaging*. 2018;11:542–545.

43. Qamruddin S, Alkharabsheh SK, Sato K, et al. Differentiating constriction from restriction (from the Mayo Clinic echocardiographic criteria). *Am J Cardiol*. 2019;124:932–938.

44. Welch TD, Ling LH, Espinosa RE, et al. Echocardiographic diagnosis of constrictive pericarditis: Mayo Clinic criteria. *Circ Cardiovasc Imaging*. 2014;7:526–534.

45. Talreja DR, Nishimura RA, Oh JK, et al. Constrictive pericarditis in the modern era: novel criteria for diagnosis in the cardiac catheterization laboratory. *J Am Coll Cardiol*. 2008;51:315–319.

46. Yang JH, Miranda WR, Borlaug BA, et al. Right atrial/pulmonary arterial wedge pressure ratio in primary and mixed constrictive pericarditis. *J Am Coll Cardiol*. 2019;73:3312–3321.

47. Geske JB, Anavekar NS, Nishimura RA, et al. Differentiation of constriction and restriction: complex cardiovascular hemodynamics. *J Am Coll Cardiol*. 2016;68:2329–2347.

48. Cremer PC, Tariq MU, Karwa A, et al. Quantitative assessment of pericardial delayed hyperenhancement predicts clinical improvement in patients with constrictive pericarditis treated with anti-inflammatory therapy. *Circ Cardiovasc Imaging*. 2015;8:e003125.

49. Mayosi BM, Ntsekhe M, Bosch J, et al. Prednisolone and mycobacterium indicus pranii in tuberculous pericarditis. *N Engl J Med*. 2014;371:1121–1130.

50. Chahine J, Shekhar S, Mahalwar G, et al. Pericardial involvement in cancer. *Am J Cardiol*. 2021;145:151–159.

51. Lorenzo-Esteller L, Ramos-Polo R, Pons Riverola A, et al. Pericardial disease in patients with cancer: clinical insights on diagnosis and treatment. *Cancers (Basel)*. 2024;16:3466.

KEY WORDS **ACC Concise Clinical Guidance, anti-inflammatory agents, computed tomography, constrictive pericarditis, echocardiography, magnetic resonance imaging, pericardial effusion, pericarditis, pericardium**

JACC VOL. 86, NO. 25, 2025
DECEMBER 23/30, 2025:2691–2719

APPENDIX 1. AUTHOR RELATIONSHIPS WITH INDUSTRY AND OTHER ENTITIES (RELEVANT)—2025 CONCISE CLINICAL GUIDANCE: AN ACC EXPERT CONSENSUS STATEMENT ON THE DIAGNOSIS AND MANAGEMENT OF PERICARDITIS

Committee Member	Employment	Consultant	Speakers Bureau	Ownership/ Partnership/ Principal	Personal Research	Institutional, Organizational, or Other Financial Benefit	Expert Witness
Tom Kai Ming Wang (*Chair*)	Cleveland Clinic Center for the Diagnosis and Treatment of Pericardial Diseases, Section of Cardiovascular Imaging, Department of Cardiovascular Medicine, Heart, Vascular and Thoracic Institute-Assistant Professor of Medicine	None	None	None	None	None	None
Allan L. Klein (*Vice Chair*)	Cleveland Clinic Center for the Diagnosis and Treatment of Pericardial Diseases, Section of Cardiovascular Imaging, Department of Cardiovascular Medicine, Heart, Vascular and Thoracic Institute—Director of Pericardial Center & Professor of Medicine	■ Cardiol Therapeutics ■ Kiniksa* ■ Pfizer ■ Ventyx†	None	None	■ Kiniksa† ■ Ventyx†	■ Pericarditis Alliance†	None
Paul C. Cremer	Northwestern University Feinberg School of Medicine, Department of Medicine, Division of Cardiology, Bluhm Cardiovascular Institute—Associate Professor of Medicine	■ Cardiol Therapeutics ■ Kiniksa ■ Monte Rosa Therapeutics ■ Pfizer ■ Ventyx	None	None	None	None	None
Massimo Imazio	University of Udine, Cardiothoracic Department, University Hospital Santa Maria della Misericordia, ASUFC, and Department of Medicine-Chief of Cardiology and Professor of Medicine	None	None	None	None	■ Monte Rosa Therapeutics	None
Sarah Kohnstamm	University of Michigan, Division of Cardiovascular Diseases, Department of Internal Medicine—Clinical Assistant Professor of Medicine	None	None	None	None	None	None
Sushil Allen Luis	Mayo Clinic, Division of Structural Heart Disease, Department of Cardiovascular Medicine, Associate Professor of Medicine	■ Cardiol Therapeutics* ■ Kiniksa ■ Medtronic* ■ SOBI*	None	None	■ Ventyx†	■ Pericarditis Alliance†	None
Vartan Mardigyan	McGill University Health Centre, Assistant Professor of Medicine	None	None	None	None	None	None
Monica Mukherjee	Johns Hopkins University School of Medicine—Associate Professor of Medicine	None	None	None	None	None	None
Karen Ordovas	University of Washington—Professor of Radiology	None	None	None	None	None	None
Sneha Vakamudi	University of Texas at Austin Dell Medical School—Ascension Texas Cardiovascular—Assistant Professor of Medicine	■ Abbott ■ Bristol Myers Squibb	None	None	None	None	None
George F. Wohlford	UVA Health, Department of Pharmacy Services—Cardiovascular Pharmacist	None	None	None	None	None	None

This table represents the relationships of committee members with industry and other entities that were determined to be relevant to this document. These relationships were reviewed and updated in conjunction with all meetings and/or conference calls of the writing committee during the document development process. The table does not necessarily reflect relationships with industry at the time of publication. A person is deemed to have a significant interest in a business if the interest represents ownership of ≥5% of the voting stock or share of the business entity or ownership of ≥$5,000 of the fair market value of the business entity; or if funds received by the person from the business entity exceed 5% of the person's gross income for the previous year. Relationships that exist with no financial benefit are also included for the purpose of transparency. Relationships in this table are modest unless otherwise noted. According to the ACC, a person has a relevant relationship IF: a) the relationship or interest relates to the same or similar subject matter, intellectual property or asset, topic, or issue addressed in the document; b) the company/entity (with whom the relationship exists) makes a drug, drug class, or device addressed in the document or makes a competing drug or device addressed in the document; or c) the person or a member of the person's household, has a reasonable potential for financial, professional, or other personal gain or loss as a result of the issues/content addressed in the document.

*Significant relationship.

†No financial benefit.

ACC =American College of Cardiology; ASUFC = Azienda Sanitaria Universitaria Friuli Centrale; SOBI = Swedish Orphan Biovitrum AB; UVA, University of Virginia.

APPENDIX 2. PEER REVIEWER RELATIONSHIPS WITH INDUSTRY AND OTHER ENTITIES (COMPREHENSIVE)—2025 CONCISE CLINICAL GUIDANCE: AN ACC EXPERT CONSENSUS STATEMENT ON THE DIAGNOSIS AND MANAGEMENT OF PERICARDITIS

Reviewer	Representation	Employment	Consultant	Speakers Bureau	Ownership/ Partnership/ Principal	Personal Research	Institutional, Organizational, or Other Financial Benefit	Expert Witness
Antonio Abbate	Content Reviewer-ACC Expert	University of Viriginia—Professor of Medicine	■ Cardiol ■ Kiniksa* ■ Monte Rosa Therapeutics ■ Novo Nordisk	None	None	■ NIH*	None	None
Syed W. Haider	Content Reviewer-ACC Expert	Medstar Health—Attending Cardiologist	None	None	None	None	None	None
David Lin	Content Reviewer-ACC Expert	Allina Health—Cardiologist	None	None	None	None	■ Kiniksa	None
Gurusher S. Panjrath	Official Reviewer-ACC Solution Set Oversight Committee	George Washington University Medical—Director, Heart Failure and Mechanical Support Program	■ BridgeBio* ■ CVRx*	■ Alnylam ■ Pfizer*	None	None	■ CARDIO-TTRansform†	None
Brittany Weber	Content Reviewer-ACC Expert	Brigham and Women's Hospital—Director, Cardio-Rheumatology Clinic, Associate Physician in Prevention Cardiology	■ Kiniksa* ■ Novo Nordisk* ■ Oruka	None	None	■ AHA* ■ ASNC* ■ NIH*	None	None

This table includes all relationships with industry and other entities that were reported by reviewers at the time this document was under review, including those not considered relevant to the document. The table does not necessarily reflect relationships with industry at the time of publication. A person is deemed to have a significant interest in a business if the interest represents ownership of ≥5% of the voting stock or share of the business entity, or ownership of ≥$5,000 of the fair market value of the business entity; or if funds received by the person from the business entity exceed 5% of the person's gross income for the previous year. Relationships that exist with no financial benefit are also included for the purpose of transparency. Relationships in this table are modest unless otherwise noted. Please refer to https://www.acc.org/Guidelines/About-Guidelines-and-Clinical-Documents/Relationships-with-Industry-Policy for definitions of disclosure categories or additional information about the ACC Disclosure Policy for Writing Committees.

*Significant relationship.

†Relationship with this company is limited to enrolling patients in clinical trials. This disclosure was entered under the Clinical Trial Enroller category in the ACC's disclosure system. To appear in this category, the author acknowledges that there is no direct or institutional relationship with the trial sponsor as defined in the ACC Disclosure Policy for Writing Committees.

ACC = American College of Cardiology; AHA = American Heart Association; ASNC = American Society of Nuclear Cardiology; NIH = National Institutes of Health.